

Recurrent BCG Infection in a Boy With X-Linked Chronic Granulomatous Disease

Pasic S

Pediatric Immunology, Mother and Child Health Institute, Medical Faculty, University of Belgrade, Serbia

Key words: BCG infection. BCG lymphadenitis. Chronic granulomatous disease.

Palabras clave: Infección BCG. Linfadenitis por BCG. Enfermedad granulomatosa crónica.

Chronic granulomatous disease is a rare inherited disorder of phagocyte function caused by mutations in the genes coding for components in the multienzyme complex, phagocytic nicotinamide dinucleotide phosphate oxidase [1].

We report on a 12-year-old boy with X-linked chronic granulomatous disease (CGD) who developed local reactivation of bacillus Calmette-Guérin (BCG) lymphadenitis. The diagnosis of CGD had been established at 12 months of age after an episode of sepsis caused by *Salmonella enteritidis*. On examination, lymph node enlargement (2 cm) was noticed in the left axilla. The family history was suggestive for X-linked CGD as the patient's older half-brother had had short-bone osteomyelitis and died of sepsis in infancy. Phorbol-acetate-myristate stimulated nitroblue tetrazolium (PMA-NBT) testing revealed that 0% of the patient's neutrophils reduced the dye, while the mother's neutrophils reduced the dye partially (55%), thus confirming a carrier state for X-linked CGD. The

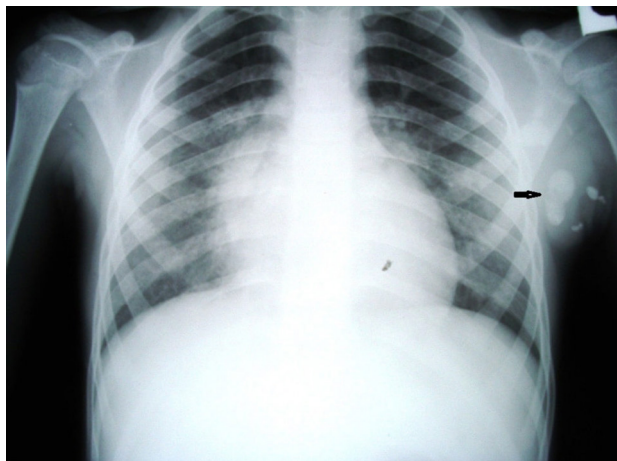


Figure. Axillary Bacille Calmette-Guérin lymphadenitis (arrow) with calcifications in a patient with chronic granulomatous disease.

definitive diagnosis was established by mutation analysis of the *CYBB* gene, which revealed a 5-base-pair deletion in exon 3 of the gene (159_164del) in both the patient and his mother.

The boy was given regular prophylaxis with cotrimoxazole and itraconazole and remained free of serious infections during his early childhood. At the age of 7 years he presented with reactivation of BCG lymphadenitis, 7 cm in size (Figure), without fever or evidence of dissemination of the BCG strain. Ethambutol and clarithromycin were given and, 6 months later, the lymph nodes decreased to 3 cm. The patient remained well until 12 years of age, when he developed severe lung infection due to the fungus *Scedosporium apiospermum*. He received stem cell transplantation from a matched unrelated donor, which was uneventful apart from acute grade I intestinal graft-vs-host disease.

Recently, Kusuhara et al [2] described a patient with X-linked CGD who presented with BCG lymphadenitis in infancy and developed disseminated infection 25 years after immunization [2]. Definite diagnosis of disseminated BCG infection requires microbiological identification of the BCG strain and isolation from at least 2 different anatomic sites beyond the site of immunization [3]. Bustamante et al [4], in turn, reviewed the cases of 16 patients with CGD in the literature who developed disseminated BCG disease; the disease proved fatal in 6 of the patients despite intensive antibiotic treatment. It should be noted that in several previously published cases of CGD, disseminated BCG infection was presumed but not proven to be present [5,6].

Local/persistent BCG lymphadenitis is the most common type of infection in CGD [1]. In a large cohort of 429 European patients with CGD, 34 patients (8%) developed either BCG skin infection at the inoculation site or regional lymphadenitis, but no cases of disseminated infection were reported [1]. Also, in a series of patients followed by our group since 1976, no cases of disseminated BCG infection were observed, even though half of the patients had local/persistent BCG lymphadenitis [7].

In a group of 23 patients with CGD at our center, we observed recurrence of axillary BCG lymphadenitis in another, 5-year-old, patient (unpublished data). Bustamante et al [4] also described a case of recurrent BCG infection, and concluded that patients with unusually severe or recurrent mycobacterial disease, including tuberculosis, should be investigated for CGD. However, more accurate diagnostic tools, including specific PCR-based assays, are needed to estimate the real incidence of disseminated BCG infection in CGD.

Reactivation of BCG lymphadenitis following stem cell transplantation is a well-known complication in vaccinated children and represents an inflammatory reaction due to immune reconstitution. We have reported the case of a patient with CGD who experienced reactivation of BCG lymphadenitis while in good health.

Funding

The writing of this manuscript was supported by grants (No.175065 and No.175073) awarded to SP by the Ministry of Science, Education and Technology, Republic of Serbia.

Conflicts of Interest

The author declares that he has no conflicts of interest.

References

1. van den Berg JM, van Koppen E, Ahlin A, Belohradsky BH, Bernatowska E, Corbeel L, Espanol T, Fischer A, Kurenko-Deptuch M, Mouy R, Petropoulou T, Roesler J, Seger R, Stasia M-J, Valerius NH, Weening RS, Wolach B, Roos D, Kuijpers TW. Chronic granulomatous disease: the European experience. *PLoS ONE*. 2009;4(4): e5234.
2. Kusuha K, Ohga S, Hashina T, Saito M, Sasaki Y, Ishimura M. Disseminated Bacillus-Calmette-Guérin lymphadenitis in a patient with gp91-phox-chronic granulomatous disease 25 years after vaccination. *Eur J Pediatr*. 2009;168:745-7/
3. Talbot EA, Perkins MD, Silva SFM, Frothingham R. Disseminated Bacille Calmette-Guérin disease after vaccination: case report and review. *Clin Infect Dis*. 1997;24:1139-46.
4. Bustamante J, Aksu G, Vogt G, Beaucondrey L, Genel F, Chapgier A, Filipe-Santos O, Feinberg J, Emile JF, Kutukceler N, Casanova JL. BCG-osis and tuberculosis in a child with chronic granulomatous disease. *J Allerg Clin Immunol*. 2007; 20:32-8.
5. Veronen P. Case report: presumed disseminated BCG infection in a boy with chronic granulomatous disease. *Acta Paediatr Scand*. 1974;63:627-30.
6. Kobayashi Y, Komazawa Y, Kobayashi M, Matsumoto T, Sakura N, Ishikawa K, Usui T. Presumed BCG infection in a boy with chronic granulomatous disease: a report of a case and a review of the literature. *Clin Pediatr (Phila)*. 1984;23:586-9.
7. Pasic S, Minic A, Minic P, Veljkovic D, Lilic D, Slavkovic B, Abinun M. Chronic granulomatous disease in Yugoslavia: Is there a role for early bone marrow transplantation? *J Clin Immunol*. 2003;23:55-61.

■ Manuscript received October 26, 2014; accepted for publication, February 16, 2015.

Srdjan Pasic

Mother & Child Health Institute
8 R. Dakica Street
11070 Belgrade
Serbia
E-mail: pasics@ikomline.net

Fatal Anaphylaxis Associated With the Gadolinium-Based Contrast Agent Gadoteridol (ProHance)

Takahashi S¹, Takada A¹, Saito K^{1,2}, Hara M¹, Yoneyama K¹, Nakanishi H²

¹Department of Forensic Medicine, Faculty of Medicine, Saitama Medical University, Iruma-gun, Saitama, Japan

²Department of Forensic Medicine, Faculty of Medicine, Juntendo University, Bunkyo-ku, Tokyo, Japan

Key words: Anaphylaxis. Gadoteridol. Gadolinium-based contrast agents. Forensic autopsy. Tryptase.

Palabras clave: Anafilaxia. Gadoteridol. Medios de contraste basados en gadolinio. Autopsia forense. Triptasa.

Gadolinium-based contrast agents (GBCAs) are considered to be extremely safe. The overall rates of GBCA adverse events and deaths are 59.8 and 0.9 per million administrations, respectively [1]. However, immediate allergic-type adverse effects linked to GBCAs remain a drug safety issue because of their potential risk of sudden death. Here, we provide the first autopsied case report of fatal anaphylaxis associated with gadoteridol, a GBCA sold as ProHance.

A Japanese man in his late 60s visited a general hospital for contrast-enhanced magnetic resonance imaging (MRI) of the prostate because his serum prostate-specific antigen level was slightly elevated (5.624 ng/mL) during a cancer screening test. He was not using any medications and had no history of exposure to contrast media or of drug hypersensitivity or allergic diseases, including asthma. At the general hospital, he was administered an intravenous injection of 2 mL of gadoteridol (a macrocyclic nonionic GBCA sold as ProHance [Eisai, Tokyo]) for allergy testing, and there were no signs or symptoms.

However, just after the intravenous injection of another 13 mL of gadoteridol for MRI imaging, the patient suddenly developed a dry cough, diaphoresis, and face flushing. The administration of gadoteridol was immediately interrupted, but he showed a decreased level of consciousness and then convulsed at 5 minutes after the injection; gasping respiration was seen 5 minutes later. He developed ventricular fibrillation and fell into cardiopulmonary arrest 20 minutes after the onset of symptoms. Cardiopulmonary resuscitation including repetitive defibrillation, intubation, and fluid replacement, together with the administration of epinephrine, dopamine, lidocaine, sodium bicarbonate, and methylprednisolone sodium succinate, was attempted, but it was not effective. The patient was pronounced dead approximately 3 hours after the onset of symptoms. His laboratory data at the hospital were nonspecific (allergy-associated items were not included).

A forensic autopsy was performed because medical malpractice was suspected. It revealed typical findings of anaphylaxis: widespread skin rash and severe laryngeal edema. The concentration of postmortem serum tryptase was 1220 µg/mL, suggesting a significant antemortem release of

tryptase due to anaphylaxis [2]. The prostate showed nodular hyperplasia with scattered foci of prostatic intraepithelial neoplasia, but there were no frank carcinomas. There were no other specific diseases or injuries that would explain the patient's sudden collapse, and thus the cause of death was diagnosed as anaphylactic shock due to the injection of gadoteridol.

Anaphylaxis from GBCAs is rare, with a reported rate ranging from 0.001% to 0.01% [3]. The number of cases of anaphylaxis from gadoteridol accounts for approximately one-sixth of those from GBCAs, and the rate of shock from gadoteridol is virtually the same as that from GBCAs (25.8% and 25.9%, respectively) [4]. However, to the best of our knowledge, there are no other published case reports of fatal anaphylaxis from gadoteridol.

The rate of immediate allergic reactions to GBCAs has been found to be significantly higher in females [5], and the rate of adverse reactions to GBCAs is reported to be higher in abdominal examinations [1]. In our survey of the literature, due to the few cases reported, we did not observe any specific tendencies regarding patient characteristics or type of MR examination in anaphylaxis from gadoteridol.

The present patient had no history of allergic disease or previous exposure to contrast agents. As a general rule, caution should be exercised in patients with a history of an adverse reaction to a GBCA or a history of allergic diseases or asthma, because the rate of immediate allergic reactions from GBCAs rises significantly in such patients (8 times higher than controls) [1,5,6]. However, in 6 of the 14 reported cases of anaphylaxis from GBCAs in the literature, there was no previous exposure to contrast media and allergic diseases [4]. Palmiere et al. [6] reported that risk factors were present only in a minority of fatal cases of anaphylaxis due to contrast agents. However, the agents they examined were mainly iodinated radiocontrast media, and GBCAs were used in only 5 cases. Four of these 5 cases had predisposing factors for anaphylaxis from GBCAs [6], but the number of cases is insufficient to provide any conclusions. In any case, it is difficult to accurately predict the possibility and severity of anaphylaxis in patients injected with a GBCA, even after checking the risks. Radiologists and physicians should be aware of the possibility of anaphylaxis from gadoteridol.

Funding

The authors declare that no funding was received for this study.

Conflicts of Interest

The authors declare that they have no conflicts of interest.

References

1. Prince MR, Zhang H, Zou Z, Staron RB, Brill PW. Incidence of immediate gadolinium contrast media reactions. *Am J Roentgenol*. 2011;196:W138-43.
2. Edston E, Ellikson O, van Hage-Hamsten M. Mast cell tryptase in postmortem serum — reference values and confounders. *Int J Legal Med*. 2007;121:275-80.
3. Runge VM. Safety of approved MR contrast media for intravenous injection. *J Magn Reson Imaging*. 2000;12:205-13.
4. Raisch DW, Garg V, Arabyat R, Shen X, Edwards BJ, Miller FH, McKoy JM, Nardone B, West DP. Anaphylaxis associated with gadolinium-based contrast agents: data from the Food and Drug Administration's adverse event reporting system and review of case reports in the literature. *Expert Opin Drug Saf*. 2014;13:15-23.
5. Jung JW, Kang HR, Kim MH, Lee W, Min KU, Han MH, Cho SH. Immediate hypersensitivity reaction to gadolinium-based MR contrast media. *Radiology*. 2012;264:414-22.
6. Palmiere C, Bonetti LR. Risk factors in fatal cases of anaphylaxis due to contrast media: a forensic evaluation. *Int Arch Allergy Immunol*. 2014;164:280-8.

■ *Manuscript received December 19, 2014; accepted for publication, February 16, 2015.*

Shirushi Takahashi

Department of Forensic Medicine
Faculty of Medicine, Saitama Medical University
38 Morohongo Moroyama-machi
Iruma-gun, Saitama 350-0495
Japan
E-mail: shirushi@saitama-med.ac.jp

Multiple Drug Allergy Due to Hypersensitivity to Polyethylene Glycols of Various Molecular Weights

Badiu I¹, Guida G², Heffler E³, Rolla G³

¹*Allergy and Lung Physiology, AO "Santa Croce e Carle", Cuneo, Italy*

²*Internal Medicine, AO "Birago di Vische", Torino, Italy*

³*Department of Medical Sciences, Allergy and Clinical Immunology, University of Torino & AO Mauriziano "Umberto I", Torino, Italy*

Key words: Multiple drug allergy. Polyethylene glycols. Macrogols. Excipient allergy.

Palabras clave: Alergia multiple a medicamentos. Polientilegicol. Macrogol. Alergia a excipientes.

Polyethylene glycols (otherwise known as macrogols or PEGs) are condensation products of glycols with ethylene oxide; the resulting molecules have various lengths and molecular weights (eg, polysorbate 80, macrogol 400, 4000, 6000, etc). Because of their stabilizing properties, macrogols are widely used as excipients, solvents, and dispersing agents in the production of foods, cosmetics, and topical and systemic drugs. Low-molecular-weight macrogols (200-700) are liquid and have been reported to cause contact dermatitis or contact urticaria as well as anaphylaxis [1]. High-molecular-weight macrogols (1000-7500) are solid and, although they are generally poorly absorbed by the gastrointestinal tract (approximately 0.2%), they have been implicated in some cases of anaphylaxis. Immediate hypersensitivity reactions have been reported after oral and parenteral administration of products containing macrogols, such as tablets, vaccines, and laxative oral solutions.

Here we describe the case of a 26-year-old woman, with no previous history of allergy, who reported many episodes of generalized urticaria within 1 hour of the intake of antibiotics (amoxicillin clavulanate and ciprofloxacin tablets) and anti-inflammatory drugs (ketoprofen granules and diclofenac tablets). The patient also manifested urticarial reactions after using cosmetic products containing PEGs.

Specific IgE antibody determinations (benzylpenicillin, ampicillin, and amoxicillin), and skin tests with major determinants (penicilloyl-polylysine) and minor determinants (minor determinant mixture) of benzylpenicillin and amoxicillin-clavulanic acid resulted negative. An oral challenge with amoxicillin clavulanate caused diffuse urticaria 30 minutes after ingestion of 45 mg of the drug. A prick test 1/1000 for ciprofloxacin 10 mg/mL resulted positive (wheal diameter, 10 mm). Oral challenges with alternative anti-inflammatory drugs (meloxicam, imidazole salicylate, and etoricoxib) caused diffuse urticaria shortly after the patient took small doses of these drugs. We noticed that all the tested drugs (including cutaneous ciprofloxacin) contained PEGs with different molecular weights (from 80 to 6000). To establish nonirritating concentrations of polysorbate 80,

PEG 400, PEG 4000, and PEG 6000 for skin tests, 10 healthy controls underwent prick and intradermal tests and showed negative responses up to 1:10 dilutions. The prick tests in the patient were positive for all PEG derivatives: polysorbate 80 (prick test 1/1000; wheal diameter, 20 mm), PEG 400 and 4000 (prick test 1/1000; wheal diameter, 10 mm), and PEG 6000 (prick test 1/100; wheal diameter, 20 mm).

Specific IgE for ethylene oxide (ImmunoCAP, Phadia) was negative. Basophil activation tests for polysorbate 80 and PEG 400, 4000, and 6000 were all negative. Oral challenges with etoricoxib, amoxicillin clavulanate, and ciprofloxacin tablets not containing PEG were all well tolerated. Once the patient had been diagnosed with hypersensitivity to PEGs, we advised her to always check the excipients listed for all kinds of drugs and cosmetics and to avoid all products containing PEGs or macrogols. She was also provided with a list of pharmaceutical products featuring commonly used drugs, such as anti-inflammatories and antibiotics, that did not contain PEGs. At the last contact, 1 year after the allergy work up, the patient reported that she taken several anti-inflammatory pills and a short course of amoxicillin and had not experienced any adverse reactions.

PEG derivatives have been implicated in immediate hypersensitivity reactions, and polysorbate 80 has been involved in the development of severe nonimmunological reactions [2]. Hypersensitivity reactions have also been reported to the following products, which all contain polysorbate 80: human papillomavirus vaccine [3], biologic drugs approved to treat severe persistent psoriasis [4], omalizumab (in 2 asthmatic patients) [5], and recombinant erythropoietin and darbepoetin [6]. There have also been reports of hypersensitivity reactions following a shoulder injection of a corticosteroid solution containing PEG 4000 [7] and ingestion of PEG solution during cleansing preparation for colon endoscopy [8].

Other cases of anaphylaxis have been reported after ingestion of tablets containing macrogols of various molecular weights (400, 1000, 4000, 6000) [1,9]. Cross-sensitization between macrogols with various molecular weights has only been occasionally investigated [10]. Yamasuji et al [10] published a case of cross-reactivity between polysorbate 80 and PEG 6000, and described a common structure: $-(CH_2CH_2O)_n-$. The authors suggested that multivalent PEG polymers may be large enough to form complete allergens without haptentation and that larger polymers would be more immunogenic. The case we report here is unique in that the patient reported systemic hypersensitivity reactions following exposure to PEGs of small and large lengths, confirmed by positive skin prick tests with all the PEG preparations tested. It is generally thought that systemic hypersensitivity reactions to PEGs depend on the dose and the route of administration. Our patient was so sensitized to PEGs that she reported a systemic reaction following as low a dose as amoxicillin 45 mg (which contains macrogol) and even after skin contact with cosmetics containing PEGs.

We have reported a case of multiple drug reaction due to hypersensitivity to PEGs of a wide variety of molecular weights, from PEG 80 to macrogol 6000. The mechanisms of such hypersensitivity reactions remain elusive, although the

timing of the clinical reactions and the positive skin prick tests suggest an IgE-mediated reaction. Nevertheless, the basophil activation tests were negative.

Funding

The authors declare that no funding was received for the present study.

Conflicts of Interest

The authors declare that they have no conflicts of interest.

References

1. Bommarito L, Mietta S, Nebiolo F, Geuna M, Rolla G. Macrogol hypersensitivity in multiple drug allergy. *Ann Allergy Asthma Immunol.* 2011;107:542-3.
2. Coors EA, Seybold H, Merk HF, Mahler V. Polysorbate 80 in medical products and nonimmunologic anaphylactoid reactions. *Ann Allergy Asthma Immunol.* 2005;95:593-9.
3. Badiu I, Geuna M, Heffler E, Rolla G. Hypersensitivity reaction to human papillomavirus vaccine due to polysorbate 80. *BMJ Case Rep.* 2012; bcr0220125797.
4. Pérez-Pérez L, García-Gavín J, Piñeiro B, Zulaica A. Biologic-induced urticaria due to polysorbate 80: usefulness of prick test. *Br J Dermatol.* 2011;164:1119-20.
5. Price KS, Hamilton RG. Anaphylactoid reactions in two patients after omalizumab administration after successful long-term therapy. *Allergy Asthma Proc* 2007;28:313-9
6. Steele R H, Limaye S, Cleland B, Chow J, Suranyi M G. Hypersensitivity reactions to the polysorbate contained in recombinant erythropoietin and darbepoietin. *Nephrology (Carlton).* 2005;10:317-20.
7. Sohy C, Vandenplas O, Sibille Y. Usefulness of oral macrogol challenge in anaphylaxis after intra-articular injection of corticosteroid preparation. *Allergy.* 2008;63:478-9.
8. Pizzimenti S, Heffler E, Gentilcore E, Raie A, Bussolino C, Nebiolo F, Rolla G. Macrogol hypersensitivity reactions during cleansing preparation for colon endoscopy. *J Allergy Clin Immunol Pract.* 2014;2:353-4.
9. Hyyry H, Vuorio A, Varjonen E, Skyttä J, Mäkinen-Kiljunen S. Two cases of anaphylaxis to macrogol 6000 after ingestion of drug tablets. *Allergy.* 2006;61:1021-3.
10. Yamasuji Y, Higashi Y, Sakanoue M, Katsue H, Kawai K, Arai N, Kanekura T. A case of anaphylaxis caused by polyethylene glycol analogues. *Contact Dermatitis.* 2013;69:183-5.

Manuscript received January 5, 2015; accepted for publication, February 20, 2015.

Iuliana Badiu

Allergologia e Fisiopatologia Respiratoria
AO "Santa Croce e Carle"
Via Carle 5, Frazione Confreria
12100 Cuneo, Italy
E-mail: iuliana.badiu@gmail.com

Burden of Skin Disease in Selective IgA Deficiency and Common Variable Immunodeficiency

Gualdi G^{1*}, Lougaris V^{2*}, Baronio M², Vitali M², Tampella G², Moratto D², Tanghetti P², Monari P¹, Calzavara-Pinton P¹, Plebani A²

¹*Dermatology Clinic, Department of Clinical and Experimental Sciences, University of Brescia, Spedali Civili di Brescia, Italy*

²*Pediatrics Clinic and Institute for Molecular Medicine A. Nocivelli, Department of Clinical and Experimental Sciences, University of Brescia, Spedali Civili di Brescia, Italy*

*These authors contributed equally to this work

Key words: Selective IgA deficiency (SIgAD). Common Variable Immunodeficiency (CVID). Atopic dermatitis (AD). Psoriasis.

Palabras clave: Deficiencia selectiva de IgA. Inmunodeficiencia común variable. Dermatitis atópica. Psoriasis.

Skin manifestations are an important clinical feature of several primary immunodeficiencies disorders (PIDs), such as granulocyte defects, hyper-IgE syndrome (HIES), and severe combined immunodeficiency (SCID). These manifestations may be related to infectious complications, such as skin abscesses/infections (eg, chronic granulomatous disease, congenital neutropenia, HIES), to chronic eczema/dermatitis (eg, Omenn syndrome, HIES), or to both (eg, HIES). In these rare forms of PIDs, cutaneous manifestations are frequently a hallmark of disease. While humoral immunodeficiencies, such as common variable immunodeficiency (CVID) and selective immunoglobulin A deficiency (SIgAD), are more common, there is little specific information on skin involvement in these disorders.

In order to evaluate the incidence of skin involvement in SIgAD and CVID, we carried out a longitudinal, prospective, clinical study of 147 patients with SIgAD or CVID consecutively followed at our center over a 16-month period (September 2012-January 2014). Diagnosis in both cases was based on the criteria of the European Society for Immunodeficiencies. One-hundred-and-two patients had SIgAD (male to female ratio, 0.55:0.45; mean age, 8.6 years), while 47 patients had CVID (male to female ratio, 0.57:0.43; mean age, 23.4 years). The majority of patients with SIgAD were symptomatic, at least at diagnosis. All patients were evaluated by the same dermatologist during routine outpatient visits. Diagnosis of skin involvement was based on clinical criteria (with application of Hanifin-Rajka criteria for atopic dermatitis [AD]) and on skin biopsies where applicable.

AD is the most common skin disorder in childhood, with a reported prevalence of up to 25% [1]. In the cohort of patients with SIgAD, 59 (57.84%) had AD, compared with just 9 (19.14%, ie, within the normal range) in the group of patients with CVID (Table A). Serum IgE levels were elevated in just 6 (10.17%) of the 59 SIgAD patients with AD, suggesting that there is no direct correlation between IgE serum levels and the presence of AD in this disorder. The

reasons for this particularly high incidence of AD in SIgAD have not yet been established. Psoriasis typically affects approximately 2% to 4% of the general population [2]. While this prevalence was confirmed in the SIgAD cohort (2/102 patients; 1.96%), it was much higher in the CVID cohort (9/47 patients; 19.14%) (Table A), and particularly in those with the infectious phenotype and/or enteropathy (Table B). This high incidence of psoriasis in CVID has not been previously reported. Contributing factors may include T-cell imbalance or other immune-related dysregulation mechanisms. In one study, T-cell analysis of CVID patients with (n=5) and without (n=12) psoriasis showed a statistically significant increase in CD4⁺ central memory T cells in the group of patients with psoriasis [3]. While no differences were detected between the 2 groups for CD8⁺ central memory T cells, an increased percentage of this subset has been reported in psoriatic patients without CVID compared with healthy controls [3]. Two of the 102 patients in the SIgAD group developed a localized, easy-to-treat skin infection. This type of infection, which is typically seen in otherwise healthy individuals, was the only infectious skin condition observed in the SIgAD group. Skin infections were much more common in the CVID group (7/47 patients, 14.89%) (Table A) and required systemic antibiotic treatment. It is likely that this higher rate of infections may be related to the more severe immunological defects that characterize CVID as compared with SIgAD.

Acne occurs in 15% to 20% of healthy individuals, with prevalence peaking in adolescence [4]. In our series, acne was found in 5.88% (6/102) of the SIgAD patients, in line with reference values, but in 12.77% (6/47) of the CVID patients (Table A), most of whom had the infectious CVID phenotype (Table B). This would appear to be an interesting and novel finding, since the patients in the CVID group (mean age, 23.4 years) had largely passed adolescence, which is when acne is particularly prevalent. Again, the more severe immunological defects that characterize CVID may explain these results. Similarly to acne, recurrent aphthosis (in the absence of celiac disease) was more common in CVID (5/47, 10.63%) than in SIgAD (5/102, 4.90%) (Table A). Vitiligo was observed with a similar frequency in SIgAD (3/102, 3.06%) and CVID (2/47, 4.25%) (Table A), with values comparable to those reported for the general population (2%-8%) [5]. Finally, alopecia areata was observed in 1 patient with CVID and 1 patient with SIgAD.

As previously published studies of skin manifestations in PIDs have contemplated all forms of PID [6-9], relatively few patients with CVID or SIgAD have been studied, preventing a comprehensive picture of skin manifestations in these 2 disorders. Our data strongly suggest that skin involvement in patients with SIgAD and CVID (and particularly those with certain CVID phenotypes) is an underestimated cause of comorbidity. Certain skin conditions that were particularly

Table. Features of Patients With Selective IgA deficiency (SIgAD) and Common Variable Immunodeficiency (CVID) Included in this Study

A. Incidence of skin involvement

	SIgAD	CVID
<i>Skin Manifestation</i>	No. (%)	No. (%)
Atopic dermatitis	59/102 (57.84)	9/47 (19.14)
Psoriasis	2/102 (1.96)	9/47 (19.14)
Skin infections	2/102 (1.96)	7/47 (14.89)
Acne	6/102 (5.88)	6/47 (12.77)
Alopecia	1/102 (0.09)	1/47 (2.12)
Vitiligo	3/102 (3.06)	2/47 (4.25)
Recurrent aphthosis	5/102 (4.90)	5/47 (10.63)

B. Distribution of skin manifestations in CVID patients based on phenotype

<i>Skin Manifestation</i>	Phenotype						No. (%)
	Inf	Ent	AC	Inf+Ent	Inf+AC	Inf+LD	
Atopic dermatitis	IIII			II	I	I	9/47 (19.14)
Psoriasis	IIII	I	I	I	I		9/47 (19.14)
Skin infections	III	I	I	I	I		7/47 (14.89)
Acne	IIII					I	6/47 (12.77)
Alopecia	I						1/47 (2.12)
Vitiligo	II						2/47 (4.25)
Recurrent aphthosis	IIII			II	I		5/47 (10.63)

Abbreviations: AC, autoimmune cytopenia; Ent, enteropathy; Inf, infectious; LD, lymphoproliferative disease.

common in our series (eg, AD in SIgAD and psoriasis in CVID) can negatively affect patient quality of life if misdiagnosed and not appropriately treated. Routine dermatological evaluation in SIgAD and CVID allows for accurate and timely diagnosis and treatment of skin diseases.

Acknowledgments

We would like to thank Fondazione Camillo Golgi and Comunità Bresciana, Brescia, Italy. We would also like to thank the patients, the patients' families and the nurses for all their efforts.

Funding

The research leading to these results received funding from the European Community's Seventh Framework Programme FP7/2007-2013 under grant agreement no. 201549 (EURO-PADnet HEALTH-F2-2008-201549) and from the Italian Ministerial Grant GR-2010-2315762. The same research also received funding from the "Fondazione C. Golgi", Brescia.

Conflicts of Interest

The authors declare that they have no conflicts of interest.

References

- Eichenfield LF, Tom WL, Chamlin SL, Feldman SR, Hanifin JM, Simpson EL, Berger TG, Bergman JN, Cohen DE, Cooper KD, Cordoro KM, Davis DM, Krol A, Margolis DJ, Paller AS, Schwarzenberger K, Silverman RA, Williams HC, Elmetts CA, Block J, Harrod CG, Smith Begolka W, Sidbury. Guidelines of care for the management of atopic dermatitis: section 1. Diagnosis and assessment of atopic dermatitis. *J Am Acad Dermatol* 2014 Feb;70(2):338-51.
- Fotiadou C, Lazaridou E, Ioannides D. Management of psoriasis in adolescence. *Adolesc Health Med Ther* 2014 Mar 14;5:25-34.
- Hayashi M, Furuhashi T, Nishida E, Saito C, Torii K, Morita A. Increased population of central memory T cells in circulating peripheral blood of psoriasis patients. *J Dermatol Sci*. 2013 Apr;70(1):61-4.
- Bhate K, Williams HC. Epidemiology of acne vulgaris. *Br J Dermatol* 2013 Mar;168(3):474-85.
- Kruger C, Schallreuter KU. A review of the worldwide prevalence of vitiligo in children/adolescents and adults. *Int J Dermatol* 2012 Oct;51(10):1206-12.
- Berron-Ruiz A, Berron-Perez R, Ruiz-Maldonado R. Cutaneous Markers of Primary Immunodeficiency Diseases in Children", *Pediatric Dermatology* 2000; 17 (2): 91-96
- Moin A, Farhoudi A, Pourpack Z, Bazargan N. Cutaneous Manifestations of Primary Immunodeficiency Disease in Children. *Iran J Allergy Asthma Immunol* 2006 September; 5(3):121-126
- Al-Herz W, Nanda A. Skin Manifestations in Primary Immunodeficient Children. *Pediatric Dermatology* 2011; 28(5): 494-501
- Sillevis Smitt JH, Kuijpers TW. Cutaneous manifestations of primary immunodeficiency. *Curr Opin Pediatr*. 2013 Aug;25(4):492-7.

■ Manuscript received December 13, 2014; accepted for publication, February 24, 2015.

Vassilios Lougaris

Pediatrics Clinic and Institute of Molecular Medicine "A. Nocivelli",
University of Brescia, Piazzale Spedali Civili 1,
25123, BRESCIA, ITALY
E-mail: vlougarisbs@yahoo.com

Immediate-Type Hypersensitivity to Atracurium: Use of the Stimulation Index as the Optimal Positivity Threshold for the Flow-Assisted Basophil Activation Test

Petrișor C¹, Gherman N², Sfichi M³, Cociș M¹, Hagău N¹

¹Department of Anaesthesia and Intensive Care, University of Medicine and Pharmacy "Iuliu Hatieganu," Cluj-Napoca, Romania

²Department of Allergology and Immunology, University of Medicine and Pharmacy "Iuliu Hatieganu," Cluj-Napoca, Romania

³Department of Immunopathology, Clinical Emergency County Hospital Cluj, Cluj-Napoca, Romania

Key words: Atracurium. Basophil activation test. Flow cytometry. Hypersensitivity.

Palabras clave: Atracurio. Test de activación de basófilos. Citometría de flujo. Hipersensibilidad.

Atracurium-induced immediate-type hypersensitivity reactions have a low prevalence but may cause life-threatening conditions [1]. Reliable, highly sensitive tests are needed to confirm the diagnosis retrospectively. The flow-assisted basophil activation test (BAT) is a useful in vitro method for the diagnosis of hypersensitivity to neuromuscular blocking agents (NMBAs), although the methodology and optimal decision thresholds for BAT vary considerably from one study to another [2-8].

We designed the present study to identify the optimal BAT threshold for atracurium. The threshold was expressed as the stimulation index (SI) and as the net percentage of activated basophils.

The study was approved by the Ethics Committee of University of Medicine and Pharmacy "Iuliu Hatieganu" in Cluj-Napoca, Romania, and all the patients signed an informed consent form. We included 12 patients who had experienced drug hypersensitivity reactions during general anesthesia with atracurium and had positive skin test results for atracurium. The control group included 15 patients with no previous drug allergies who underwent surgery, tolerated intravenous atracurium, and had negative skin test results for atracurium. The skin tests included a skin prick test (1 mg/mL) and an intradermal test (10 µg/mL) [9,10].

BAT was performed using the Flow2CAST technique with human chemokine receptor coupled to phycoerythrin antibodies (anti-CCR3-PE) and anti-CD63-FITC antibodies (a glycoprotein expressed on the activated basophils) (Bühlmann Laboratories AG) [7]. Atracurium was tested at 2.5 mg/mL, 0.25 mg/mL, and 0.025 mg/mL. Upregulation of CD63, the activation marker on basophils, was measured using Cell Quest (FACSCalibur, Becton Dickinson).

For each individual patient and control, the highest SI and the highest net percentage of activated basophils from all 3 atracurium concentrations were used in the receiver operating

characteristic (ROC) curve analysis to calculate the optimal threshold values that reflected the best in vitro response to stimulation with atracurium. The SI was calculated as the percentage of activated basophils after stimulation divided by the number of basophils with no atracurium stimulation. The net percentage of activated basophils was calculated by subtracting the negative control from the value obtained after stimulation with atracurium. The SI was supplemented with an additional criterion, namely, the percentage of activated basophils had to be higher than 5% in order to avoid mild, nonspecific stimulation. Sensitivity was calculated as the number of patients with positive BAT results divided by the total number of patients, while specificity was calculated as the number of controls with a negative BAT result divided by the total number of controls. The 2 matched results were compared using the McNemar exact test.

Of the 12 patients with hypersensitivity reactions to atracurium, 5 had positive results in the skin prick test and 7 had positive results in the intradermal test. The clinical symptoms were bronchospasm in 1 patient, angioedema in 2, urticaria in 1, hypotension in 1, and anaphylactic shock in 7.

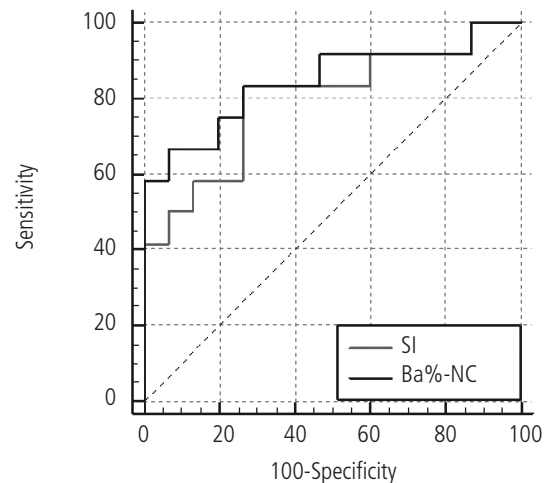


Figure. Receiver operating characteristic curve analysis performed with the SI and the net percentage of activated basophils (Ba%-NC) as a threshold for basophil activation test positivity. The SI was calculated as the ratio of Ba% divided by the NC. SI indicates stimulation index; Ba, percentage of activated basophils after in vitro stimulation with atracurium; NC, negative control.

The ROC curve constructed with the highest SI of the 3 atracurium concentrations vs history yielded an SI >1.85 as the optimal threshold for BAT positivity, with an AUC of 0.79 (95%CI, 0.61%-0.97%; $P=0.0097$) (Figure). With a cutoff of 1.85 as the only diagnostic criterion, the sensitivity of BAT was 83.33% (95%CI, 51.59%-97.91%) and the specificity was 73.33% (95%CI, 44.90%-92.21%). When the additional criterion (percentage of activated basophils >5%) was applied, 8 of the 12 patients had a positive BAT result, while none of the controls had a positive BAT result. Thus, the sensitivity of the tests was 66.66% and the specificity 100%.

One patient had a positive BAT result for all 3 concentrations tested, 3 patients for 2.5 mg/mL only, 1 patient for both 2.5 mg/mL and 0.25 mg/mL, and 3 patients for both 0.25 mg/mL and 0.025 mg/mL.

ROC analysis performed with the net percentage of activated basophils revealed >3.84% to be the optimal threshold value for BAT positivity, with an AUC of 0.84 (95%CI, 0.68%-1%; $P=0.025$) (Figure). Considering >3.84% as the threshold for BAT positivity, sensitivity was 58.33% (95%CI, 27.6%-84.83%) and specificity 100% (95%CI, 78.20%-100%).

No statistically significant differences were detected between the results obtained using the 2 different cutoffs (McNemar test, $P=1$).

Several previous studies on NMBAs as a drug class have identified different thresholds for BAT positivity (activated basophils ranging from 10% to 15%) [2-5]. As an extrapolation from antibiotic flow cytometry, the manufacturers recommend an optimal cutoff SI of >2 together with a percentage of activated basophils after stimulation >5%. For BAT, using a universal decision threshold for all NMBAs is difficult to justify [1], since each substance might have a specific cutoff value. The optimal thresholds we found for atracurium were as follows: SI >1.85 (with 66.66% sensitivity) and net percentage of activated basophils >3.84% (with 58.33% sensitivity). Specificity was 100% in both cases.

The optimal threshold for the percentage of activated basophils has been shown to be 4% for rocuronium [6] and 5% for atracurium [8]. We identified an optimal threshold of 3.84%, which is very close to the 2 thresholds cited above. By applying a cutoff of 4% in our patients, we would have found the same sensitivity and specificity values as for 3.84%. The sensitivity value we found for atracurium was close to that reported by Ebo et al [6]. We did not find an optimal atracurium concentration for basophil stimulation in hypersensitive patients, whose *in vitro* responses to atracurium challenge were markedly heterogeneous.

The association between the 2 BAT-matched results was significant for the individual patients: only 1 patient had a positive BAT result based on SI and a negative BAT result based on net percentage of activated basophils. Larger study populations—viable only using multicenter studies, owing to the low prevalence of the disease—and a standardized methodological approach are needed to evaluate the superiority of using one threshold over the other or to demonstrate their equivalency.

Acknowledgments

We are grateful to Mr Nicolae Todor for advice on the statistical analysis.

Funding

Financial support was received from National Plan II, Priority Domain Partnership Romania (number 41-062/2007).

Conflicts of Interest

The authors declare that they have no conflicts of interest.

References

1. Ebo DG. The basophil activation test in the diagnosis of anaesthesia-related allergy. *Revue française d'allergologie et d'immunologie clinique*. 2008;48:214-6.
2. Abuaf N, Rajoely B, Ghazouani E, Levy DA, Pecquet C, Chabane H, Leynadier F. Validation of a flow cytometric assay detecting *in vitro* basophil activation for the diagnosis of muscle relaxant allergy. *J Allergy Clin Immunol*. 1999;104:411-8.
3. Monneret G, Benoit Y, Debard AL, Gutowski MC, Topenot I, Biennu J. Monitoring of basophil activation using CD63 and CCR3 in allergy to muscle relaxant drugs. *Clin Immunol*. 2002;102:192-9.
4. Sudheer PS, Hall JE, Read GF, Rowbottom AW, Williams PE. Flow cytometric investigation of peri-anaesthetic anaphylaxis using CD63 and CD203c. *Anaesthesia*. 2005;60:251-6.
5. Kvedariene V, Kamey S, Ryckwaert Y, Rongier M, Bousquet J, Demoly P, Arnoux B. Diagnosis of neuromuscular blocking agent hypersensitivity reactions using cytofluorimetric analysis of basophils. *Allergy*. 2006;61:311-5.
6. Ebo DG, Bridts CH, Hagendorens MM, Mertens CH, De Clerck LS, W. J. Stevens WJ. Flow-assisted diagnostic management of anaphylaxis from rocuronium bromide. *Allergy*. 2006;61:935-9.
7. Hagau N, Gherman-Ionica N, Sfichi M, Petrişor C. Threshold for basophil activation test positivity in neuromuscular blocking agents hypersensitivity reactions. *Allergy Asthma Clin Immunol*. 2013;9:42.
8. Uyttebroek AP, Sabato V, Leysen J, Bridts CH, De Clerk LS, Ebo DG. Flowcytometric diagnosis of atracurium-induced anaphylaxis. *Allergy*. 2014;69:1324-32.
9. Mertes PM, Laxenaire MC, Lienhart A, and the working group of the SFAR and Aberer W, Ring J, Pichler WJ, Demoly P, for ENDA and the EAACI interest group on drug hypersensitivity. Reducing the risk of anaphylaxis during anaesthesia: guidelines for clinical practice. *J Invest Allergol Clin Immunol*. 2005;15:91-101.
10. Demoly P, Piette V, Bousquet J. *In vivo* methods for study of allergy: skin tests, technique and interpretation. In: Adkinson NF Jr, Yunginger JW, Busse WW, Bochner BS, Holgate TS, Simons FER, editors. *Middleton's Allergy, Principles and Practice*. 6th ed. Philadelphia, Pennsylvania: Mosby; 2003. p.631-43.

■ Manuscript received January 16, 2015; accepted for publication February 26, 2015.

Natalia Hagău

Department of Anaesthesia and Intensive Care
Clinical Emergency County Hospital of Cluj
400006 Clinicilor 3-5, Cluj-Napoca, Romania
E-mail: hagaunatalia@gmail.com

A Case of Anaphylaxis After Garlic Ingestion: Is Alliinase the Only Culprit Allergen?

Treudler R¹, Reuter A², Engin AM², Simon JC¹

¹Department of Dermatology, Venereology and Allergology, Universität Leipzig, Leipzig, Germany

²Division of Allergology, Paul-Ehrlich-Institut, Langen, Germany

Key words: Garlic. Food allergy. Oral food challenge. Alliinase. Mass spectrometry.

Palabras clave: Ajo. Alergia alimentaria. Provocación oral con alimentos. Alliinasa. Espectrometría de masas.

Allergic reactions to garlic (*Allium sativum*) occur mainly after inhalation of or contact with spice dust [1], while ingestion only rarely induces immediate-type reactions (2-5). Only 1 allergen, alliinase, has been identified to date [6], and very little information is available on cross-reactivity to other allergens.

We report the case of a 48-year-old man with seasonal allergic rhinitis and gastroesophageal reflux disease who presented with a history of generalized urticaria, angioedema, and vomiting 20 minutes after ingestion of döner kebab with garlic sauce. On a second occasion, he experienced urticaria, angioedema, and hypotension a few minutes after eating tzatziki (yoghurt, cucumber, garlic, olive oil, vinegar, and pepper). Garlic and other foods of the Amaryllidaceae family (eg, onion, shallot, leek, and chives) and asparagus (belonging to the same order as garlic, Asparagales) had been well tolerated before the immediate-type reactions, as were cucumber, vinegar, and pepper thereafter. The patient had been taking omeprazole for 6 months, and this may have facilitated sensitization to food allergens [7].

We performed a skin prick test with inhalant allergens and foods and determined specific IgE and serum tryptase levels (CAP FEIA, ThermoFisher). On 2 separate days, the patient underwent an open oral provocation test (OPT) with up to 4 black olives and with 6 increasing doses of ripe raw garlic clove (0.025, 0.05, 0.1, 0.2, 0.4, and 0.9 g) at 30-minute intervals. Blinding of garlic during the OPT was not possible because of the intense odor.

Garlic proteins were extracted from the cloves of ripe garlic using NH₄HCO₃, phosphate-buffered saline (PBS), and Tris pentaborate buffer and pooled. Ten micrograms of protein was separated using 2-dimensional electrophoresis. The first dimension was performed on a Protean IEF Cell (BioRad), the second separation was performed on an Invitrogen XCell Sure Lock Mini Cell system (Whatman Protran BA83). Immunodetection was performed with the patient's serum (diluted 1:24 in PBS) and a horseradish peroxidase-labelled mouse monoclonal antibody targeting human IgE (Southern Biotechnology). SYPRO Ruby-stained protein spots were manually matched with IgE-reactive spots on membranes, excised, and subjected to tryptic digestion and mass spectrometry (MS) as published elsewhere [8] and modified according to Berkner et al [9]. Data were analyzed

using Protein Lynx Global Server version 2.4 (Waters) after searching the UniProt database (March 2012) with restriction to entries for green plants and applying standard parameters.

Skin prick testing for inhalant allergens (birch, timothy grass, mugwort, ragweed, cat, and mite [ALK-Abelló] and with sodium chloride as a negative control revealed urticaria factitia. As the prick-to-prick tests with native garlic sauce, a clove of fresh raw garlic, and tzatziki produced a wheal at least twice the size of the positive control (histamine chloride, ALK-Abelló), the reactions were considered positive. Specific IgE was positive for garlic (10.30 kU_A/L), mugwort (9.30 kU_A/L), onion (6.75 kU_A/L), celery (7.33 kU_A/L), bell pepper (5.74 kU_A/L), Ole e 1 (8.22 kU_A/L), black olive (2.34 kU_A/L), oregano (1.53 kU_A/L), thyme (1.04 kU_A/L), and MUX-F3/Ana c 2 (7.7 kU_A/L). Specific IgE was negative for rBet v 1, rBet v 2, rPru p 3, and milk protein. Total serum IgE was 713 kU/L, and serum tryptase levels were within the normal range.

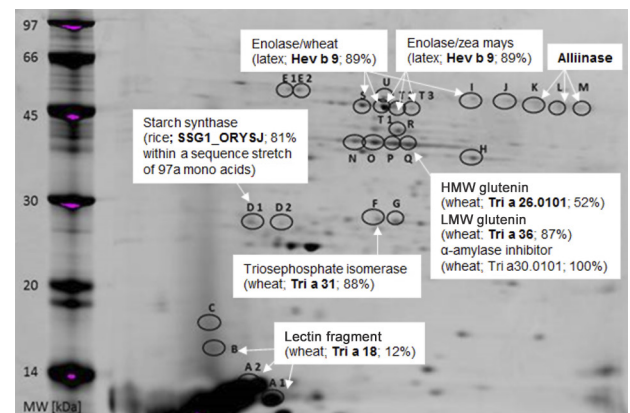


Figure. Dimensional map of raw garlic clove. Marked protein spots were found to bind to IgE from human serum (data not shown) and underwent mass spectrometry. We identified alliinase and 8 proteins showing sequence homology (given in percent) with rice (*Ory s*), latex (*Hev b*), or wheat (*Tri a*). HMW indicates high-molecular-weight; LMW, low-molecular-weight.

The result of the OPT with olives was negative. However, 20 minutes after intake of 0.9 g of raw garlic (cumulative dose of 1.675 g), the patient reported headaches and presented flush, urticaria, shortness of breath, and hypotension (blood pressure, 80/40 mmHg). The symptoms resolved completely after emergency treatment with intramuscular adrenaline. The patient refused to undergo further OPT.

In vitro investigations detected IgE binding to 27 spots (data not shown), which contained a total of 16 different proteins (Figure). The proteins identified by mass spectrometry were as follows: alliinase, a protein previously described as a garlic allergen [2,6]; 7 proteins that were likely irrelevant; and 8 proteins possibly representing novel garlic clove allergens (ie, enolase [twice], high-molecular-weight and low-molecular-weight glutenin, alpha-amylase inhibitor, triosephosphate isomerase, starch synthase, and lectin fragment).

In conclusion, we present a rare case of anaphylaxis after ingestion of garlic in an atopic man. The patient did not recall any previous adverse events to any of the foods with positive

IgE results except for garlic. False-positive signals were suspected of being at least partly induced by cross-reactions (eg, to MUX-F3). The patient refused to undergo further OPT and was therefore advised to eliminate all foods of the Amaryllidaceae family and asparagus, which often causes cross-reactions. An emergency kit was prescribed.

The allergens identified in the present case were alliinase and 8 potential novel garlic clove allergens, which showed sequence identity of between 12% and 100% with allergens reported for rice, latex, or wheat. We found no clinically relevant allergy to any of these allergens in the patient described here.

Kao et al [6] had already identified alliinase with a molecular weight of 56 kD as a major allergen of garlic in a Taiwanese patient with anaphylaxis. The allergen was suspected of being heat-labile. In contrast, Asero et al [2] identified a 10-kD heat-resistant allergen in a patient who experienced urticaria upon ingestion of raw and cooked garlic. In the present case, we observed IgE binding to alliinase, which may confirm the allergenicity of this protein. We also observed IgE binding to several other proteins, which may be novel garlic allergens.

Funding

The authors declare that no funding was received for the present study.

Conflicts of Interest

The authors declare that they have no conflicts of interest.

References

- van der Walt A, Singh T, Baatjies R, Lopata AL, Jeebhay MF. Work-related allergic respiratory disease and asthma in spice mill workers is associated with inhalant chili pepper and garlic exposures. *Occup Environ Med*. 2013 Jul;70(7):446-52.
- Asero R, Mistrello G, Roncarolo D, Anonioti PL, Falagiani P. A case of garlic allergy. *J Allergy Clin Immunol*. 1998 Mar;101(3):427-8.
- Pérez-Pimiento AJ, Moneo I, Santaolalla M, de Paz S, Fernández-Parra B, Domínguez-Lázaro AR. Anaphylactic reaction to young garlic. *Allergy*. 1999 Jun;54(6):626-9.
- Vovolis V, Kalogiros L, Ivanova D, Koutsostathis N. Garlic-induced severe anaphylaxis in a nonatopic patient. *J Investig Allergol Clin Immunol*. 2010;20(4):356.
- Ma S, Yin J. Anaphylaxis induced by ingestion of raw garlic. *Foodborne Pathog Dis*. 2012 Aug;9(8):773-5.
- Kao SH, Hsu CH, Su SN, Hor WT, Chang T WH, Chow LP. Identification and immunologic characterization of an allergen, alliin lyase, from garlic (*Allium sativum*). *J Allergy Clin Immunol*. 2004 Jan;113(1):161-8.
- Untersmayr E, Schöll I, Swoboda I, Beil WJ, Förster-Waldl E, Walter F, Riemer A, Kraml G, Kinaciyar T, Spitzauer S, Boltz-Nitulescu G, Scheiner O, Jensen-Jarolim E. Antacid medication inhibits digestion of dietary proteins and causes food allergy: a fish allergy model in BALB/c mice. *J Allergy Clin Immunol*. 2003 Sep;112(3):616-23.
- Albrecht M, Alessandri S, Conti A, Reuter A, Lauer I, Vieths St, Reese G. High level expression, purification and physico- and immunochemical characterisation of recombinant Pen a 1: a major allergen of shrimp. *Mol Nutr Food Res*. 2008;52(Suppl 2):186-95.
- Berkner H, Seutter von Loetzen C, Hartl M, Randow S, Gubesch M, Vogel L, Husslik R, Reuter A, Lidholm J, Ballmer-Weber B, Vieths S, Rösch P, Schiller D. Enlarging the Toolbox for Allergen Epitope Definition with an Allergen-Type Model Protein. *Gay N, ed. PLoS ONE* 2014;9(10):e111691. doi:10.1371/journal.pone.0111691.

■ *Manuscript received January 20, 2015; accepted for publication February 26, 2015.*

Regina Treudler

Department of Dermatology, Venereology und Allergology,
Universität Leipzig,
Philipp-Rosenthal-Straße 23
04103 Leipzig
Germany
E-mail: regina.treudler@uniklinik-leipzig.de

Hedgehog Allergy: New Pet, Old Allergens

Núñez-Acevedo B¹, Domínguez-Ortega J², Rodríguez-Jiménez B³, Kindelan-Recarte C³, Jimeno-Nogales L⁴

¹Allergy Unit, Hospital Universitario de Getafe, Madrid, Spain.
Current position Hospital Universitario Infanta Sofía, San Sebastián de los Reyes, Madrid, Spain

²Allergy Department, IDIPAZ, Hospital Universitario La Paz, Madrid, Spain

³Allergy Unit, Hospital Universitario de Getafe, Madrid, Spain

⁴Research and Development Department, ALK-Abelló, Madrid, Spain

Key words: Hedgehog. Lipocalin. Serum albumin.

Palabras clave: Erizo. Lipocalina. Albúmina sérica.

The presence of exotic pets in homes has increased in recent years. Although cats and dogs remain the leading cause of respiratory and cutaneous allergies produced by domestic pets, the growing presence of nontraditional pets has led to a parallel increase in allergic disorders, including respiratory disease caused by inhalation of particles, contact urticaria, or reactions secondary to bites [1]. The clinical cases reported in the literature include reactions caused by contact with mammals (eg, ferrets, gerbils, mice, rabbits, hamsters, monkeys, hedgehogs, prairie dogs, and chinchillas), reptiles (eg, iguanas, chameleons, lizards, rattlesnakes, and king cobras), birds (eg, lovebirds, cockatiels, pheasants, canaries, parakeets, parrots, geese, and owls), spiders, and cockroaches [1-4]. We present the case of a 26-year-old woman with a 1-year history of respiratory problems manifesting as moderate persistent rhinoconjunctivitis, dyspnea, cough, and persistent audible wheezing requiring sustained treatment with inhaled corticosteroids and frequent bronchodilator rescue medication. The patient reported no seasonal variations in the symptoms, but claimed that they improved during a 2-week vacation away from home. For the last 3 years, she had kept 2 African pygmy hedgehogs and explained that her respiratory symptoms worsened on cleaning their cage and the room in which they were located, as well as on picking up the animals. Physical examination revealed cough at the end of expiration. The remaining findings were normal. Prick testing was performed with a standard battery of aeroallergens including pollen (grasses, olive, *Platanus hispanica*, plantago, and *Cynodon*, *Arizonica*, *Artemisia*, and *Chenopodium* species), house dust mites (*Dermatophagoides pteronyssinus*, *Dermatophagoides farinae*), warehouse dust mites (*Tyrophagus*, *Blomia*, *Euroglyphus*, and *Lepidoglyphus* species), animal dander (cats and dogs), fungi (*Alternaria* and *Aspergillus* species), latex, and peach lipid transfer protein, with positive results for grass pollen mix (4×5 mm), olive pollen (3×4 mm), and *D pteronyssinus* (6×7 mm). Blood testing revealed eosinophilia (1300/μL) and positive IgE levels for Ole e 1 (28.9 kU_A/L), grass pollen (1.23 kU_A/L), and *D pteronyssinus* (0.15 kU_A/L) (ImmunoCAP, Phadia). Respiratory function tests were performed (under treatment with inhaled corticosteroids).

Fractional exhaled nitric oxide was 47 ppb, forced expiratory volume in 1 second (FEV₁) was 114% (3.98 L), forced vital capacity (FVC) was 107% (4.79 L), and FEV₁/FVC was 83.03%. The bronchodilation test result was negative. Chest x-ray findings were normal. An extract (wt/vol) was prepared with material supplied by the patient, including hedgehog dander and spines, which tested positive (6×5 mm). Negative controls (2 atopic patients and 2 nonatopic patients) had negative results with this extract. With the aim of identifying the protein responsible for the patient's symptoms, we also conducted an in vitro study using prepared extracts of hedgehog dander and spines. Both the extracts and the molecular weight markers were analyzed using tricine-based SDS-PAGE (acrylamide concentration, 10%-20%) under nonreducing conditions followed by electrophoretic transfer to nitrocellulose paper strips [5]. After transfer, the strips were saturated with 1% casein in phosphate-buffered saline (PBS) for 1 hour at room temperature and then incubated for approximately 18 hours with the patient's serum diluted 1:5. A nitrocellulose paper strip containing each of the extracts was

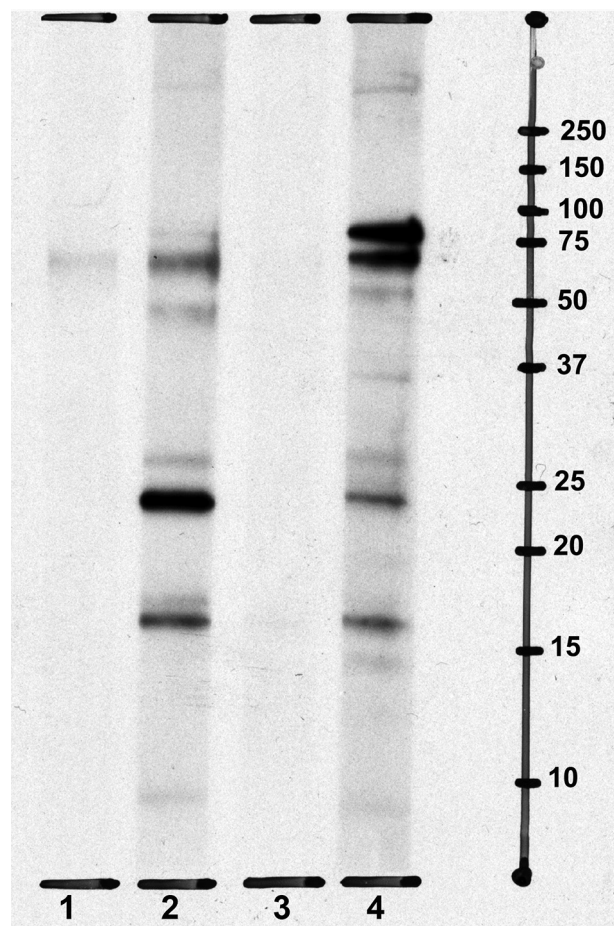


Figure. Immunoblotting with hedgehog dander and spines. Lane 1, dander extract + negative control; lane 2, dander extract + patient serum; lane 3, spine extract + negative control; lane 4, spine extract + patient serum. The molecular weight markers (in kDa) are shown on the right.

incubated with 1% casein in PBS as a negative control. After washing with 0.1% Tween-20 in PBS, the strips were incubated for 2 hours at room temperature with ascitic fluid containing human anti-IgE monoclonal antibody HE-2 and diluted 1:3000 [6]. After further washing, the strips were incubated for 1 hour at room temperature with rabbit antimouse IgG antibody labeled with peroxidase (RAM-HRP, Calbiochem) and diluted 1:5000. Lastly, the strips were washed and IgE-binding proteins were detected using chemiluminescence (ECL, Amersham Bioscience), according to the manufacturer's instructions. The Figure shows the IgE immunodetection results. Several bands were observed for the extracts of spines and dander. The bands corresponded to different molecular weights (15-17 kDa, 20-25 kDa, and 50-75 kDa). The patient was advised to remove the hedgehogs from her home. Ten months later, her respiratory symptoms had improved considerably, and she only required occasional use of a short-acting bronchodilator.

We present the case of a patient with respiratory allergy secondary to inhalation of hedgehog particles. Hedgehog allergy has been reported elsewhere [4,7], although to our knowledge this is the first time the proteins potentially responsible for symptoms have been identified. Most mammal proteins implicated in allergic reactions come from 3 families: lipocalins, serum albumins, and secretoglobulins [8]. Lipocalins have a molecular weight of 25-27 kDa and are highly soluble. They are present in fluids and secretions and are involved in the transport of hydrophobic molecules. Serum albumins are the most abundant proteins in mammalian plasma and are essential for maintaining oncotic pressure. Their molecular weight is approximately 67 kDa. In the case we report, proteins were identified in both dander and spines. Those of the lowest molecular weight, which were more intensely expressed in dander, could correspond to lipocalins, whereas those of the highest molecular weight, which were more intensely expressed in spines, could correspond to serum albumins. Therefore, despite the increasingly widespread presence of exotic pets in homes, the associated pattern of allergens implicated in the development of allergic diseases seems to be similar to that found in traditional pets.

Funding

The authors declare that no funding was received for the present study.

Conflicts of Interest

Lucía Jimeno-Nogales is an employee of ALK-Abelló. The remaining authors declare that they have no conflicts of interest.

References

- Díaz-Perales A, González-de-Olano D, Pérez-Gordo M, Pastor-Vargas C. Allergy to uncommon pets: new allergies but the same allergens. *Front Immunol*. 2013;4:492.
- Phillips JF, Lockey RF. Exotic pet allergy. *J Allergy Clin Immunol*. 2009;123(2):513-5.
- Marenco-Arellano V, Bartolome B, Reaño-Martos M, Marrero C, Rodríguez-Cabreros M, Iglesias-Cadarso A. New pets, new allergies. *Allergol Immunopathol (Madr)*. 2012;40(2):128-9.
- Slavin RG. The tale of the allergist's life: a series of interesting case reports. *Allergy Asthma Proc*. 2008;29(4):417-20.
- Towbin H, Staehelin T, Gordon J. Electrophoretic transfer of proteins from polyacrylamide gels to nitrocellulose sheets: procedure and some applications. *Proc Natl Acad Sci U S A*. 1979;76(9):4350-4.
- Sánchez-Madrid F, Morago G, Corbi AL, Carreira J. Monoclonal antibodies to three distinct epitopes on human IgE: their use for determination of allergen-specific IgE. *J Immunol Methods*. 1984;73(2):367-78.
- Fairley JA, Suchniak J, Paller AS. Hedgehog hives. *Arch Dermatol*. 1999;135(5):561-3.
- Aalberse RC. Mammalian airborne allergens. *Chem Immunol Allergy*. 2014;100:243-7.

■ *Manuscript received December 22, 2014; accepted for publication March 5, 2015.*

Beatriz Núñez-Acevedo

E-mail: bnunezacevedo@yahoo.es

Incidence of the C104R *TACI* Mutation in Patients With Primary Antibody Deficiency

Lucena JM, Burillo Sanz S, Núñez-Roldan A, Sánchez B
*Hospital Universitario Virgen del Rocío, Servicio de Inmunología,
 Sevilla, Spain*

Key words: Common variable immunodeficiency. C104R *TACI* mutation. IgA deficiency. IgG subclass deficiency.

Palabras clave: Inmunodeficiencia común variable. Mutación C104R en *TACI*. Deficiencia de IgA. Deficiencia de subclases de IgG.

The *TACI* gene (*TNFRSF13B*, OMIM ID 604907) is a member of the tumor necrosis factor receptor family that is expressed in B cells and mediates switching to IgA and IgG in response to its ligands, BAFF and APRIL. *TACI* mutations have previously been associated with common variable immunodeficiency (CVID) [1], a primary immunodeficiency characterized by hypogammaglobulinemia and the inability to mount specific antibody responses. More than 20 *TACI* mutations have been identified in CVID, the most common being C104R (about 5% of cases) followed by A181E [2]. The C104R mutation is located in cysteine-rich domain-2 in the extracellular ligand-binding domain, and previous studies suggest an autosomal dominant inheritance pattern with heterozygous cells showing a negative dominant effect by the formation of mixed mutant-wild type heterotrimers [3]. In CVID, C104R shows variable expressivity and incomplete penetrance [4]. It has also been described in IgA deficiency, although the frequency was not statistically significant. Since some cases of IgA deficiency can evolve to CVID, it is possible that they have a common origin with CVID [2]. On the other hand, no relationship has been established between *TACI* mutations and IgG subclass deficiency [5]. The molecular basis of this disease could reside in the alteration of the switching process, although the molecular mechanism implied has not been elucidated to date. Deletions of 1 or more of the 9 genes in the IGHC locus have been reported, but in most cases they are related to an alteration in the expression of the γ genes. Thus, mutations in the cis-regulatory elements at the *IGHC* locus and alterations in the synthesis of cytokines such as IFN- γ , IL-4, and TGF- β have been considered to affect Ig class switching.

In order to verify the association between *TACI* and CVID and to investigate the possible association between *TACI* and IgG subclass deficiency, we studied the presence of the C104R mutation in a cohort of Spanish patients from our institution. The CVID subgroup included 107 patients with a mean age of 41.8 (5-73) years who fulfilled the criteria of the European Society for Immunodeficiencies. The IgA deficiency subgroup included 52 patients with a mean age of 29.2 (4-72) years and serum IgA <10 mg/dL; the IgG subclass deficiency subgroup comprised 87 patients with a mean age of 53.4 (7-83) years and less than 2 standard deviations below the mean in any of the IgG subclass serum levels. A total of 156 healthy donors were included. The parameters evaluated in all cases were Ig and IgG subclass serum levels, specific antibodies to pneumococcal 23-valent vaccine and *Haemophilus influenzae*-conjugated vaccine, and lymphocyte subpopulations and B lymphocyte subsets evaluated using flow cytometry. Expression of *TACI* in B lymphocytes was analyzed using flow cytometry with PE-conjugated antihuman *TACI* (BD Pharmingen). CVID patients were classified according to the EuroClass classification. The *TACI* g.28216T>C (c.310T>C) position was genotyped in whole blood genomic DNA with a commercially available TaqMan assay for the polymorphism rs34557412 (Life Technologies).

TACI c.310T>C genotyping (Table) revealed that the mutated allele was significantly more common in patients with CVID and IgG subclass deficiency than in healthy controls. The percentage of CVID patients with at least 1 mutated allele in C104 was 4.67%. A mean value of 4.2% has been reported elsewhere [6]. Interestingly, 3.5% of patients with IgG subclass deficiency had 1 mutated allele. We also found 1 patient with the C104R mutation in the IgA-deficient cohort (1.9%), although the frequency was not statistically significant. We were unable to find specific clinical or immunological features in these patients; however, CD267 (*TACI*) seemed to be less frequently expressed in the patient with a homozygous *TACI* mutation than in heterozygous and nonmutated cases, as reported elsewhere [7].

Therefore, we report that 3 patients with IgG subclass deficiency can harbor the C104R *TACI* mutation. The 3 patients were referred from the pulmonology department with repetitive respiratory infections. Careful follow-up of these patients for possible progress to CVID was recommended. *TACI* mutations other than C104R were reported in 7 cases of IgG subclass deficiency [5], although no association studies have been published to date. We report the first finding of this mutation

Table. Statistical Analysis of *TACI* c.310T>C Genotyping in the Study Cohort: CVID, IgA Deficiency, and IgG Subclass Deficiency

<i>TACI</i> Genotypes at c.310T>C	Disease			
	CVID	IgA Deficiency	IgG Subclass Deficiency	Healthy Controls
CC	1/107	0/52	0/87	0/156
CT	4/107	1/52	3/87	0/156
TT	102/107	51/52	84/87	156/156
	<i>P</i> =.024	NS	<i>P</i> =.020	

Abbreviations: CVID, common variable immunodeficiency; NS, nonsignificant

in association with CVID. The molecular mechanism for this association could be the implication of *TACI* in cellular signaling that results in the activation of the switching mechanism through stimulation of MyD88, TLR7, and TLR9 [8].

Only 1 of the IgA-deficient patients had the C104R mutation. This frequency was not statistically significant, as reported elsewhere [9]. The patient was a 7-year-old child with recurrent upper respiratory tract infections and poor response to treatment with antibiotics. IgG and IgM concentrations were normal, with good response to vaccines. Given that IgA deficiency can progress to CVID [10], as occurs with IgG deficiency, immunological follow-up of this patient would be recommended.

In conclusion, we recommend that the study of the C104R *TACI* mutation should be extended to patients with IgG subclass deficiency.

References

- Salzer U, Chapel HM, Webster AD, Pan-Hammarstrom Q, Schmitt-Graeff A, Schlesier M, Peter HH, Rockstroh JK, Schneider P, Schäffer AA, Hammarström L, Grimbacher B. Mutations in TNFRSF13B encoding TACI are associated with common variable immunodeficiency in humans. *Nat Genet.* 2005;37:820-8.
- Pan-Hammarstrom Q, Salzer U, Du L, Bjorkander J, Cunningham-Rundles C, Nelson DL, Bacchelli C, Gaspar HB, Offer S, Behrens TW, Grimbacher B, Hammarström L. Reexamining the role of TACI coding variants in common variable immunodeficiency and selective IgA deficiency. *Nat Genet.* 2007;39:429-30.
- Garibyan L, Lobito AA, Siegel RM, Call ME, Wucherpfennig KW, Geha RS. Dominant-negative effect of the heterozygous C104R TACI mutation in common variable immunodeficiency (CVID). *J Clin Invest.* 2007;117:1550-7.
- Martinez-Gallo M, Radigan L, Almejun MB, Martinez-Pomar N, Matamoros N, Cunningham-Rundles C. TACI mutations and impaired B-cell function in subjects with CVID and healthy heterozygotes. *J Allergy Clin Immunol.* 2013;131:468-76.
- Speletas M, Mamara A, Papadopoulou-Alataki E, Iordanakis G, Liadaki K, Bardaka F, Kanariou M, Germeris A. TNFRSF13B/TACI alterations in Greek patients with antibody deficiencies. *J Clin Immunol.* 2011;31:550-9.
- Freiberger T, Ravcukova B, Grodecka L, Pikulova Z, Stikarovska D, Pesak S, Kuklínek P, Jarkovský J, Salzer U, Litzman J. Sequence variants of the TNFRSF13B gene in Czech CVID and IgAD patients in the context of other populations. *Hum Immunol.* 2012;73:1147-54.
- Fried AJ, Rauter I, Dillon SR, Jabara HH, Geha RS. Functional analysis of transmembrane activator and calcium-modulating cyclophilin ligand interactor (TACI) mutations associated with common variable immunodeficiency. *J Allergy Clin Immunol.* 2011;128:226-8.
- Romberg N, Chamberlain N, Saadoun D, Gentile M, Kinnunen T, Ng YS, Virdee M, Menard L, Cantaert T, Morbach H, Rachid R, Martinez-Pomar N, Matamoros N, Geha R, Grimbacher B, Cerutti A, Cunningham-Rundles C, Meffre E. CVID-associated TACI mutations affect autoreactive B cell selection and activation. *J Clin Invest.* 2013;123:4283-93.
- Lopez-Mejias R, del Pozo N, Fernandez-Arquero M, Ferreira A, Garcia-Rodriguez MC, de la Concha EG, Urcelay E, Martínez A, Núñez C. Role of polymorphisms in the TNFRSF13B (TACI) gene in Spanish patients with immunoglobulin A deficiency. *Tissue Antigens.* 2009;74:42-5.
- Castigli E, Wilson S, Garibyan L, Rachid R, Bonilla F, Schneider L, Morra M, Curran J, Geha R. Reexamining the role of TACI coding variants in common variable immunodeficiency and selective IgA deficiency. *Nat Genet.* 2007;39:430-1.

■ Manuscript received December 3, 2014; accepted for publication March 10, 2015.

José Manuel Lucena

E-mail: josem.lucena.sspa@juntadeandalucia.es

Allergic Bronchopulmonary Aspergillosis Associated With Eosinophilic Gastroenteritis

Bumbacea RS¹, Balea MI², Ghiordanescu IM¹, Popp C³, Bumbacea D⁴
¹Allergology, Elias Emergency University Hospital & University of Medicine and Pharmacy Carol Davila, Bucharest, Romania
²Pneumology, Colentina Clinical Hospital, Bucharest, Romania
³Pathology, Colentina Clinical Hospital, Bucharest, Romania
⁴Pneumology, Elias Emergency University Hospital & University of Medicine and Pharmacy Carol Davila, Bucharest, Romania

Key words: Allergic bronchopulmonary aspergillosis. Eosinophilia. Eosinophilic gastroenteritis.

Palabras clave: Aspergilosis broncopulmonar alérgica. Eosinofilia. Gastroenteritis eosinofílica.

Allergic bronchopulmonary aspergillosis (ABPA) is a rare disease that may be associated with marked peripheral blood eosinophilia [1]; however, eosinophilic infiltration of organs other than the lung is unusual. We present a case of ABPA associated with eosinophilic gastroenteritis (EGE) that complicated the differential diagnosis.

A 66-year-old nonsmoking woman with no significant occupational exposure, recent travel history, or drug history (except asthma medication) was admitted to our service with breathlessness, wheezing, and a 2-month history of recurrent fever (up to 40°C), weight loss (10 kg), progressive weakness, and dysphonia. She had a 2-year history of chronic nonbloody diarrhea and a 9-year history of chronic rhinosinusitis and asthma, with severe uncontrolled asthma in the last 5 years accompanied by severe airflow limitation (forced expiratory volume in 1 second [FEV₁], 0.6 L, 28% predicted) and persistent hyper eosinophilia (>1500/μL on more than 2 occasions) despite continuous treatment with salmeterol/fluticasone 50/500 bid and several short courses of oral corticosteroids every year. Clinical examination revealed that the patient was underweight (BMI, 16.8 kg/m²) with normal vital signs, prolonged expiration, and diffuse wheezes; the remainder of the clinical examination, including the neurological exam, was normal, and no enlarged lymph nodes or hepatosplenomegaly were present.

A laboratory workup disclosed blood hyper eosinophilia (5531/μL), mild thrombocytosis (542 000/μL), increased serum C-reactive protein (32.3 mg/L), and a mild increase in serum lactate dehydrogenase (400 IU/L). Findings for serum creatinine and urinalysis were normal. The results of HIV serology, *Toxoplasma* IgM and IgG, *Toxocara canis* and *Toxocara cati* IgG, *Trichinella spiralis* IgG, and a copro-parasitological examination (Lugol, Kato-Miura concentration method, serum, *Strongyloides*) were negative. Total serum IgE was 2750 IU/mL (normal, <100 IU/mL) and *Aspergillus fumigatus* specific IgE was 10.7 kU_A/L (upper limit of normal, 0.35 kU_A/L), with high levels of *A. fumigatus* precipitins but negative recombinant *A. fumigatus*-specific IgE (rAsp f 4 and rAsp f 6). The results of testing for antinuclear

antibodies and antineutrophilic cytoplasmic antibodies were negative, as were the results of the peripheral blood genetic analysis for the *FIP1L1-PDGFRα* mutation. We chose not to perform skin prick testing for *A. fumigatus* because of the severe airflow limitation.

Spirometry revealed a severe obstructive ventilatory pattern (FEV₁, 0.54 L; 26% predicted, FEV₁/forced vital capacity [FVC], 0.63), and ECG revealed major right bundle block (previously known) with no other significant abnormalities. Computed tomography of the chest revealed central bronchiectasis, tree-in-bud opacities, and peribronchial fibrosis. Abdominal ultrasound revealed mild ascites and intestinal wall edema; cardiac ultrasound revealed mildly altered left ventricular diastolic function with no other abnormalities.

Upper gastrointestinal endoscopy and colonoscopy showed patchy erythema in the stomach, duodenum, and colon. Biopsy specimens were taken at several levels. Histopathology revealed an increased eosinophil count (>30 per high-power field) in the lamina propria of the stomach and colon, with marked degranulation (Figure). Prominent nodular infiltrates of eosinophils were observed in the deep lamina propria and muscularis mucosae, although necrosis, fibrin deposition, and granuloma were not recorded.

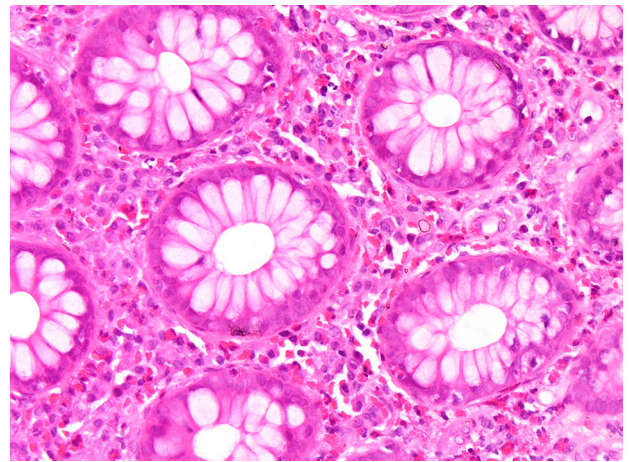


Figure. High-power view of colonic mucosa showing numerous eosinophils with increased degranulation in the lamina propria (hematoxylin-eosin, original magnification ×400).

We classified this case as ABPA based on the presence of 6 out of 8 major classic criteria: asthma, central bronchiectasis, peripheral blood eosinophilia, increased total serum IgE, serum precipitating antibodies, and *A. fumigatus*-specific serum IgE [1]. The case would also fulfill more recently proposed criteria for ABPA [2]; in addition, ABPA was associated with biopsy-proven EGE. Treatment with methylprednisolone at a starting dose of 32 mg/d for 1 month followed by gradual tapering over 6 months resulted in a significant improvement with complete remission of asthma symptoms, normal stool, weight gain of 14 kg, and marked improvement in lung function (FEV₁, 1.62 L; 78% predicted). In the following 6 months, 2 attempts at stopping oral corticosteroids resulted in asthma exacerbations with eosinophilia but no recurrent diarrhea after 2 to 3 weeks. Administration of itraconazole

400 mg/d for 3 days followed by 200 mg/d for 5 months made it possible to stop oral corticosteroids after 3 months, with no subsequent asthma exacerbation.

To our knowledge, the association between EGE and ABPA has not been previously described. The presence of marked peripheral blood eosinophilia, together with eosinophilic gastrointestinal infiltration, imposed a differential diagnosis including eosinophilic granulomatosis with polyangiitis (EGPA, previously known as Churg Strauss syndrome) and hypereosinophilic syndrome (HES). A diagnosis of EGPA would be supported by the presence of chronic rhinosinus involvement and associated gastrointestinal eosinophilic infiltration but refuted by the absence of pulmonary infiltrates on lung images, absence of granuloma or necrosis in histopathology, negative antineutrophil cytoplasmic antibody concentrations, and absence of renal or neurologic involvement [3]. A diagnosis of HES would be supported by persistent hypereosinophilia; however, myeloproliferative HES is refuted by the absence of hepatosplenomegaly, the *FIP1L1-PDGFR*A mutation, and other laboratory abnormalities, and lymphocytic HES is refuted by the presence of a well-defined allergic mechanism [4]. In fact, both HES and EGPA are rendered less likely by the evidence of *Aspergillus*-related disease (specific IgE and precipitins) in immunological tests.

Several lines of evidence support the role of *Aspergillus*—and of aeroallergens in general—in the pathogenesis of EGE. Inhalation of *A fumigatus* led to eosinophilic esophagitis (and to a lesser degree gastritis) associated with eosinophilic lung infiltration in mice [5]. This effect was not obtained by oral or intragastric administration of the same allergen and was attenuated in the absence of eotaxin or IL-5, suggesting a T_H2 -dependent response. Second, peripheral blood mononuclear cells from patients with eosinophilic esophagitis produced significantly more IL-5 after exposure to *A fumigatus* than those from healthy controls [6]. At the same time, the prevalence of allergen-specific IgE is more frequent in patients with EGE than in healthy controls, most notably for aeroallergens, including *Aspergillus*-specific IgE [7]. Finally, aeroallergen-induced eosinophilic esophagitis has been described in an adult [8]. Taken together, these data support the hypothesis that an *Aspergillus*-induced T_H2 response might be responsible for eosinophilic infiltration of the gastrointestinal wall, which might also be the case in the present report. Although the underlying mechanism of EGE could be swallowed aeroallergens, as recently suggested [9], the existence of peripheral blood *Aspergillus*-specific T cells and the coexistence of respiratory disease suggest systemic pathogenesis with involvement of homing receptors in gastrointestinal mucosa.

In conclusion, we report the first case of ABPA associated with EGE and hypothesize that an *Aspergillus*-related T_H2 response is responsible for both diseases.

Funding

The authors declare that no funding was received for the present study.

Conflicts of Interest

The authors declare that they have no conflicts of interest.

Previous Presentation

This case report was presented in a previous version at a PneumoCaz meeting in Bucharest, Romania on May 15, 2014.

References

1. Rosenberg PA, Patterson R, Mintzer R, Cooper BJ, Roberts M, Harris KE. Clinical and immunologic criteria for the diagnosis of allergic bronchopulmonary aspergillosis. *Ann Intern Med.* 1977 Apr;86(4):405-14.
2. Agarwal R, Chakrabarti A, Shah A, Gupta D, Meis JF, Guleria R, Moss R, Denning DW, ABPA complicating asthma ISHAM working group. Allergic bronchopulmonary aspergillosis: review of literature and proposal of new diagnostic and classification criteria. *Clin Exp Allergy.* 2013 Aug;43(8):850-73.
3. Vaglio A, Buzio C, Zwerina J. Eosinophilic granulomatosis with polyangiitis (Churg-Strauss): state of the art. *Allergy.* 2013 Mar;68(3):261-73.
4. Simon H-U, Rothenberg ME, Bochner BS, Weller PF, Wardlaw AJ, Wechsler ME, Rosenwasser LJ, Roufosse F, Gleich GJ, Klion AD. Refining the definition of hypereosinophilic syndrome. *J Allergy Clin Immunol.* 2010 Jul;126(1):45-9.
5. Mishra A, Hogan SP, Brandt EB, Rothenberg ME. An etiological role for aeroallergens and eosinophils in experimental esophagitis. *J Clin Invest.* 2001 Jan;107(1):83-90.
6. Yamazaki K, Murray JA, Arora AS, Alexander JA, Smyrk TC, Butterfield JH, Kita H. Allergen-specific in vitro cytokine production in adult patients with eosinophilic esophagitis. *Dig Dis Sci.* 2006 Nov;51(11):1934-41.
7. Ishimura N, Furuta K, Sato S, Ishihara S, Kinoshita Y. Limited role of allergy testing in patients with eosinophilic gastrointestinal disorders. *J Gastroenterol Hepatol.* 2013 Aug;28(8):1306-13.
8. Fogg MI, Ruchelli E, Spergel JM. Pollen and eosinophilic esophagitis. *J Allergy Clin. Immunol.* 2003 Oct;112(4):796-7.
9. Prussin C. Eosinophilic gastroenteritis and related eosinophilic disorders. *Gastroenterol Clin North Am.* 2014 Jun;43(2):317-27.

■ Manuscript received November 24, 2014; accepted for publication March 17, 2015.

Dragos Bumbacea

Department of Pneumology
Elias Emergency University Hospital & University of Medicine
and Pharmacy Carol Davila
17 Marasti Blvd, 011461 Bucharest, Romania
E-mail: d.bumbacea@gmail.com

Nitrite/Nitrate in Nasal Lavage Fluid Reflects Nasal Symptoms After a Single Nasal Allergen Provocation in Patients With Seasonal Allergic Rhinitis

Imoto Y¹, Yamada T¹, Tsukahara H², Kimura Y¹, Kato Y¹, Sakashita M¹, Fujieda S¹

¹Department of Otorhinolaryngology Head & Neck Surgery, Faculty of Medical, Sciences, University of Fukui, Fukui, Japan

²Department of Pediatrics, Okayama University Graduate School of Medicine, Dentistry, and Pharmaceutical Sciences, Okayama, Japan

Key words: Nitrite/nitrate. Nasal symptoms. Nasal lavage.

Palabras clave: Nitrito/nitrato. Síntomas nasales. Lavado nasal.

Seasonal allergic rhinitis by Japanese cedar pollen (SAR-JCP) is the most common allergic disease in Japan. We recently reported JCP to be the most common allergen in allergic rhinitis [1]. Alteration of the flux of free radicals from infiltrated cells can considerably affect the pathophysiology of allergic disease [2]. In this study, we investigated the involvement of local and systemic nitric oxide (NO) production in patients with SAR-JCP. Serum, urine, and nasal lavage fluid were obtained from patients with SAR-JCP before and after nasal provocation with JCP. We examined a marker of endogenous NO production, total nitrite plus nitrate (nitrite/nitrate, NO_x-), a product of NO that reflects airway inflammation.

The study population comprised 41 Japanese volunteers: 21 participants (12 men and 9 women, mean age 24.9 [0.6] years) with SAR-JCP and 20 participants (11 men and 9 women; mean age, 24.2 [1.5] years) with no allergic sensitization or history of allergic rhinitis, who comprised the control group. JCP-specific IgE in serum was measured using the ImmunoCAP method (Pharmacia Diagnostics AB). The specific IgE of JCP in the SAR-JCP group was 16.1 (14.3) IU/mL, whereas that of the control group was <0.3 IU/mL.

Natural JCP was collected and stored at -20°C before use. We placed 1 µg of JCP on the surface of both nasal cavities and maintained it in the inferior turbinate.

Urine and serum were collected before and 8 hours after nasal allergen exposure outside the JCP season. After centrifugation for 10 minutes at 400g, the supernatants of urine and serum were stored at -20°C until quantification.

Nasal lavage fluid was collected before and after allergen provocation. Details of the methods used for nasal lavage were described elsewhere [3]. For the present study, we injected 20 mL of saline into the nasal cavity. After centrifugation for 10 minutes, 400g, the supernatants of lavage fluid were stored at -20°C until quantification.

The NO_x- concentrations were measured in duplicate using the Griess method (Nitrate/Nitrite Colorimetric Assay Kit, Cayman Chemical) [4]. The concentrations of NO_x- in urine were corrected for the concentration of urine creatine. The NO_x- concentrations in nasal lavage fluid were also

corrected for the ratio of nasal lavage volume to 20 mL of saline. NO_x- in serum was measured using the same procedure without correction.

Nasal symptoms were recorded for all 21 participants before and after the nasal allergen provocation test based on the Japanese Guideline for Allergic Rhinitis [5].

All participants gave their written informed consent to participate in the study, which was approved by the Ethics Committee of the University of Fukui, Japan.

Data are expressed as mean (SD). The significance of the changes in markers was compared between the 2 groups using the Wilcoxon signed rank test and the Mann-Whitney test.

All nasal symptom scores were markedly elevated after nasal challenge with JCP in SAR-JCP patients (sneezing, 0.1 [0.2] to 1.4 [1.1]; nasal blowing, 0.3 [0.5] to 1.9 [1.0]; nasal itch, 0.1 [0.2] to 1.4 [1.1]; and nasal congestion, 0.2 [0.5] to 1.5 [1.1]). The total nasal symptom score was 0.5 (0.8) to 6.3 (3.5). As for the SAR-JCP group, the NO_x- concentrations in nasal lavage fluid after provocation were significantly higher than before provocation (7.3 [4.1] to 13.7 [7.9], *P*<.05), which were also higher than that of the control group (*P*<.05).

The Figure presents the correlation between nasal symptoms and the NO_x- concentration after nasal provocation. NO_x- concentrations in nasal lavage fluid correlated strongly with all nasal symptom scores, as follows: sneezing, *R*²=0.437, *P*<.001; nasal blowing, *R*²=0.286, *P*<.01; nasal itch, *R*²=0.396, *P*<.001; nasal congestion, *R*²=0.334, *P*<.001; total nasal symptom score, *R*²=0.441, *P*<.001.

We measured NO_x- in urine, serum, and nasal lavage fluid as a noninvasive monitor of allergic inflammation. The results showed a significant positive correlation between nasal symptoms and NO_x- concentrations.

In the human airway, the most readily detectable NO oxidation products include nitrite (NO₂-) and nitrate (NO₃-), which can be derived from NO through a series of reactions involving superoxide anion and oxygen [6]. The generation of NO oxidation products is important for transcription factor activation and for the regulation of airway inflammation [7]. NO_x- concentrations were higher in the SAR group than in controls during the pollen season [8]. Repeated exposure of patients with SAR to pollen induced an increase in NO_x- concentrations and kept them elevated for several weeks. Although the stimulation was administered only once, we observed a marked increase in NO_x- in nasal lavage from patients with SAR in this study. Our results suggest that the nasal mucosa of patients with SAR-JCP was antigen-sensitive because only a single provocation test caused nasal symptoms with an increase in NO_x-. Measuring redox markers directly from inflammatory lesions shows effects more sharply than from other tissues or organs [9]. Our data showed that the concentration of NO_x- in nasal lavage fluid reflected nasal symptoms more sharply than in serum or urine. We consider nasal NO_x- an ideal marker of allergic rhinitis.

We measured NO_x- before and after allergen provocation by placing JCP directly onto the surface of the inferior turbinates. Our results showed that the NO_x- concentration in the nasal lavage fluid of SAR-JCP patients increased significantly after provocation and correlated with nasal

symptoms. These results demonstrate that NO_x⁻ in nasal lavage fluid might be a candidate biomarker of nasal allergic inflammation.

Acknowledgments

We are grateful to the patients and their parents for agreeing to participate in this study.

Funding

The study was supported by Grants-in-Aid for Young Scientists (B) from the Japan Society for the Promotion of Science (26861362), Grants-in-Aid for Scientific Research from the Japanese Ministry of Health, Labour and Welfare (H26-Immunology-general-003), and the Japanese Ministry of Education, Culture, Sports, Science and Technology (26293368).

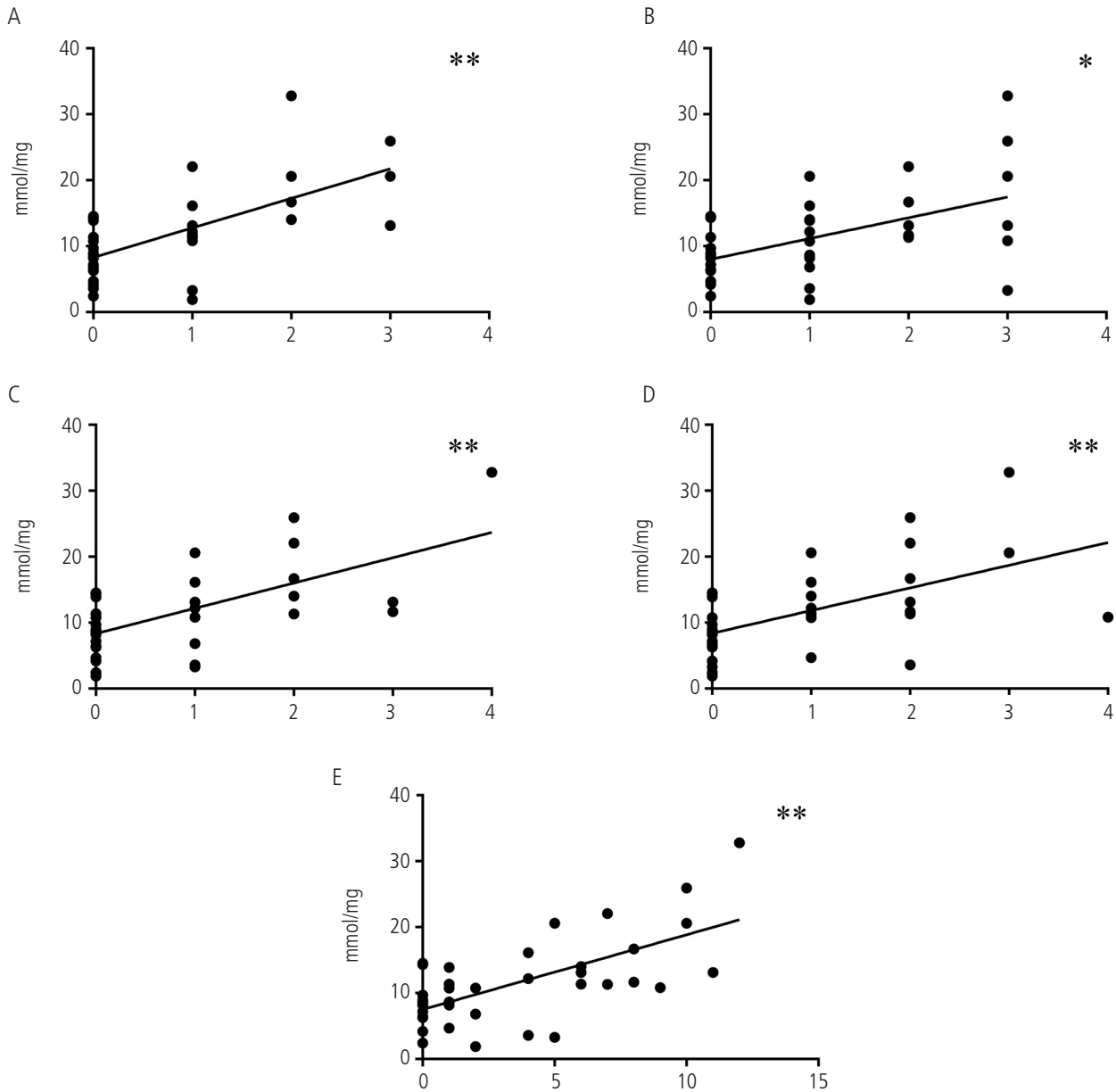


Figure. Correlations between the concentrations of NO_x⁻ in nasal lavage and respective nasal symptom scores: A, sneezing; B, nasal blowing; C, nasal itch; D, nasal congestion; E, total nasal symptom score. * $P < .01$, ** $P < .001$

Conflicts of Interest

The authors declare that they have no conflicts of interest.

References

1. Sakashita M, Hirota T, Harada M, Nakamichi R, Tsunoda T, Osawa Y, Kojima A, Okamoto M, Suzuki D, Kubo S, Imoto Y, Nakamura Y, Tamari M, Fujieda S. Prevalence of Allergic Rhinitis and Sensitization to Common Aeroallergens in a Japanese Population. *Int Arch Allergy Immunol*. 2009;151:255-61.
2. Tsukahara H, Shibata R, Ohshima Y, Todoroki Y, Sato S, Ohta N, Hiraoka M, Yoshida A, Nishima S, Mayumi M. Oxidative stress and altered antioxidant defenses in children with acute exacerbation of atopic dermatitis. *Life Sci*. 2003;72:2509-16.
3. Fujieda S, Diaz-Sanchez D, Saxon A. Combined nasal challenge with diesel exhaust particles and allergen induces *In vivo* IgE isotype switching. *Am J Respir Cell Mol Biol*. 1998;19:507-12.
4. Green LC, Wagner DA, Glogowski J, Skipper PL, Wishnok JS, Tannenbaum SR. Analysis of nitrate, nitrite, and [15N]nitrate in biological fluids. *Anal Biochem*. 1982;126:131-8.
5. Fujieda S, Kurono Y, Okubo K, Ichimura K, Enomoto T, Kawauchi H, Masuyama K, Goto M, Suzaki H, Okamoto Y, Takenaka H. Examination, Diagnosis and Classification for Japanese Allergic Rhinitis: Japanese Guideline. *Auris Nasus Larynx*. 2012;39:553-6.
6. Fitzpatrick AM, Brown LA, Holguin F, Teague WG. Levels of nitric oxide oxidation products are increased in the epithelial lining fluid of children with persistent asthma. *J Allergy Clin Immunol*. 2009;124:990-6.
7. Andreadis AA, Hazen SL, Comhair SA, Erzurum SC. Oxidative and nitrosative events in asthma. *Free Rad Biol Med*. 2003;35:213-25.
8. Gratziau C, Rovina N, Makris M, Simoes DC, Papapetropoulos A, Roussos C. Breath markers of oxidative stress and airway inflammation in Seasonal Allergic Rhinitis. *Int J Immunopathol Pharmacol*. 2008;21:949-57.
9. Tsukahara H. Biomarkers for oxidative stress: clinical application in pediatric medicine. *Curr Med Chem*. 2007;14:339-51.

■ *Manuscript received March 19, 2015; accepted for publication April 24, 2015.*

Yoshimasa Imoto

Otorhinolaryngology Head & Neck Surgery
 Department of Sensory and Locomotor Medicine
 Faculty of Medical Science
 University of Fukui
 23 Shimoaizuki, Matsuoka, Yoshida,
 Fukui, 910-1193, Japan
 E-mail: yimoto@u-fukui.ac.jp