

A Delayed Reaction to Oxaliplatin

M-S Masse, D Caimmi, P Demoly
Allergy Department and INSERM U657, Hôpital Arnaud de Villeneuve, University Hospital of Montpellier, Montpellier, France

Key words: Delayed reaction. Hypersensitivity. Oxaliplatin. Platinum salts. Skin tests.

Palabras clave: Reacción tardía. Hipersensibilidad. Oxaliplatino. Sales de platino. Pruebas cutáneas.

A 64-year-old man who was receiving chemotherapy for gastric cancer with liver metastases was referred to our department for an allergy workup after experiencing a skin reaction. The chemotherapy regimen comprised taxotere, oxaliplatin, and 5-fluorouracil (5-FU) (combined with calcium folinate) followed by abundant intravenous hydration. Each cycle was administered in combination with a standard preparation containing ondansetron and methylprednisolone succinate. The patient experienced no problems during the first 6 cycles of treatment. However, approximately 8 hours after the beginning of the seventh cycle, he developed a pruritic polymorphous maculopapular rash, mainly on the upper and lower limbs. No associated systemic manifestations were observed. Antihistamines and corticosteroids were administered immediately, and the rash resolved within 72 hours. The same reaction occurred 2 weeks after this episode, while the patient was receiving his eighth cycle of chemotherapy.

Table. Concentrations Used During the Skin Tests Performed on Our Patient

Drug	Concentration for SPT	Concentration for IDT
Carboplatin	10 mg/mL	1 mg/mL
Cisplatin	1 mg/mL	0.1 mg/mL
Oxaliplatin	5 mg/mL	0.5 mg/mL
Docetaxel	10 mg/mL	1 mg/mL
5-Fluorouracil	10 mg/mL	10 mg/mL
Calcium folinate	50 mg/mL	0.5 mg/mL
Methylprednisolone succinate	10 mg/mL	1 mg/mL
Ondansetron	2 mg/mL	0.02 mg/mL

Abbreviations: IDT, intradermal test; SPT, skin prick test.

Following these 2 reactions, the patient was referred to our clinic, where we performed skin tests. Our evaluation included skin prick tests followed by intradermal tests with all of the drugs he had received, namely, docetaxel, oxaliplatin, carboplatin, cisplatin, 5-FU, calcium folinate, methylprednisolone succinate, and ondansetron. The concentrations used are shown in the Table. All of the skin tests were negative at the immediate reading. However, about 12 hours later, they became positive for oxaliplatin and docetaxel. During the following 2 days, positive results were also observed for carboplatin and cisplatin.

Two months after our tests, the cancer progressed with peritoneal and lymph node involvement, and the patient required a further course of chemotherapy. The newly prescribed regimen was FOLFOX (5-FU and oxaliplatin). The drugs were administered in combination with corticosteroids. Four hours after the beginning of the treatment, the patient began to experience cutaneous pruritus, mainly on the forearm on which we had recently performed our skin tests. During the night, the rash spread in the same way as the previous rashes. Since the FOLFOX regimen does not contain docetaxel, we conclude that the reaction was induced by oxaliplatin.

Platinum salt reactions are generally described as immediate-type reactions (type I), thus requiring skin tests to be performed, and more rarely as hypersensitivity reactions secondary to direct release of mediators (cytokines) [1]. Type II reactions (thrombocytopenia and hemolytic anemia) have also been reported [2]. However, no delayed-type reactions (type IV) to these agents have been reported to date.

Leguy-Seguín et al [3] report on 7 patients with delayed-type reactions to platinum salts. Nevertheless, none of these patients presented delayed positive skin test results. To our knowledge, no authors have reported patients with a history of delayed reaction to platinum salts, in whom skin tests demonstrated the role of the drug. Diagnosis has never been confirmed in any of these patients after reintroduction of the agent. In our case, corticosteroids were not powerful enough to prevent the reaction, and the oncologists finally decided to discontinue platinum salts.

The present case highlights the importance of a complete allergy workup in both immediate-type and delayed-type reactions. Investigations should include all the drugs a patient has received, even those that seem less likely to have caused the reaction.

References

- Santini D, Tonini G, Salerno A, Vincenzi B, Patti G, Battistoni F, Dicuonzo G, Labianca R. Idiosyncratic reaction after oxaliplatin infusion. *Ann Oncol.* 2001;12:132-3.
- Polyzos A, Tsavaris N, Gogas H, Souglakos J, Vambakas L,

Vardakas N, Polyzos K, Tsigris C, Mantas D, Papachristodoulou A, Nikiteas N, Karavokyros JG, Felekouras E, Griniatsos J, Giannopoulos A, Kouraklis G. Clinical features of hypersensitivity reactions to oxaliplatin: a 10-year experience. *Oncology*. 2009;76:36-41.

3. Leguy-Seguín V, Jolimoy G, Coudert B, Pernot C, Dalac S, Vabres P, Collet E. Diagnostic and predictive value of skin testing in platinum salt hypersensitivity. *J Allergy Clin Immunol*. 2007;119:726-30.

■ Manuscript received December 7, 2011; accepted for publication January 19, 2012.

Pascal Demoly

Head of the Allergy Department
Hôpital Arnaud de Villeneuve
University Hospital of Montpellier
Montpellier, France
E-mail: pascal.demoly@inserm.fr

Urticaria Due to an Intradermal Test With Articaïne Hydrochloride

G Davila-Fernández,¹ L Sánchez-Morillas,² P Rojas,² JJ Laguna²

¹Allergy Department, Hospital Universitario del Henares, Coslada, Spain

²Allergy Department, Hospital Central de La Cruz Roja, Madrid, Spain

Key words: Articaïne. Amide local anesthetics. Cross-reactivity. Urticaria. Intradermal test.

Palabras clave: Articaína. Anestésico local grupo amida. Reactividad cruzada. Urticaria. Test intradérmico.

Articaïne hydrochloride belongs to the amino amide anesthetic group. Although one of the most widely used anesthetics in dental procedures, it has rarely caused systemic allergic reactions [1-5].

A 26-year-old woman with no history of atopy received subcutaneous 4% articaïne with 0.5% epinephrine for a dental procedure. Twenty minutes after injection, she developed generalized urticaria and dysphagia. The symptoms were treated with parenteral antihistamines and corticosteroids and resolved completely.

The allergy workup was as follows: prick test with latex; prick and intradermal tests with undiluted 1% lidocaine, 1% mepivacaine, and 0.5% bupivacaine; prick (undiluted) and intradermal test (1:100, 1:10) with 4% articaïne; and patch testing with 1% lidocaine, 1% mepivacaine, 0.5% bupivacaine, and 4% articaïne in saline solution. Ten nonatopic and 10 atopic individuals were also tested as controls. Single-blind placebo-controlled tests with epinephrine and alternative local anesthetic agents (lidocaine, mepivacaine, and bupivacaine) were performed to evaluate possible cross-reactivity.

Negative results were recorded for the prick and intradermal tests with lidocaine, mepivacaine, and bupivacaine and for the prick test with articaïne and latex. The concentrations used for these anesthetics were shown to be nonirritant in previous studies [2,6,8].

An intradermal test with 4% articaïne (diluted 1:10) was positive. Twenty minutes after the intradermal test, the patient developed urticarial lesions on the chest and face. The prick and intradermal tests were negative in all the controls.

Patch tests with lidocaine, mepivacaine, bupivacaine, and articaïne in saline solution were negative.

We performed a single-blind placebo-controlled subcutaneous challenge test with lidocaine, mepivacaine, bupivacaine, and epinephrine, although the results were negative.

We report a case of urticaria after intradermal skin testing with articaïne. Systemic reactions with this technique have been described only occasionally, and the literature contains few cases of allergy to articaïne [1-5].

The cross-reactivity study revealed tolerance to other amide local anesthetics, as reported by other authors. Few

reports have established the degree of cross-reactivity between amide local anesthetics in immediate-type hypersensitivity reactions [1,4,6-8]. Warrington and McPhillips [4] reported cross-reactivity between prilocaine, bupivacaine, and articaine in a single patient. Our patient reacted to articaine and tolerated lidocaine, mepivacaine, and bupivacaine.

Allergy to local anesthetics has important implications for therapy; therefore, it is necessary to offer a safe alternative to patients who demonstrate tolerance to other local anesthetics.

References

1. Moreno Escobosa MC, Cruz Granados S, Moya Quesada MC, Amat López J. Urticaria due to articaine. *J Investig Allergol Clin Immunol*. 2011;21(2):155-6.
2. El-Qutob D, Morales C, Peláez A. Allergic reaction caused by articaine. *Allergol Immunopathol*. 2005 Mar-Apr;33(2):115-6.
3. Kleinhans M, Böer A, Kaufmann R, Boehncke WH. Fixed drug eruption caused by articaine. 2004 Jan;59(1):117.
4. Warrington RJ, McPhillips S. Allergic reaction to local anesthetic agents of the amide group. *J Allergy Clin Immunol*. 1997 Dec;100(6 Pt 1):855.
5. Malanin K, Kalimo K. Hypersensitivity to the local anesthetic articaine hydrochloride. *Anesth Prog*. 1995;42(3-4):144-5.
6. Prieto A, Herrero T, Rubio M, Tornero P, Baeza ML, Velloso A, Pérez C, De Barrio M. Urticaria due to mepivacaine with tolerance to lidocaine and bupivacaine. *Allergy*. 2005 Feb;60(2):261-2.
7. Cuesta-Herranz J, De las Heras M, Fernández M, Lluch M, Figueredo E, Umpiérrez A, Lahoz C. Allergic reaction caused by local anesthetic agents belonging to the amide group. *J Allergy Clin Immunol*. 1997;99:427-8.
8. González-Delgado P, Antón R, Soriano V, Zapater P, Niveiro E. Cross-reactivity among amide-type local anesthetics in a case of allergy to mepivacaine. *J Investig Allergol Clin Immunol*. 2006;16(5):311-3.

■ Manuscript received November 18, 2011; accepted for publication January 20, 2012.

Galicía Davila Fernández
Hospital Universitario del Henares
28822 Coslada, Spain
E-mail: galiciadavila@gmail.com

Specific Immunoglobulin E to *Echinococcus granulosus* in Children Allergic to Cow's Milk Proteins

MC García-Ara, I Bobolea, T Caballero, S Quirce, MT Boyano-Martínez
Department of Allergy, Hospital La Paz Institute for Health Research, IdiPAZ, Madrid, Spain

Key words: Animal dander allergy. Bovine serum albumin. Cow's milk allergy. Specific IgE to *Echinococcus*. Total serum IgE.

Palabras clave: Albúmina sérica bovina. Alergia a epitelios de animales. Alergia a las proteínas de la leche de vaca. IgE específica a *Echinococcus*. IgE sérica total.

Echinococcosis is an endemic disease in Spain. It can induce immediate hypersensitivity reactions [1], which can often be demonstrated by elevated levels of specific immunoglobulin E (sIgE) to *Echinococcus granulosus*. Therefore, the allergy workup for patients with elevated total serum IgE includes determination of sIgE to parasites, including *Echinococcus*. Moreover, many patients who are allergic to cow's milk proteins (CMP) also have positive sIgE to *Echinococcus*, even though parasitosis has been ruled out.

The aims of this cross-sectional study were as follows: first, to analyze whether positivity of sIgE to *Echinococcus* is found only in patients with allergy to CMP or also in those with other allergic disorders, such as animal dander allergy, as compared to patients with elevated total serum IgE and no allergy to CMP or animal dander; and second, to assess whether sIgE to *Echinococcus* is associated with any specific CMP in particular.

The study population comprised 51 patients (34 males, mean age 6.8 years [2-15 years]) seen consecutively in our pediatric allergy outpatient clinic. The patients were divided into 3 groups. Group 1 comprised 29 patients with CMP allergy a high level of sensitization (CAP \geq class 4 [ImmunoCAP, Phadia]), and no allergy to animal dander. Group 2 comprised 10 patients without CMP allergy who were allergic to dog dander, cat dander, or both. Group 3 comprised 12 patients with total serum IgE >1000 kU_A/L and no allergy to CMP or dander.

All patients underwent skin prick tests (SPT) with cow's milk and dog and cat dander (ALK-Abelló). Patients from Group 1 were also tested for CMP using α -lactalbumin (ALA), β -lactoglobulin (BLG), bovine serum albumin (BSA), and casein. In all patients with positive SPT results for cow's milk, we investigated sIgE to CMP (ALA, BLG, BSA, and casein), *Echinococcus*, and dog and cat dander.

A CAP inhibition study of sIgE to *Echinococcus* was conducted [2] using a serum pool from 16 patients allergic to CMP and with positive sIgE to *Echinococcus*. All patients underwent serology testing for hydatidosis; the results were negative in all cases. Patients with elevated sIgE to *Echinococcus* also underwent a complete blood count, chest X-rays, and abdominal ultrasound, all of which were normal.

Table. Specific Immunoglobulin E to *Echinococcus granulosus* in Children Allergic to Cow's Milk Proteins^a

CAP <i>Echinococcus</i>	>0.35 kU _A /L n=25	<0.35 kU _A /L n=4	
Total IgE	947 (106-2639)	221.5 (102-1873)	P=.227
Specific IgE			
Cow's milk	86.5 (15.5-101)	50.2 (26.1-101)	P=.521
α-Lactalbumin	16.2 (1.5-101)	11.98 (2.30-39.3)	P=.785
β-Lactoglobulin	12.9 (0.74-101)	2.39 (0.34-21.7)	P=.116
Casein	79.5 (7.26-101)	45.35 (19.5-101)	P=.477
BSA	4.5 (0.34-101)	0.34 (0.34-1.15)	P=.012
Dog dander	5.8 (0.87-25.4)	2.32 (1.15-11.9)	P=.109
Cat dander	1.88 (0.34-16.9)	0.34 (0.34-6.89)	P=.144
<i>Echinococcus</i>	4.56 (0.39-101)	0.34 (0.34-0.34)	

Abbreviations: BSA, bovine serum albumin; Ig, immunoglobulin.
^akU_A/L (median and range); cutoff for positivity, 0.35 kU_A/L.

sIgE to *Echinococcus* (>0.35 kU_A/L) was detected in 34 of the 51 patients (68%). The highest frequency was found in Group 1 (25/29 [86.2%]), which also had the highest sIgE levels (median, 3.75 kU_A/L [0.34->100]). sIgE to *Echinococcus* was detected in 5 out of 10 patients in Group 2 (median, 0.4 kU_A/L [0.34 to 8.35]) and in 4 out of 12 patients in Group 3 (median 0.34 kU_A/L [0.34 to 6.4]).

In Group 1, children with positive sIgE to *Echinococcus* had higher levels of sIgE to cow's milk and to all CMPs than those with negative sIgE to *Echinococcus* (Table). Nevertheless, the association reached statistical significance only with BSA (medians compared using the Mann-Whitney test). sIgE to *Echinococcus* was 87% inhibited by BSA, and sIgE to BSA was 99% inhibited by preincubation of the serum pool with BSA.

The CAP inhibition results provide evidence of IgE cross-reactivity between *E granulosus* and BSA. This may be due to contamination of the *Echinococcus* extract with BSA from the bovine host, or to BSA or other host proteins present in the hydatid cyst [3]. *Echinococcus* is a parasite with various antigens [4]. Several host proteins, including serum albumin and γ-globulin, have been detected in cyst fluid [5].

In Group 2, no association was found between IgE to dog or cat dander and IgE to *Echinococcus*. These patients were not sensitized to CMP. Other authors have shown that, although some dander allergens are serum albumins that share a high degree of homology with BSA (cat albumin [Fel d 2] and dog serum albumin [Can f 3]), patients who are allergic only to animal dander seem to recognize other major allergens, such as lipocalins (Can f 1, Can f 2, and Fel d 4) [6].

Group 3 was characterized by low frequency of sensitization to *Echinococcus* and low levels of sIgE.

In conclusion, sensitization to *Echinococcus* was found more frequently in children with allergy to CMP and was associated with sensitization to BSA. Nevertheless, sIgE to *Echinococcus* in patients with CMP allergy does not seem to be a marker of hydatidosis.

References

- Vuitton DA. Echinococcosis and allergy. Clin Rev Allergy Immunol. 2004;26:93-104.
- Pascual C, Crespo JF, San Martín MS, Ornia N, Ortega N, Caballero T, Muñoz-Pereira M, Martín-Esteban M. Cross-reactivity between IgE-binding proteins from Anisakis, German cockroach and chironomides. Allergy. 1997;52:514-20.
- Caballero T, Alonso A, De Miguel S, Martín-Esteban M, Varga B, Pascual CY, López-Serrano MC. IgE mediated anaphylaxis to Thiomucase, a mucopolysaccharidase: allergens and cross-reactivity. Allergy. 2002;57:254-7.
- Shepherd JC, McManus DP. Specific and cross-reactive antigens of *Echinococcus granulosus* hydatid cyst fluid. Mol Biochem Parasitol. 1987;25:143-54.
- Shapiro SZ, Bahr GM, Hira PR. Analysis of host components in hydatid cyst fluid and immunoblot diagnosis of human *Echinococcus granulosus* infection. Ann Trop Med Parasitol. 1992;86:503-9.
- Spitzauer S, Pandjaitan B, Soregi G, Muhl S, Ebner C, Kraft D, Valenta R, Rumpold H. IgE cross-reactivities against albumins in patients allergic to animals. J Allergy Clin Immunol. 1995;96 (6 Pt 1):951-9.

■ Manuscript received October 26, 2011; accepted for publication January 23, 2012.

Irina Bobolea

Department of Allergy
 Hospital Universitario Infantil La Paz
 Paseo La Castellana, 261
 28046 Madrid, Spain
 E-mail: irinabobolea@yahoo.com

Ibuprofen-Induced Exudative Erythema Multiforme After 1 Week of Continued Therapy Following Oral Challenge

A Alonso-Llamazares, JM Beitia-Mazuecos, R Cardenas-Contreras, A Vega-Castro, B Mateo-Borrega
Allergy Department, Hospital Universitario de Guadalajara, Guadalajara, Spain

Key words: Ibuprofen. Delayed reaction. Exudative erythema multiforme.

Palabras clave: Ibuprofeno. Reacción retardada. Eritema exudativo multiforme.

Ibuprofen is one of the most commonly prescribed nonsteroidal anti-inflammatory drugs (NSAIDs) for symptomatic relief of mild pain and fever.

The most common side effects of ibuprofen involve the gastrointestinal system. The principal clinical manifestations of allergic reactions to ibuprofen are urticaria and angioedema, although other types of hypersensitivity reaction have also been described [1-9].

Exudative erythema multiforme is a self-limiting dermatosis with characteristic skin lesions and variable mucosal involvement. In almost 50% of cases, the trigger is unknown. This condition has been associated with viral infections (eg, herpes simplex infection), drugs, connective tissue disease, and tumors. Several drugs have been associated with this reaction, especially sulfonamides, penicillins and other antibiotics, NSAIDs (diclofenac [6], ibuprofen [7-9], naproxen [7]), and allopurinol.

Cases secondary to viruses generally affect the extremities, whereas those secondary to drugs affect the trunk.

Exudative erythema multiforme takes 2 clinical forms: the minor form is the more common and usually causes mild symptoms; the major form, or Stevens-Johnson Syndrome, is more severe, with systemic symptoms and mucosal involvement.

A 32-year-old woman with no history of allergic disease was referred to the allergy department after a suspected allergic reaction to drugs. She had begun treatment with omeprazole and paracetamol 1 week earlier and presented with pruritic maculopapular lesions on the face and dorsum of the hands. She had no mucosal lesions.

The patient reported similar lesions on her arms and legs after 1 week of treatment with ibuprofen and paracetamol a year previously.

The results of skin prick tests with paracetamol (500 mg/mL), ibuprofen (400 mg/mL), and omeprazole (40 mg/mL) and intradermal tests with paracetamol (50 mg/mL) and omeprazole (4 mg/mL) were negative.

Patch testing with paracetamol (10% in petrolatum) and ibuprofen (5% in petrolatum) also yielded negative results.

Oral challenge testing with paracetamol (1000 mg), omeprazole (40 mg), and ibuprofen (1000 mg) was negative. The patient subsequently continued treatment with each drug for 1 week, after which time no reaction was observed with paracetamol or omeprazole. After 7 days of treatment with ibuprofen (600 mg every 12 hours), she developed maculopapular lesions with erythema and pruritus on the dorsum of the hands and on the elbows (Figure, A).

Histopathology of a skin biopsy from the lesions on the elbows and hands revealed the lesions to be compatible with exudative erythema multiforme (Figure, B).

Arylpropionic acid NSAIDs were prohibited. Tolerance to other NSAIDs was confirmed. The patient subsequently received treatment with etoricoxib and diclofenac for 10 days without presenting a reaction.

Oral challenge was performed with all the drugs involved, because the patient's symptoms were mild. Continuation of treatment after a negative challenge test is uncommon, and a recent review of hypersensitivity reactions to NSAIDs makes no mention of this diagnostic approach [10].

In our case, diagnosis was confirmed by continuing treatment for 1 week after a negative oral challenge test result.

We conclude that, in patients with a delayed reaction and depending on the clinical picture, it is important to continue treatment with the suspected drug to demonstrate tolerance and prevent misdiagnosis.

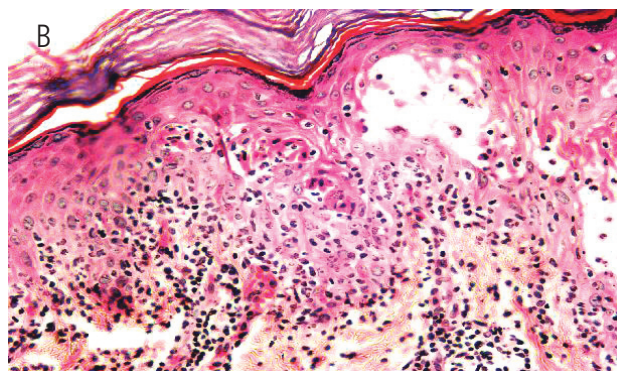
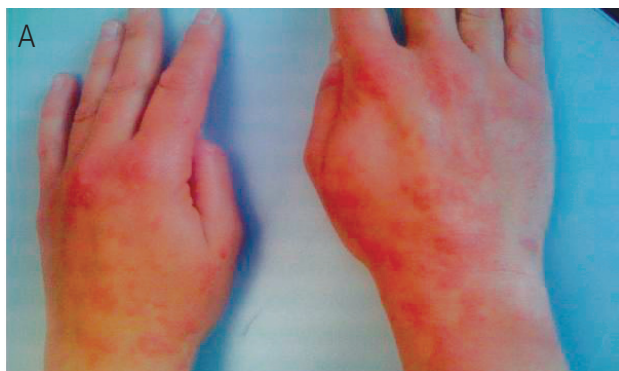

Figure. A, Lesions on the hands. B, Skin biopsy.

This case was presented as a poster at the Symposium Internacional de Alergia a Medicamentos (SEIAC) 2009, Logroño, Spain.

References

- Doña I, Blanca-López N, Cornejo-García JA, Torres MJ, Laguna JJ, Fernández J, Rosado A, Rondón C, Campo P, Agúndez JA, Blanca M, Canto G. Characteristics of subjects experiencing hypersensitivity to non-steroidal anti-inflammatory drugs: patterns of response. *Clin Exp Allergy*. 2011 Jan;41(1):86-95.
- Kumar A, Berko NS, Gothwal R, Tamarin F, Jesmajian SS. Kounis syndrome secondary to ibuprofen use. *Int J Cardiol*. 2009 Nov 12;137(3):e79-80
- Mao Martín L, Hernández Blanco C, Antolín Arias J, Cabello Carro J. Toxic epidermal necrolysis. *Med Clin (Barc)*. 2008 Sep 13;131(8):320.
- Kucharewicz I, Kemona-Chetnik I, Reduta T, Wierzwicka I, Flisiak R, Bodzenta-Lukaszyk A. Drug rash with eosinophilia and systemic symptoms after ibuprofen intake. *J Investig Allergol Clin Immunol*. 2007;17(5):347-8.
- Periard D, Mayor C, Aubert V, Spertini F. Recurrent ibuprofen-induced aseptic meningitis: evidence against an antigen-specific immune response. *Neurology*. 2006 Aug 8;67(3):539-40.
- Ludwig C, Brinkmeier T, Frosch PJ. Exudative erythema multiforme with transition to a toxic epidermal necrolysis after taking aceclofenac. *Dtsch Med Wochenschr* 2003;128 (10):487-90.
- Sotelo CN, Hurtado VJG, Rascón AA. Síndrome de Stevens-Johnson. Informe de 7 casos. *Bol Med Hosp Infant Mex* Vol. 62, enero-febrero 2005:25-32.
- Sánchez Blanco B. Síndrome de Stevens-Johnson. *Emergencias*. 2010;22:470.
- Neuman N, Nicar M. Apoptosis in ibuprofen-induced Stevens-Johnson syndrome. *Transl Res*. 2007 May;149 (5):254-9.
- Kowalski ML, Makowska JS, Blanca M, Bavbek S, Bochenek G, Bousquet J, Bousquet P, Celik G, Demoly P, Gomes ER, Nizankowska-Mogilnicka E, Romano A, Sanchez-Borges M, Sanz M, Torres MJ, De Weck A, Szczeklik A, Brockow K. Hypersensitivity to nonsteroidal anti-inflammatory drugs (NSAIDs) classification, diagnosis and management: Review of the EAACI/ENDA and GA2LEN/HANNA. *Allergy*. 2011;66 (7):818-29.

■ Manuscript received October 19, 2011; accepted for publication January 24, 2012.

Ana Alonso Llamazares
Allergy Department
Hospital Universitario de Guadalajara
C/ Donantes de sangre s/n
19002 Guadalajara, Spain
E-mail: analonlla@hotmail.com

Report From the Hymenoptera Committee of the Spanish Society of Allergology and Clinical Immunology: Immunotherapy With Bumblebee Venom

S Cruz,¹ A Vega,² S Fernández,³ L Marquès,⁴ M Baltasar,⁵ A Alonso,² G Jorro,⁶ A Moreno,⁷ L Sánchez-Morillas,⁸ A Miranda,³ V Soriano,⁹ J Fernández,⁹ R Guspi,⁵ and the members of the Hymenoptera Committee of the Spanish Society of Allergology and Clinical Immunology (SEIAC)
¹Allergy Department, Hospital Torrecárdenas, Almería, Spain
²Allergy Department, Hospital Universitario de Guadalajara, Guadalajara, Spain
³Allergy Department, Hospital Carlos Haya, Málaga, Spain
⁴Allergy Department, Hospital Santa María, Lleida, Spain
⁵Allergy Department, Hospital de Tortosa Verge de la Cinta, Institut de Investigació Sanitària Pere i Virgili, Tortosa, Spain
⁶Allergy Department, Hospital de la Rivera, Alzira, Spain
⁷Allergy Department, Hospital Nuestra Señora del Prado, Talavera de la Reina, Spain
⁸Allergy Department, Hospital Cruz Roja, Madrid, Spain
⁹Allergy Department, Hospital General Universitario de Alicante, Alicante, Spain

Key words: Bumblebee venom. Hymenoptera. Immunotherapy.

Palabras clave: Veneno de abejorro. Himenópteros. Inmunoterapia.

For many years, bee venom has been used to treat patients sensitized to bumblebee venom, as several studies have shown a high degree of cross-reactivity between bee and bumblebee venom [1]. Bumblebee venom allergy is rare in the general population, and normally results from primary sensitization to bee venom.

Bumblebees are less aggressive than bees and do not usually sting; consequently, allergic reaction to bumblebee stings is rare in the general population. However, in the last decade, the prevalence of allergy to hymenoptera has increased, specifically in the Mediterranean area (mainly Almería and Málaga), where bumblebees are increasingly used for pollination of greenhouse plants such as tomatoes, zucchini, and peppers.

As these flowers are not attractive to bees, farmers use bumblebees (especially *Bombus terrestris*) because they are larger than bees, can visit more plants per flight, work at low temperatures and low light intensity, and do not fly in swarms outside the greenhouse. The increased use of this species in greenhouses has led to an increase in the frequency of adverse reactions to bumblebee venom.

For many years, bee venom was used to treat patients sensitized to bumblebee venom, as commercial extracts of this specific type were not available and different studies showed a high degree of cross-reactivity between bee and bumblebee venom [1]. However, cross-reactivity between these venoms is often very low or nonexistent. Bumblebee phospholipase A2 was recently shown to be only 53% identical

to bee phospholipase A2 [2]. This finding could explain the failure of immunotherapy with bee venom in some patients who are allergic to bumblebee venom [3]. Consequently, immunotherapy with bee venom does not always protect these patients.

Patients sensitized to bumblebee venom can be divided into 2 types [4]. The first type comprises patients who present high cross-reactivity with bee venom, are not generally exposed to bumblebee professionally, and have primary sensitization to bee venom. The second type comprises patients who are specifically sensitized to bumblebee venom. They generally work in greenhouses and are frequently stung. As such patients show scarce cross-reactivity with bee venom, the European Academy of Allergy and Clinical Immunology [5] recommends the use of bumblebee venom for immunotherapy.

In Spain (mainly in Almería and Málaga), bumblebee venom (ALK-Abelló) has been used since 2005 for the diagnosis and treatment of allergic patients. Immunotherapy with bumblebee venom is similar to immunotherapy with bee and wasp venom, even with respect to the incidence of side effects [6].

Therefore, the committee would like to make the following recommendations:

1. Greenhouse workers who experience a systemic reaction following a bumblebee sting should undergo a study of sensitization to bumblebee venom.
2. Greenhouse workers who are allergic to bumblebee venom and have high levels of exposure should undergo immunotherapy with bumblebee venom.
3. Individualized preparations of pure extract of bumblebee venom such as those used in the present study should be readily available for purposes of diagnosis and treatment.

Acknowledgments

We are grateful to the other members of the Hymenoptera Committee of the Spanish Society of Allergology and Clinical Immunology (SEAIIC) (M Armisén, G Dalmau, and C Granel) for their support in this work. We are particularly grateful to F de la Torre for his help and critical review of the manuscript.

Conflicts of Interest/Disclosures

Dr Arantza Vega has been paid for lectures by ALK-Abelló and Laboratorios Leti.

Dr Salvador Fernández has contributed to a monograph on hymenoptera allergy sponsored by Allergy Therapeutics.

Dr Lluís Marquès has been a consultant for Stallergènes Ibérica, has provided expert testimony for ALK-Abelló, and has been paid for lectures by Allergy Therapeutics.

The remaining authors declare that they have no conflicts of interest.

References

1. Mueller UR. Insect Sting Allergy. Stuttgart: Gustav Fischer; 1990. 103-105.
2. Hoffman DR, El-Choufani SE, Smith MM, De Groot H. Occupational allergy to bumblebees: allergens of *Bombus terrestris*. *J Allergy Clin Immunol*. 2001;108:855-60.
3. Stern A, Wüthrich B, Müllner G. Successful treatment of occupational allergy to bumblebee venom after failure with honeybee venom extract. *Allergy*. 2000;55:88-91.
4. Fernández S, Baltasar M. Inmunoterapia con himenópteros: doble sensibilización. *J Investig Allergol Clin Immunol*. 2008;18(Suppl.3):73-5.
5. Bonifazi F, Jutel M, Biló BM, Birnbaum J, Muller U; EAACI Interest Group on Insect Venom Hypersensitivity. Prevention and treatment of hymenoptera venom allergy: guidelines for clinical practice. *Allergy*. 2005;60:1459-70.
6. De Jong NW, Vermeulen AM, de Groot H. Allergy to bumblebee venom. III. Immunotherapy follow-up study (safety and efficacy) in patients with occupational bumblebee-venom anaphylaxis. *Allergy*. 1999;54(9):980-4.

■ Manuscript received October 26, 2011; accepted for publication January 24, 2012.

Sergia Cruz

Unidad de Alergia
Hospital Torrecárdenas
Paraje Torrecárdenas, s/n
04009 Almería, Spain
E-mail: scruzg@gmail.com

Anaphylaxis Due to Sulpiride and Sensitization to Metamizole

MI Alvarado,¹ C Cámara,² A Trabado³

¹Allergy Unit, Coria Hospital, Coria, Cáceres, Spain

²Immunology Department, San Pedro de Alcántara Hospital Cáceres, Spain

³Allergy Unit, Campo Arañuelo Hospital, Navalmoral de la Mata, Cáceres, Spain

Key words: Drug anaphylaxis. Immunological test. Metamizole. Sulpiride.

Palabras clave: Anafilaxia por medicamentos. Tests inmunológicos. Metamizol. Sulpiride.

We report the case of a female patient who experienced an anaphylactic reaction due to hypersensitivity to sulpiride and sensitization to metamizole. Sulpiride is a selective dopamine 2 receptor antagonist belonging to the benzamide group. It has antidepressive, antiemetic, neuroleptic, and antivertigo properties. Only 1 case of immediate-type hypersensitivity (urticaria) to sulpiride has been reported [1]. Metamizole is a nonsteroidal anti-inflammatory drug belonging to the pyrazolone group that is frequently used as a mild analgesic. In Spain, nonsteroidal anti-inflammatory drugs are the second cause of immunoglobulin (Ig) E-mediated reactions to drugs. A search of MEDLINE revealed 40 articles on metamizole-induced allergy, some of which analyzed metamizole-induced anaphylaxis [2,3,4]. However, none of the articles reported hypersensitivity to sulpiride and metamizole.

A 29-year-old woman with no personal history of atopy was referred to our unit for an allergy workup because she had presented an anaphylactic reaction immediately after parental administration of 100 mg of sulpiride (Sanofi-Aventis) and 2 g of metamizole (Boehringer-Ingelheim) for renal colic. The reaction began with itching palms and progressed to generalized urticaria, edema, dysphagia, and dyspnea. The patient was treated with parenteral corticosteroids, antihistamines, and epinephrine in the emergency room. She had received these drugs in the past and subsequently tolerated ibuprofen and piroxicam.

After obtaining the patient's informed consent, we determined tryptase and specific IgE levels and performed a skin prick test (400 mg/mL) and intradermal test (1 mg/mL) with metamizole. Tryptase was within normal levels, and the results for specific IgE and prick test were negative. The result of the intradermal test was positive for 1 mg/mL (15 mm), with a wheal of 7 mm for histamine and no response for saline. Intradermal testing with metamizole was negative in 5 controls. A single-blind oral challenge test with sulpiride was performed to confirm that the patient could tolerate the drug, because we thought that her reaction was induced by metamizole. It was positive with 17 mg. The patient presented intense itching on her hands and wheals on her arms, back, and waist. The oral challenge was stopped, and the patient was immediately treated with 5 mg of parenteral dexchlorpheniramine (Schering

Plough), 40 mg of methylprednisolone (Sanofi-Aventis), and 0.3 mL of epinephrine 1 mg/mL. She remained under observation for 3 hours. One month later we performed skin tests with sulpiride and metamizole. Positive results were recorded for metamizole (prick test, 400 mg/mL [5 mm]; intradermal test, 1 mg/mL [8 mm]) and sulpiride (skin prick test, 5 mg/mL [6 mm]). Prick testing with histamine was positive (5 mm) and skin testing with metamizole was negative in 5 controls. These results demonstrate that the reaction was due to sulpiride, thus suggesting a type I hypersensitivity reaction.

The result of a basophil activation test with both drugs was positive, although the response was stronger for sulpiride: the activation threshold (minimum antigen concentration required for a positive test result) was lower for sulpiride (50-100 ng/mL [2.5 mg/mL with metamizole]) and the percentage of activated basophils after allergen stimulation was 4-fold higher for sulpiride than for metamizole. Basophil activation test results were negative in 5 controls (Figure).

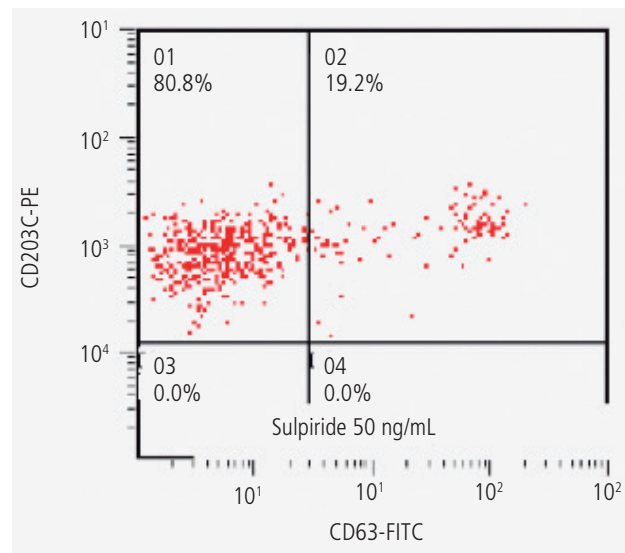


Figure. Basophil activation test.

We studied the chemical formula of sulpiride and metamizole to explain the cross-reactivity observed in our patient. Both drugs have similar O=S=O phenyl ring groups, although these groups are not similar 3-dimensionally. The phenyl group of metamizole is freely rotating, while sulpiride can be constrained by the O=S=O group. In addition, it seems that this group is not recognized by antibodies. The result of an inhibition test to assess cross-reactivity was negative.

We report a case of drug-induced anaphylaxis. Clinical findings and positive skin prick test results, as well as a positive challenge result with sulpiride, strongly suggest that the patient developed type I hypersensitivity. This is the first case of anaphylaxis to sulpiride. To our knowledge, this is also the first case of hypersensitivity to sulpiride and sensitization to metamizole. We investigated potential cross-reactivity between both results, although our results were inconclusive.

References

1. Botey E, López Abad R, Gázquez V, Gaig P. A case of urticaria due to sulpiride. *Allergy*. 2004;59(9):1020-1.
2. Echarri A, Tejedor R, Gomez de Segura JL, Marcos I. Acute myocardial infarction after intake of non-steroid anti-inflammatory drugs. *Semergen*. 2007;33(5):264-5.
3. Escolano F. [Severe anaphylactic reaction to metamizol during subarachnoid anaesthesia]. *Rev Esp Anestesiol Reanim*. 2004;51(3):151-4. Spanish.
4. Abeledo MA. [Anaphylactic reaction versus carcinoid crisis: the role of octeotride as a vasoconstrictor]. *Rev Esp Anestesiol Reanim*. 2004;51(7):395-8. Spanish.
5. Rodríguez A, Cámara C, Ramos A, Porcel S, Jimenez S, Pereira G, et al. Basophil activation test for the in vitro diagnosis of nonsteroidal anti-inflammatory drug hypersensitivity. *Allergy Asthma Proc*. 29 (3): 241-249. 2008.

■ Manuscript received October 11, 2011; accepted for publication January 24, 2012.

María Isabel Alvarado

"Ciudad de Coria" Hospital
Cervantes, 75
10800 Coria, Spain

E-mail: maribeladiz@gmail.com

DRESS Syndrome in a 19-Year-Old Patient Following the Administration of First-Line Antituberculosis Drugs

R Rodríguez,¹ V Jover,¹ I Orozco,² J Domenech¹

¹Allergology Department, Hospital General de Elda, Alicante, Spain

²Hospital USP San Jaime, Torrevieja, Spain

Key words: DRESS syndrome. Lymph node tuberculosis. Antituberculosis drugs.

Palabras clave: Síndrome DRESS. Nódulos linfáticos con infiltración tuberculosa. Fármacos antituberculosos.

A 19-year-old man was diagnosed with lymph node tuberculosis and treated with first-line antituberculosis drugs (isoniazid, rifampin, pyrazinamide, and ethambutol). After 2 weeks on treatment, he developed generalized erythematous papular rash, for which he made repeated visits to the emergency department. He was eventually admitted to the pneumology department. During his stay, the patient developed fever, leukocytosis, and eosinophilia, as well as liver failure, and was therefore admitted to the intensive care unit. His condition improved gradually following discontinuation of all the drugs he was taking before the reaction and treatment with high-dose parenteral corticosteroids. The result of a sputum test for *Mycobacterium tuberculosis* was negative. Serology testing for human herpes virus (HHV) types 1 and 2 was positive, and testing for other herpes viruses (eg, cytomegalovirus, Epstein-Barr virus), human immunodeficiency virus, and hepatitis was negative.

Following recent recommendations [1,2], we performed prick tests, intradermal tests (1:100, 1:1000), and patch tests (10% in water). The immediate and delayed readings (at 48 and 72 hours) were negative for all tests. The results of the tests were also negative in healthy controls.

When the result of the HHV serology test became negative, we performed systematic challenge tests with each drug involved in the process. We left an interval of at least 1 month between one challenge and the next to avoid false positives due to the fluctuations in eosinophilia that are inherent to drug reaction with eosinophilia and systemic symptoms (DRESS)

Table. Drug Challenge Tests

	Total Dose Administered	Clinical and Laboratory Findings
Isoniazid	90 mg	Pruritus, eosinophilia
Rifampin	50 mg	Pruritus, wheals
Pyrazinamide	125 mg	Pruritus, erythema, eosinophilia, hepatitis
Ethambutol	1200 mg	Exanthema, fever, eosinophilia

syndrome [3]. The symptoms that led to the patient being admitted to the intensive care unit were reproduced to a greater or lesser extent with each of the 4 drugs (Table). In each case, the patient responded well to corticosteroids.

Although sensitization to several drugs in DRESS syndrome has been reported [4], we tried all 4 first-line antituberculosis drugs because of the adverse reactions and administration difficulties inherent to second-line drugs. If the patient had tolerated only 1 of the first-line drugs, chronic treatment would have been much easier. Specific sensitization to rifampin and pyrazinamide has also been reported [1,2].

Finally, we decided to perform challenge tests with second-line drugs. The patient tolerated therapeutic doses of levofloxacin, streptomycin, para-aminosalicylic acid, and prothionamide.

Given the risk of fatal outcome, we did not try to desensitize the patient to isoniazid, rifampin, pyrazinamide, or ethambutol, and he was advised not to take these drugs. Desensitization protocols are contraindicated in patients with DRESS syndrome.

DRESS syndrome is characterized by the presence of at least 3 of the following findings: fever, rash, eosinophilia, atypical circulating lymphocytes, enlarged lymph nodes, and elevated transaminases related to liver failure. The reaction is generally induced by specific drugs, the most typical being allopurinol, sulfonamides, and aromatic antiepileptic agents such as phenytoin, phenobarbital, and carbamazepine [5]. Most reactions are with phenytoin. As DRESS syndrome is a potentially fatal condition, the drugs responsible for the reaction must be discontinued immediately, and high doses of corticosteroids must be given along with supportive measures [6]. Although the pathophysiology of DRESS syndrome is unknown, it is believed that herpes viruses may play a role in the syndrome, particularly HHV-6, HHV-7, cytomegalovirus, and Epstein-Barr virus.

In DRESS syndrome secondary to drug administration and in other types of life-threatening delayed-type reactions or reactions not mediated by immunoglobulin (Ig) E, such as erythema multiforme major and toxic epidermal necrolysis, the pathophysiological and immunological mechanisms are unknown. This represents a significant difference from IgE-mediated sensitization, which is relatively easy to control within the context of challenge tests and desensitization. In the case we report, we had the difficult choice of either directly prohibiting administration of first-line drugs in a young patient or exercising great caution and administering them one after another, leaving a reasonable gap between each one, to clarify whether it was only one or several of them that had actually triggered the severe symptoms that led to the patient being admitted to the intensive care unit. Finally, in view of the severity of the symptoms of the patient's lymph node tuberculosis, we decided to proceed with the challenge test, which was positive for every drug we tested.

No systematic skin tests or challenge tests have been performed with first-line antituberculosis drugs in similar cases. Furthermore, the results observed lead us to hypothesize that the cross-reactivity between isoniazid, rifampicin, pyrazinamide, and ethambutol cannot be explained in terms of chemical structure. The pharmacological interaction with

immune receptors (p-i concept) could have played a role in this case. Drug allergy is an example of the drug-receptor interaction, where the consequence of the interaction results in T-cell activation and expansion: this stimulation is dependent on an additional major histocompatibility complex interaction for full activation of the reactive T cell, which results in cytokine synthesis, proliferation, and, probably, clinical symptoms. As the reaction mimics an immunologic response, it is interpreted as an immune mechanism, although it is actually drug-driven T-cell expansion. The stimulated T cells have additional peptide specificity, which is unknown [7]. This concept can also explain the low tolerance to the 4 different drugs analyzed in this study.

Acknowledgments

During the acute clinical phase the patient was hospitalized and treated by the Pneumology Department and the Intensive Care Unit at Hospital General de Elda (Alicante, Spain). The authors are grateful to Sandra Rossi Baixauli (ALK Abelló), Dr. Luis Prieto, M^a Dolores Alcolea, and M^a Auxiliadora Pacheco for their contribution to this article.

References

- Rodrigues Carvalho S, Silva I, Leiria-Pinto P, Rosado-Pinto J. Rapid oral tolerance induction to isoniazid and pyrazinamide and controlled administration of ethambutol: clinical case. *Allergol Immunopathol (Madr)*. 2009 Nov-Dec;37(6):336-8.
- Strauss RM, Green ST, Gawkrödger DJ. Rifampicin allergy confirmed by an intradermal test, but with a negative patch test. *Contact Dermatitis*. 2001;45:108.
- Walsh SA, Creamer D. Drug reaction with eosinophilia and systemic symptoms (DRESS): a clinical update and review of current thinking. *Clin Exp Dermatol*. 2011 Jan;36(1):6-11.
- Joo Ho Lee y col. Drug Rash with Eosinophilia and Systemic Symptoms (DRESS) syndrome induced by celecoxib and anti-tuberculosis drugs. *J Korean Med Sci*. 2008;23:521-5.
- Chaabane A, Aouam K, Ben Fredj N, A Boughattas N. [DRESS Syndrome: 11 Case Reports and a Literature Review]. *Therapie*. 2010 11-12;65(6):543-50. French.
- Fleming P, Marik PE. The DRESS syndrome: the great clinical mimicker. *Pharmacotherapy*. 2011 Mar;31(3):332.
- Posadas SJ, Pichler WJ. Delayed drug hypersensitivity reactions - new concepts. *Clin Exp Allergy*. 2007 Jul;37(7):989-99. Review.

■ Manuscript received October 23, 2011; accepted for publication January 31, 2012.

Joan Domenech Witek
Hospital General de Elda
Ctra. Elda-Sax, Ptda. La Torreña, s/n
03600 Elda, Alicante, Spain

Severe Reaction Following Sugammadex Injection: Hypersensitivity?

A Soria,¹ C Motamed,² H Gaouar,¹ S Chemam,² E Amsler,¹ C Francès¹

¹Service de dermato-allergologie, Hôpital Tenon, APHP, Paris, France

²Service d'anesthésie-réanimation, Institut Gustave-Roussy, Villejuif, France

Key words: Cyclodextrins. Hypersensitivity. Sugammadex.

Palabras clave: Ciclodextrinas. Hipersensibilidad. Sugammadex.

Sugammadex is a modified γ -cyclodextrin that was recently approved for reversal of the neuromuscular blockade induced by rocuronium and vecuronium [1].

A 62-year-old man (65 kg, 173 cm) underwent laryngoscopy for evaluation of a vocal cord tumor. He was taking acebutolol for arterial hypertension and simvastatin for hypercholesterolemia. The patient was sedated with propofol, and remifentanyl and rocuronium 0.6 mg/kg were administered for tracheal intubation. Antibiotic prophylaxis (2 g amoxicillin-clavulanic acid) was also administered. The laryngoscopy was performed without difficulty. At the end of the procedure, sugammadex (150 mg [2.3 mg/kg]) diluted in 0.9% saline was injected. Within 3 minutes following the injection, the patient developed intense erythema without edema, systolic blood pressure fell below 45 mmHg with tachycardia (150 beats/min), and oxygen saturation fell to 40% without bronchospasm. He received an epinephrine bolus to maintain hemodynamic stability and was transferred, ventilated, to the intensive care unit. The patient was gradually weaned from mechanical ventilation and epinephrine.

Three hours after the reaction, the patient's histamine level was >100 nmol/L (reference value, <10 nmol/L), whereas the tryptase level was normal. Five months later, the patient underwent a skin prick test with undiluted solutions of all the drugs injected and intradermal tests with propofol (0.01, 0.1, and 1 mg/mL), rocuronium (0.01 and 0.1 mg/mL), remifentanyl (0.0003 and 0.003 mg/mL), sugammadex (100 mg/mL and 0.1 mg/mL), amoxicillin-clavulanic acid (2, 20 and 200 mg/mL), and a prick test with latex. All the tests showed negative results except for the prick test with sugammadex 100 mg/mL (6-30 mm) and intradermal test with sugammadex 0.1 mg/mL (9-40 mm) (with positive histamine control to 9-30 mm). The sugammadex prick test was negative at 20 minutes, but showed a positive result at 30 minutes; hence the positive result with the 0.1 mg/mL intradermal test. A challenge test with amoxicillin-clavulanic acid produced no reaction. Testing with sugammadex under the same conditions in 5 control participants was negative. We did not perform in vitro tests with β -lactams or neuromuscular blocking agents.

Sugammadex is the first selective relaxant-binding agent indicated for reversal of neuromuscular blockade since May 2009. Only a few cases of hypersensitivity reaction have

been reported to date. The case report by Menéndez-Ozcoidi et al [2] is very similar to ours, except that the patient had milder symptoms. Laboratory tests revealed a high histamine level and normal tryptase level with a positive skin prick test result [2]. During a phase I trial with sugammadex, 1 out of 13 volunteers experienced a hypersensitivity reaction following the first exposure to the product. The infusion was discontinued, and the result of an intradermal skin test was positive [3]. In 2 phase I trials (n=62 and n=83), 6 volunteers experienced hypersensitivity symptoms (rash and flushing which did not require treatment) after receiving sugammadex at 32 mg/kg [1,4].

Due to the severity of the reaction in our case and the positive skin test results with sugammadex, we diagnosed this reaction as an allergic hypersensitivity reaction. However, the normal tryptase levels could suggest nonallergic hypersensitivity. Given that the patient had never received sugammadex, we can speculate that he became sensitized via oral ingestion of cyclodextrins in food. More cases are needed to determine the mechanisms underlying this kind of reaction. Nevertheless, physicians must be aware of potential hypersensitivity reactions to sugammadex, and allergists must include sugammadex in their anesthetics testing protocol.

References

1. Yang LP, Keam SJ. Sugammadex: a review of its use in anaesthetic practice. *Drugs*. 2009;69:919-42.
2. Menéndez-Ozcoidi L, Ortiz-Gómez JR, Olaguibel-Ribero JM, Salvador-Bravo MJ. Allergy to low dose sugammadex. *Anaesthesia*. 2011;66:217-9.
3. Peeters PA, van den Heuvel MW, van Heumen E, Passier PC, Smeets JM, van Iersel T, Zwiers A. Safety, tolerability and pharmacokinetics of sugammadex using single high doses (up to 96 mg/kg) in healthy adult subjects: a randomized, double-blind, crossover, placebo-controlled, single-centre study. *Clin Drug Investig*. 2010;30:867-74.
4. FDA Anesthetic and Life Support Advisory Committee Meeting Sugammadex Sodium Injection (NDA 22-225) March 11, 2008 (online: available from URL: <http://www.fda.gov/ohrms/dockets/ac/08/briefinf/2008-4346b1-02-Orgaron.pdf>).

■ Manuscript received September 5, 2011; accepted for publication February 16, 2012.

A Soria

Service de dermato-allergologie
Hôpital Tenon, APHP
4 rue de la Chine
75020 Paris
France

Occupational Asthma Caused by the Inhalation of *Tyrophagus putrescentiae* Allergens in a Dry-Cured Ham Transporter Allergic to Shrimp

P Rodríguez del Río,^{1,2} JI Tudela García,³ NJ Narganes,¹
E Fernández-Caldas,³ V Rodríguez-García,¹ J Subiza¹

¹Subiza Asthma and Allergy Centre, Madrid, Spain

²Allergy Department, Niño Jesus University Hospital, Madrid, Spain

³Immunotek Laboratories, Madrid, Spain

Key words: Dry-cured ham. Occupational asthma. Shrimp. *Tyrophagus putrescentiae*.

Palabras clave: Jamón. Asma ocupacional. Gamba. *Tyrophagus putrescentiae*.

Up to 15% of adult-onset asthma is due to the inhalation of occupational allergens [1]. Dust mites may be implicated in 5% of all cases, but the prevalence of mite sensitization among farm workers and bakers can be higher [1]. Cross-reactivity between seafood and mites has been widely described [2]. We report a case of occupational asthma caused by the mite *Tyrophagus putrescentiae* in a dry-cured ham delivery man who was allergic to shrimp.

A 43-year-old man who had always lived in Madrid, a region with a low prevalence of mite sensitization [3], had worked transporting dry-cured ham in a van since he was 30 years old. At the age of 38 years, he developed moderate persistent rhinoconjunctivitis, cutaneous pruritus, and dyspnea that worsened on week days and improved at weekends and during holidays. The patient spent most of the time at work in his van on delivery duties. When he was 40 years old, he experienced 2 episodes of oral pruritus and lip angioedema immediately after eating boiled shrimp; the symptoms subsided 3 hours after the administration of oral antihistamines. After these episodes, he developed oral pruritus on trying small amounts of other crustaceans at home. He had good tolerance of cephalopods, molluscs, and dry-cured ham, including the ham he delivered.

The patient was tested with a commercially available series of allergens. Skin prick test results were positive to *T putrescentiae*, *Acarus siro*, *Dermatophagoides pteronyssinus*, *Dermatophagoides farinae*, *Dermatophagoides microceras*, *Lepidoglyphus destructor*, *Euroglyphus maynei*, *Blomia tropicalis*, and shrimp, and negative to pollen, cat and dog dander, and molds. A prick to prick test with a portion of the dry-cured ham the patient transported was negative for the meat but positive for the crust of the ham. Total immunoglobulin (Ig) E was 287 kU_A/L, and specific IgE (CAP Phadia) was 12.5 kU_A/L for *T putrescentiae* and 3.11 kU_A/L for shrimp, and negative for recombinant Pen a 1 (tropomyosin

from brown shrimp), *Penicillium notatum*, *Aspergillus fumigatus*, and *Alternaria alternata*.

Baseline rhinomanometry and spirometry were normal. After a negative bronchial challenge with saline solution, a nonspecific bronchial challenge with methacholine was slightly positive (20% fall in forced expiratory volume in the first second [FEV₁] from baseline [PC₂₀] at 7.62 mg/mL) whilst the patient was on sick leave; 2 weeks after he returned to work, a PC₂₀ of 0.53 mg/mL was recorded. The patient refused to undergo an oral challenge with shrimp in our center.

Examination of a sample of dry-cured ham provided by the patient demonstrated extensive contamination with *Tyrophagus* species, although it could not be determined if they were *T putrescentiae* or *Tyrophagus longior*. The patient also reported that the inside of his delivery van, specially the floor, was filled with mites. A specific positive bronchial challenge with a commercial extract of *T putrescentiae* (Immunotek Laboratories) was carried out starting at a 1:1 000 000 w/v concentration with 10-fold increments until a bronchial response was obtained. A 20% decrease in FEV₁ was registered when a concentration of 1:1000 w/v was reached. No late-phase response was observed.

The aforementioned clinical and laboratory findings led to the diagnosis of shrimp allergy and occupational asthma due to *T putrescentiae* allergy. Further in vitro analyses were conducted to confirm the sensitivity of the patient.

Specific IgE to natural (n) Pen m 1 (tropomyosin from *Penaeus monodon*/giant tiger prawn) and nPen i 1 (tropomyosin from *Penaeus indicus*/Indian white prawn) (Bial Aristegui) were determined by enzyme-linked immunosorbent assay (ELISA). Values were expressed in optical densities (OD) as the mean of duplicate determinations minus the blank. Both determinations were positive: 1.18 OD for nPen m 1 and 0.76 OD for nPen i 1, confirming sensitization to tropomyosin in these shrimp species.

ELISA competition assays were conducted to investigate cross-reactivity between *T putrescentiae* and shrimp. Using *T putrescentiae* on the solid phase, the shrimp extract

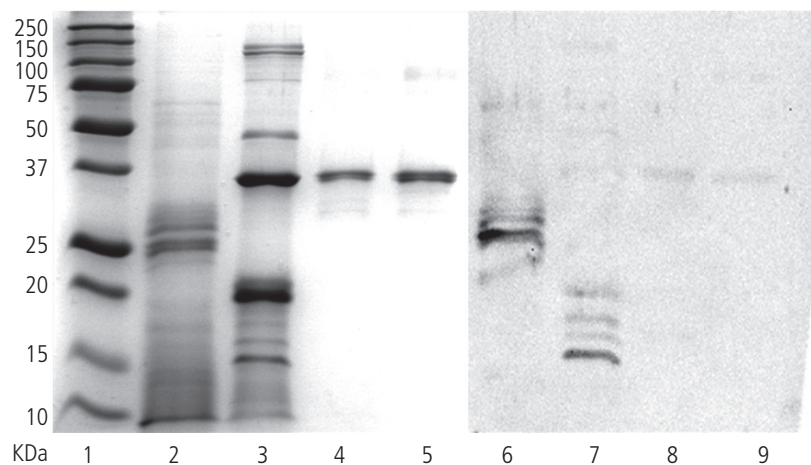


Figure. Sodium dodecyl sulfate polyacrylamide gel electrophoresis (Lanes 1-5) and immunoblots (Lanes 6-9) of *Tyrophagus putrescentiae*, shrimp, natural (n) Pen m 1, and nPen i 1. Lane 1: molecular weight markers. Lanes 2 and 6: *Tyrophagus putrescentiae*. Lanes 3 and 7: shrimp. Lanes 4 and 8: nPen m 1. Lanes 5 and 9: nPen i 1.

was not able to inhibit IgE binding to *T putrescentiae*, but *T putrescentiae* exhibited 40% inhibition of specific IgE binding to shrimp. This suggests a low degree of cross-reactivity between *T putrescentiae* and shrimp.

Sodium dodecyl sulfate polyacrylamide gel electrophoresis of the *T putrescentiae* extract under reduced conditions showed intense bands at approximately 26 kDa and 37 kDa, which may correspond to Tyr p 3 [4] and Tyr p 10 [5]. Under the same conditions, the shrimp extract displayed several bands, including one at 35 kDa that may correspond to shrimp tropomyosin. The same band was visualized for nPen m 1 and nPen i 1. The sera of the patient bound specific IgE to bands at approximately 26 kDa in the *T putrescentiae* extract and to 4 bands between 15 and 20 kDa in the shrimp extract. Diffuse binding to tropomyosin was observed in the shrimp extract.

Dry-cured hams are an ideal substrate for the growth of several mite species [6]. Despite the widespread distribution of mites, in our review of the literature, we found only 1 case of upper respiratory tract symptoms caused by occupational exposure to *T putrescentiae* [7]. We also found cases of contact dermatitis caused by exposure to *T putrescentiae* in contaminated meat products [8,9], but none of the patients showed respiratory symptoms. It is noteworthy that our patient had been working for 8 years before he started to experience symptoms, but latency periods of up to 18 years have been reported for sensitization to storage mites [10]. To the best of our knowledge, this is the first report of occupational asthma due to *T putrescentiae* in a dry-cured ham worker.

In view of the low degree of cross-reactivity observed between shrimp and *T putrescentiae* in the inhibition assays, and the small amounts of tropomyosin detected in mites [2], proteins other than tropomyosin may have been implicated. Based on our results we cannot say whether in our patient, shrimp allergy was a consequence of primary sensitization to *T putrescentiae* by cross-reactivity or an allergy due to a new sensitization and thus, an unrelated event.

We have presented a case of occupational asthma caused by *T putrescentiae* contaminating dry-cured ham in a patient with shrimp allergy. The most peculiar aspect of this case is the uncommon source of exposure. More attention should be given to van or car environments as a potential source of occupational allergens, especially in relation to the transport of food that is prone to contamination by mites.

References

1. Kogevinas M, Zock JP, Jarvis D, Kromhout H, Lillienberg L, Plana E, Radon K, Torén K, Alliksoo A, Benke G, Blanc PD, Dahlman-Hoglund A, D'Errico A, Héry M, Kennedy S, Kunzli N, Leynaert B, Mirabelli MC, Muniozgueren N, Norbäck D, Olivieri M, Payo F, Villani S, van Sprundel M, Urrutia I, Wieslander G, Sunyer J, Antó JM. Exposure to substances in the workplace and new-onset asthma: an international prospective population-based study (ECRHS-II). *Lancet*. 2007;370(9584):336-41.
2. Arlian LG, Morgan MS, Vyzenski-Moher DL, Sharra D. Cross-reactivity between storage and dust mites and between mites and shrimp. *Exp Appl Acarol*. 2009 Feb;47(2):159-72.
3. Sastre J, Iraola V, Figueredo E, Tornero P, Fernández-Caldas E. Mites in Madrid. *Allergy*. 2002 Jan;57(1):58-9.
4. Liao EC, Hsu EL, Tsai JJ, Ho CM. Immunologic characterization and allergenicity of recombinant Tyr p 3 allergen from the storage mite *Tyrophagus putrescentiae*. *Int. Arch. Allergy Immunol*. 150 (1), 15-24 (2009).
5. Jeong KY, Lee H, Lee JS, Lee J, Lee IY, Ree HI, Hong CS, Yong TS. Molecular cloning and the allergenic characterization of tropomyosin from *Tyrophagus putrescentiae*. *Protein Pept Lett*. 2007;14(5):431-6.
6. García N. Efforts to control mites on Iberian ham by physical methods. *Exp Appl Acarol*. 2004;32(1-2):41-50.
7. Armentia A, Fernández A, Pérez-Santos C, de la Fuente R, Sánchez P, Sanchís F, Méndez J, Stolle R. Occupational allergy to mites in salty ham, chorizo and cheese. *Allergol Immunol*. 1994. 22(4): 152-4
8. Vidal C, Rial A. Airborne contact dermatitis from *Tyrophagus putrescentiae*. *Contact Dermatitis*. 1996; 38: 181
9. Quiñones Estévez MD. Occupational urticaria-dermatitis by *Tyrophagus putrescentiae*. *Contact Dermatitis*. 2006. 55: 308-9
10. Boquete M, Carballada F, Armisen M, Nieto A, Martín S, Polo F, Carreira J. Factors influencing the clinical picture and the differential sensitization to house dust mites and storage mites. *J Investig Allergol Clin Immunol*. 2000 Jul-Aug;10(4):229-34.

■ Manuscript received November 24, 2011; accepted for publication, February 16, 2012.

Pablo Rodríguez del Río

Centro de Asma y Alergia Subiza
Calle General Pardiñas 116
28006 Madrid, Spain
E-mail: prrio@yahoo.es

Hypersensitivity to Cassava: An Allergen-Based Assessment

D Antolin-Amerigo,¹ M Rodriguez-Rodriguez,¹ J Barbarroja-Escudero,¹ I Postigo Resa,² M Ceballos Uribe-Etxebarria,² M Alvarez-Mon¹

¹Servicio de Enfermedades del Sistema Inmune-Alergia, Hospital Universitario "Príncipe de Asturias", Departamento de Medicina, Universidad de Alcalá, Madrid, Spain

²Dpto. de Inmunología, Microbiología y Parasitología, Lab. Parasitología e Inmunología, Facultad de Farmacia, Centro de Investigación Lucio Lascaray, Universidad del País Vasco, Vitoria, Spain

Key words: Manihot. rHev b 5. Anaphylaxis. Latex. Hypersensitivity

Palabras clave: Yuca. rHev b 5. Anafilaxia. Látex. Hipersensibilidad.

Cassava (*Manihot esculenta*), also called yuca or manioc, is a woody shrub of the Euphorbiaceae (spurge family) native to South America. It is extensively cultivated as an annual crop in tropical and subtropical regions for its edible starchy tuberous root, a major source of carbohydrates. Cassava is the third largest source of food carbohydrates in the world and is sometimes described as the "bread of the tropics". It must be cooked properly to detoxify it before it is eaten in various ways (soft-boiled root, deep-fried, toasted, or as root flour). It has become a staple food in South America, Mesoamerica, the Caribbean, subtropical Africa, and Southern Asia, but is not common in Europe.

We describe the case of a 47-year-old Colombian woman, resident in Spain, who reported 2 anaphylactic reactions (with elevated baseline serum tryptase levels) in a 5-month interval. The episodes had occurred immediately after ingestion of boiled cassava. She denied a history of atopy and did not complain of symptoms in springtime or following the intake of fruit or vegetable. She did, however, report pruritic erythema on inflating balloons or using rubber gloves.

Skin prick tests (SPTs) were performed with the most common aeroallergens in our area, with food consumed in a regular diet, and with vegetables known to cross-react with latex (chestnut, kiwi, passion fruit, avocado, banana, papaya, melon, tomato, and spinach). The results were negative in all cases. Prick to prick testing with raw and boiled cassava showed strongly positive results (wheal size equal to the size of the histamine wheal and with 6 atopic patients as negative controls). An SPT with a commercial latex extract (Stallergenes) was also strongly positive.

Total immunoglobulin (Ig) E was 104 IU/L, and specific IgE to latex measured by CAP (Phadia) was 68.20 kU/L. ImmunoCAP ISAC (Phadia) consisting of a panel of 103 allergens was used to elucidate possible specific IgEs, eliciting exclusively 9.5 ISU for Hev b 5.

To activate the cassava extract with biotin, the extract was diluted in phosphate-buffered saline at 1 mg protein/mL and biotinylated following the manufacturer's instructions (Roche Diagnostics GmbH) at a ratio of 1 to 5 moles. Following the procedures described by Sander et al [1], prewashed solid-phase Streptavidin ImmunoCAP (Phadia AB) was loaded with 50 μ L of biotinylated cassava extract and incubated for 30 minutes at 37°C. The cassava extract coupled to Streptavidin ImmunoCAP was used to determine specific IgE in the ImmunoCAP 100 System (Phadia AB).

Likewise, specific IgE to recombinant Hev b 5 (rHev b 5) and natural rubber latex was measured using UniCap 100. Specific IgE to cassava was 5 kU/L.

To determine the level of cross-reactivity between rHev b 5 and cassava, immunoassay inhibitions were carried out as described by Cardona et al [2]. Cassava extract and Hev b 5 were used as solid phases, as previously described [3,4]. Cassava extract was used as the inhibitor. A 1:1 dilution of these sera was preincubated overnight at 4°C with cassava extract. After centrifugation, the specific IgE responses were measured using ImmunoCAP 100, and the percentage of inhibition was calculated. The corresponding controls consisting of cassava extract and rHev b 5 were included. The use of rHev b 5 as the solid phase and cassava extract as the inhibitor resulted in 85% inhibition. Similarly, the use of cassava extract as the solid phase and rHev b 5 as the inhibitor resulted in 82% inhibition.




Figure. immunoglobulin (Ig) E-binding bands of 22 and 25 KDa with an isoelectric point of 5.5 revealed by IgE immunoblotting. IP indicates isoelectric point; MW, molecular weight.

Two-dimensional (2D) electrophoresis was performed following standard methods. Briefly, samples were loaded onto first-dimension IPG strips with a pH of 7 to 10 (BioRad Hercules) and focused using a PROTEAN IEF cell (BioRad), according to the manufacturer's instructions. The proteins were separated in the second dimension in 10% SDS polyacrylamide gels, and were then either stained with Coomassie brilliant blue R-250 or transferred to a PVDF membrane. The PVDF membrane was incubated overnight with the patient's sera at 4°C with agitation. After incubation for 1 hour with mouse anti-human IgE (Fc) horseradish peroxidase conjugate (SouthernBiotech), chemiluminescent reagents (ECL1, Western Blotting Detection Reagents, Amersham Biosciences) were used to detect the immune complex using a Chemi Doc XR Reader (BioRad). Immunoblotting of the cassava extract showed 2 IgE-binding spots of 22 and 25 kDa, with an isoelectric point of 5.5 (Figure). Cross-reactivity assessment between cassava and latex was performed by 2D-immunoblotting inhibition following the previously described procedures, using cassava extract as the solid phase and latex extract as the inhibitor. After inhibition, a unique spot of 25 kDa, with an isoelectric point of 5.5, corresponding to the specific cassava allergen, was detected.

The IgE-binding spots revealed by 2D-immunoblotting were sent to the Proteomic Unit (CNIC Foundation) for identification by MALDI-TOF (matrix-assisted laser desorption/ionization-time-of-flight mass spectrometry) and tandem mass spectrometry. The amino acid sequence was assessed using Mascot software (Matrix Science) and the NCBI nr database. No peptide match was found, probably because of the low number of proteins described for cassava.

In our review of the literature, we found only 4 reports of patients developing anaphylaxis after the ingestion of boiled cassava (3 in Brazil and 1 in Spain, with latex-fruit syndrome) [5-7]. The allergen study showed different results regarding cross-reactivity between cassava and latex, which was attributed to Hev b 7 (patatin-like protein) in the Brazilian cases and to Hev b 6 (prohevein) in the Spanish case. In our patient (who did not have latex-fruit syndrome), the cross-reactivity with latex was related to Hev b 5 and we identified the specific allergen of cassava (molecular weight, 25 kDa) and an isoelectric point of 5.5 (not previously described).

In brief, we present a unique case of anaphylaxis to cassava in a patient without associated latex-fruit syndrome in which we demonstrated cross-reactivity with rHev b 5. To our knowledge, this is the first specific cassava allergen identified to date.

Acknowledgments

This work was partially supported by a grant from Comunidad de Madrid S2010/BMD-2502 MITIC.

References

1. Sander I, Kespohl S, Merget R, Goldscheid N, Degens PO, Bruning T, Raulf-Heimsoth M. A new method to bind allergens

for the measurement of specific IgE antibodies. *Int Arch Allergy Immunol.* 2005; 136(1): 39-44.

2. Cardona G, Guisantes J, Postigo I, Eraso E, Serna LA, Martínez J. Allergenic cross-reactivity between *Blomia tropicalis* and *Blomia kulagini* (Acari: Echiromphodidae) extracts from optimized mite cultures. *J Invest Allergol Clin Immunol.* 2005; 15:259-65.
3. Postigo I, Gutiérrez-Rodríguez A, Fernández J, Guisantes JA, Suñén E, Martínez J. Diagnostic value of Alt a 1, fungal enolase and manganese-dependent superoxide dismutase in the component-resolved diagnosis of allergy to Pleosporaceae. *Clin Exp Allergy.* 2011 Mar;41(3):443-51
4. Rodrigo MJ, Postigo I, Wangenstein O, Guisantes JA, Martínez J. A new application of Streptavidin ImmunoCAP for measuring IgG antibodies against non-available commercial antigens. *Clin Chim Acta.* 2010 Nov 11; 411(21-22):1675-8.
5. Galvao CES, Iwai LK, Andrade MEB, Kalil J, Morato Castro F.F. Latex allergy and cross-reactivity to manioc: report of 2 cases. *J Allergy Clin Immunol.* 2004; 113 (2 Suppl): S61.
6. Gaspar A, Neto-Braga C, Pires G, et al. Anaphylactic reaction to manioc: cross-reactivity to latex. *Allergy.* 2003; 58(7):683-4
7. Ibero M, Castillo MJ, Pineda F. Allergy to cassava: a new allergenic food with cross-reactivity to latex. *J Investig Allergol Clin Immunol.* 2007; 17 (6):409-12.

■ Manuscript received November 24, 2011; accepted for publication, February 16, 2012.

Dario Antolin-Amerigo

Servicio de Enfermedades del Sistema
Inmune-Alergia
Hospital Universitario Príncipe de Asturias
Carretera de Alcalá-Meco s/n.
28085.Alcalá de Henares
Madrid. Spain.
Email: dario.antolin@gmail.com

Quantitative Measurement of Allergen-Specific Immunoglobulin E Levels in Mass Units (ng/mL): An Interlaboratory Comparison

M López-Hoyos,¹ MT Lizaso,² JJ Rodríguez,³ ML Sanz,⁴
 M Labrador-Horrillo,⁵ R Ramos,⁶ M Martín-Esteban,⁷
 R Pastor,⁸ MD Hernández,⁹ ML Casas,¹⁰ A Peláez,¹¹ BE García²
¹*Servicio Inmunología, Hospital Universitario Marqués de Valdecilla-IFIMAV, Santander, Spain*
²*Servicio Alergología, Complejo Hospitalario de Navarra, Pamplona, Spain*
³*Servicio Inmunología, Hospital General Universitario Gregorio Marañón, Madrid, Spain*
⁴*Departamento de Alergología e Inmunología Clínica, Clínica Universidad de Navarra, Pamplona, Spain*
⁵*Servicio Alergología, Hospital Vall d'Hebron, Barcelona, Spain*
⁶*Servicio Análisis Clínicos, Hospital Virgen de la Victoria, Málaga, Spain*
⁷*Sección Alergología, Hospital Universitario La Paz, Madrid, Spain*
⁸*Servicio Análisis Clínicos, Hospital Joan XXIII, Tarragona, Spain*
⁹*Servicio Análisis Clínicos, Hospital Virgen de la Luz, Cuenca, Spain*
¹⁰*Servicio Análisis Clínicos, Fundación Hospital Alcorcón, Madrid, Spain*
¹¹*Servicio Alergología, Hospital Clínico, Valencia, Spain*

Key words: Specific IgE. ng/mL. KU_A/L, Multicenter. Inter-laboratory variation.

Palabras clave: IgE específica. ng/ml. KU_A/L. Multicéntrico. Variación interlaboratorio.

In vitro quantification of allergen-specific immunoglobulin (Ig) E (sIgE), together with skin testing, is of great value in the diagnosis of allergic disease. Recent years have witnessed developments in immunological assays for sIgE and the introduction of several rapid, automated assays for clinical diagnosis. Technical improvements have led to enhanced analytical sensitivity and quantitation of sIgE assays and widely adopted calibration methods traceable to an international IgE reference preparation [1]. For sIgE assays, however, there are currently no universally accepted allergen-specific IgE antibody standards. Instead, heterologous interpolation of allergen-specific IgE antibody results from a total IgE dose-response curve based on the World Health Organization (WHO) IgE standard 75/502 has become an accepted calibration method [2]. A number of studies have noted considerable discrepancies between kU_A/L values obtained by different methods [3,4]. Furthermore, proficiency testing has demonstrated that sIgE results obtained using different systems are not comparable, despite being related to the same reference material (eg, WHO IgE 75/502 standard) [3]. In clinical practice, this problem has been overcome by the use of classes of sIgE instead of kU_A/L. Recent guidelines,

however, such as those proposed for food allergy, have clearly urged laboratories to replace the use of classes by kU_A/L [5].

kU_A/L sIgE can be converted to mass units per volume using a conversion factor of 2.4 (1 kU_A/L sIgE=0.994 kU/L total IgE=2.4 ng/mL sIgE) [6]. The aim of this study was to evaluate interlaboratory variation in the measurement of serum sIgE levels converted to ng/mL and to compare results with those observed with traditional kU_A/L measurements.

Ten laboratories from different hospitals in Spain that perform in vitro allergy diagnosis participated in the study. The manufacturer of the ImmunoCAP 250 system used for testing (Phadia AB, Uppsala, Sweden) made the necessary arrangements to measure sIgE in ng/mL and kU_A/L. Once the study had been approved by the participating laboratories and the manufacturer, serum samples were collected as explained below.

Random clinical samples sent for routine analysis were collected in the serum banks of 2 of the participating laboratories. The selected samples were thawed and mixed to make 52 serum pools covering an sIgE range of 0.1 kU_A/L to 100 kU_A/L for the most prevalent allergens (f1, f2, f3, f13, f24, d1, e1, e5, g6, t9, w6, w21, m6, p4, c2, i1). Several pools corresponding to different sIgE levels were considered: high (H) (50-100 kU_A/L), medium (M) (3.5-50 kU_A/L), low (L) (0.35-3.5 kU_A/L), and extra-low (EL) (<0.35 kU_A/L). Aliquots stored at 4°C to 8°C were immediately shipped to the participating laboratories for analysis.

Serum samples were measured in monoplicate by the ImmunoCAP 250 in 2 separate runs: one for classical kU_A/L units and the other for mass units in ng/mL using a new curve and prototype reagents for ng/mL prepared by Phadia AB. All the reagents and calibrators used by the 10 participating laboratories belonged to the same lot to avoid a further source of variability. Standards for calculating the curve in ng/mL and necessary modifications to the software were prepared by the equipment manufacturer.

Results were analyzed using the SPSS 15.0 software package. Means, SDs, and interlaboratory coefficients of variation (CVs) were calculated for all the results reported in both units by the 10 participating laboratories. Linear regression, using kU_A/L converted to ng/mL by a global or laboratory-specific conversion factor, was used to compare the 2 measurement units. Bland-Altman plots were performed to illustrate the difference between the 2 measurements against the mean of the 2 measurements. Bland-Altman logarithmic differences between kU_A/L and ng/mL were calculated for the overall results [7].

The results obtained for each of the pooled serum samples tested for sIgE in both units are shown in the Table. In general, the CVs were similar and below 30% for each sIgE tested at all the serum levels. No differences were found in terms of interlaboratory CV for either of the units.

We found a quantitative agreement between kU_A/L and ng/mL. The results for sIgE to all the allergens as a whole were plotted on a linear plot and a logarithmic Bland-Altman plot (data not shown), and showed considerable measurement consistency.

To further assess agreement between both units in the measurement of sIgE, all the reported data were pooled and the

Table. Mean levels, SD, and Interlaboratory Coefficient of Variation (CV) for Specific Immunoglobulin E Measurements in kU_A/L and ng/mL

Allergen	kU _A /L			ng/mL		
	Mean	SD	CV	Mean	SD	CV
f1	57.4	14.3	25.0	189.3	49.3	26.0
	25.1	4.4	17.5	82.8	15.0	18.1
	1.6	0.3	19.4	5.3	1.2	23.0
	0.4	0.0	10.8	1.3	0.2	13.8
f2	92.7	12.0	13.0	285.8	65.9	23.1
	33.5	7.1	21.2	111.7	21.2	18.9
	5.6	0.9	15.4	18.6	1.9	10.3
	0.5	0.1	15.3	1.5	0.3	20.7
f3	63.6	7.2	11.3	200.2	24.3	12.2
	2.0	0.7	36.3	6.8	1.7	24.5
f13	68.1	11.5	16.8	223.6	46.5	20.8
	11.5	2.8	24.1	41.5	6.3	15.2
	1.6	0.6	39.9	5.4	1.6	30.8
	0.3	0.0	14.7	1.1	0.1	12.7
f24	1.8	0.2	9.6	5.7	0.5	9.0
	0.1	0.0	22.5	0.4	0.1	20.6
d1	71.3	8.0	11.2	225.1	27.9	12.4
	48.6	5.2	10.8	150.8	21.9	14.5
	17.8	2.4	13.4	56.1	11.9	21.2
	1.8	0.2	14.1	5.6	0.9	16.3
	0.1	0.0	12.3	0.4	0.1	29.9
e1	94.8	16.4	17.3	437.5	45.3	10.3
	45.4	5.1	11.2	148.0	18.6	12.5
	11.2	2.2	19.2	36.6	7.7	21.0
	0.7	0.0	6.6	2.1	0.2	9.5
e5	74.3	18.2	24.5	241.5	53.0	22.0
	42.7	5.3	12.3	138.9	22.0	15.9
	4.2	1.2	27.3	14.1	4.2	30.2
g6	55.8	5.8	10.3	180.1	23.7	13.2
	29.6	4.4	15.0	92.3	14.8	16.0
	6.6	0.9	13.4	22.3	3.9	17.6
	1.2	0.1	11.3	3.9	0.5	13.3
t9	30.6	4.3	14.0	99.5	12.4	12.4
	5.6	0.7	12.3	18.4	2.4	12.9
	3.6	0.4	11.8	10.8	1.3	12.0
w6	68.1	0.4	0.6	15.1	1.5	10.0
	0.4	0.0	11.7	1.1	0.1	10.1
w21	20.6	1.4	6.6	69.6	11.9	17.0
m6	38.3	10.2	26.6	128.8	37.3	29.0
	5.2	0.7	12.8	16.4	2.3	14.3
p4	93.8	19.6	20.9	293.5	68.0	23.2
	36.6	6.2	16.9	120.5	15.6	12.9
	6.3	0.7	10.8	21.2	1.9	8.8
	0.2	0.0	11.6	0.6	0.1	19.9
c2	5.0	0.4	7.2	15.8	2.4	15.5
	2.1	0.2	9.4	6.7	1.1	15.7
	0.8	0.0	4.7	2.6	0.2	8.6
	0.1	0.0	25.4	0.2	0.1	25.3
i1	46.5	9.2	19.8	151.6	33.2	21.9
	17.0	1.2	7.3	55.7	3.9	7.0
	2.3	0.2	10.6	7.7	0.9	12.1
	0.1	0.1	53.3	0.4	0.2	54.5

Abbreviation: CV, coefficient of variation.

CVs analyzed. The mean (SD) results were 129.8 (11.4) ng/mL (CV, 14.1%) and 11.5 (3.4) kU_A/L (CV, 15.1%). Furthermore, the expected mean kU_A/L result based on the curve in ng/mL and the conversion factor (1 kU_A/L=2.4 ng/mL) was very close to that indicated: 11.8 (3.4) kU_A/L. Finally, the average difference between samples measured in ng/mL and kU_A/L was 15.54% with an adjustment factor of 13.59% for each laboratory.

There are few methods available in clinical laboratories to quantify serum levels of sIgE. Despite this, however, results are inconsistent [3,4,6] and there is a clear lack of agreement between methods. Most systems report results in kU_A/L but with a very high variability. This means that it is not possible to compute a mean value against which to reliably compare results. Several reasons have been proposed to explain such poor agreement, including differences related to allergens (purification, preparation, etc) and test reagents (buffers, antibodies, etc). This poor agreement makes it difficult not only to compare results between laboratories but also to design multicenter clinical protocols. In other words, sIgE measurements cannot be used as valid endpoints.

This study shows good agreement between the use of ng/mL and kU_A/L units as a measurement of sIgE to a number of allergens at different concentrations using the ImmunoCAP 250 system, with no significant differences observed in precision when reporting in ng/mL or in kU_A/L, even at low levels of sIgE (<0.5 kU_A/L). With this platform, the variability observed in the kU_A/L assays was predictable from the variability obtained in mass unit assays by using the theoretical conversion factor (1 kU_A/L=2.4 ng/mL). Despite this good conversion from kU_A/L to ng/mL, it must be stressed that a high interlaboratory CV was observed for both units of measurement. Besides, the preparation of standards in ng/mL was based on the reassignment of standards prepared in kU_A/L. We are aware that an ideal comparison should be based on standards prepared either in kU_A/L or in ng/mL.

Finally, additional studies are needed to compare results obtained using other IgE measurement systems. The clinical relevance of measuring sIgE levels in mass units will be determined in clinical validation studies.

References

1. Hamilton RG, Williams PB. Human IgE antibody serology: a primer for the practicing North American allergist/immunologist. *J Allergy Clin Immunol*. 2010; 126: 33-38.
2. Li TM, Chuang T, Tse S, Hovanec-Burns D, El Shami AS. Development and validation of a third generation allergen-specific IgE assay on the continuous random access IMMULite 2000 analyzer. *Ann Clin Lab Sci*. 2004; 34: 67-74.
3. Wang J, Godbold JH, Sampson HA. Correlation of serum allergy (IgE) tests performed by different assay systems. *J Allergy Clin Immunol*. 2008 May;121(5):1219-24.
4. Wood RA, Segall N, Ahlstedt S, Williams PB. Accuracy of IgE antibody laboratory results. *Ann Allergy Asthma Immunol*. 2007 Jul;99(1):34-41.
5. García BE, Gamboa PM, Asturias JA, Lopez-Hoyos M, Sanz ML, Caballero MT, García JM, Labrador M, Lahoz C, Longo Areso

N, Martínez Quesada J, Mayorga L, Monteseirín FJ; Clinical Immunology Committee; Spanish Society of Allergology and Clinical Immunology. Guidelines on the clinical usefulness of determination of specific immunoglobulin E to foods. *J Investig Allergol Clin Immunol*. 2009; 19: 423-432.

6. Cox L, Williams B, Sicherer S, Oppenheimer J, Sher L, Hamilton R, Golden D; American College of Allergy, Asthma and Immunology Test Task Force; American Academy of Allergy, Asthma and Immunology Specific IgE Test Task Force. Pearls and pitfalls of allergy diagnostic testing: report from the American College of Allergy, Asthma and Immunology/American Academy of Allergy, Asthma and Immunology Specific IgE Test Task Force. *Ann Allergy Asthma Immunol*. 2008 Dec;101(6):580-92.
7. Bland JM, Altman DG. Statistical methods for assessing agreement between two methods of clinical measurement. *Lancet*. 1986; 1: 307-310.

■ *Manuscript received January 4, 2012; accepted for publication, February 16, 2012.*

Marcos López Hoyos

Servicio Inmunología
Hospital Universitario Marqués de Valdecilla
Avda. Valdecilla s/n
39008 Santander (SPAIN)
E-mail: mlopezhoyos@humv.es

Erythema and Hand Edema Due to Flavoxate

MC Moreno Escobosa, S Cruz Granados, MC Moya Quesada
Unidad de Alergia, Hospital Torrecárdenas, Almería, Spain

Key words: Antimuscarinic. Cross-reactivity. Flavoxate. Hypersensitivity. Urinary anticholinergic.

Palabras clave: Antimuscarínicos. Reactividad cruzada. Flavoxato. Hipersensibilidad. Anticolinérgicos urinarios.

Flavoxate hydrochloride is a urinary anticholinergic drug with antimuscarinic effects and a tertiary amine structure [1]. It is used to treat urinary frequency and retention due to neurogenic bladder, chronic prostatitis, and chronic cystitis. Acetylcholine is the primary contractile neurotransmitter in the human detrusor, and antimuscarinics exert their effects by inhibiting the binding of acetylcholine at muscarinic receptors M2 and M3 on detrusor smooth muscle cells and other structures within the bladder wall [2]. Flavoxate suppresses the overactive bladder by exerting a relaxant effect on the detrusor muscle and a central suppressive effect on the micturition reflex [3].

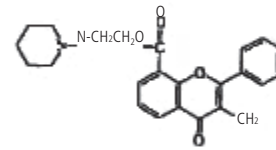
Antimuscarinics are generally well tolerated, even in special populations such as elderly patients and children. The most frequently reported adverse events in clinical studies are dry mouth, constipation, headache, and blurred vision.

A 26-year-old woman was referred to our allergy unit for evaluation of generalized, pruritic erythema and hand edema that had appeared 6 months earlier 5 hours after taking Monurol (fosfomicin) and Uronid (flavoxate hydrochloride) for a urinary infection. She was admitted to the emergency room and treated with methyl prednisolone and dexchlorpheniramine. She had no history of allergic disease.

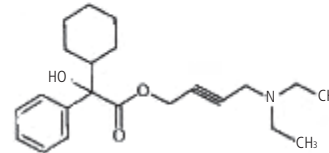
After obtaining informed consent, we performed skin prick tests, intradermal tests, and challenge tests to identify the offending drug.

Intradermal and challenge tests performed with fosfomicin were negative. A prick test with flavoxate (200 mg/mL) was also negative, leading us to propose a challenge test with the same drug. Intradermal tests were not performed with flavoxate because we were unable to find a parenteral preparation. For the challenge test, the patient took a cumulative dose of 200 mg; 1 hour after the last dose, she developed facial itching and light facial and hand erythema. She was treated with oral antihistamine and the symptoms disappeared, but 2 hours later, she developed itching, erythema, and hand edema. She received treatment with intramuscular corticosteroids and antihistamine and the symptoms disappeared in 2 hours.

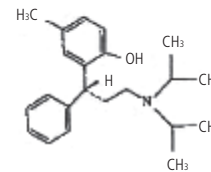
After discussing the need for alternative treatment, we investigated tolerance of other anticholinergic drugs used to treat urinary tract symptoms, namely, oxybutynin, tolterodine, and trospium (Figure). Prick tests performed with oxybutynin (5 mg/mL), tolterodine (2 mg/mL), and trospium (4 mg/mL) were all negative. Intradermal tests were not performed because we did not find parenteral preparations. Challenge tests were performed with oxybutynin and tolterodine, and were negative.



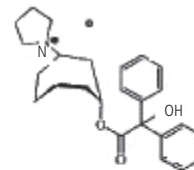
FLAVOXATE



OXYBUTYNIN



TOLTERODINE



TROSPIUM

Figure. Chemical structure of urinary anticholinergic drugs.

A challenge test was not performed with trospium because the patient decided to finish the study.

Flavoxate hydrochloride is associated with adverse effects such as gastrointestinal symptoms, sleepiness, and drug eruption [4]. Erythema and hand edema have not been reported to date, however, either for flavoxate hydrochloride or for the similar, well-known drugs, oxybutynin, tolterodine, and trospium.

Because the patient had recurrent urinary infections and cystitis, we decided to test tolerance of flavoxate, oxybutynin, and tolterodine. Because these 3 drugs are tertiary amines, it was decided to perform a challenge test due to the possibility of cross-reactivity. The negative results indicate the absence

of cross-reactivity in our patient, but our findings cannot be extrapolated to other patients. Trospium is a quaternary amine, so we believe that cross-reactivity between flavoxate and trospium would be very unlikely. However, we were unable to test this hypothesis as the patient refused to undergo a challenge test with this drug.

In our review of the literature, we found only 1 report of generalized drug eruption with fever and loss of appetite due to flavoxate hydrochloride [4]. Patch and oral challenge tests were positive and a cross-reactivity study was not carried out.

In conclusion, we have described a case of erythema and hand edema that appeared several hours after the patient took flavoxate. Although we were unable to demonstrate an IgE-mediated mechanism by prick testing, the positive challenge test indicates that a hypersensitivity mechanism might have been involved.

Challenge tests demonstrated the lack of cross-reactivity between flavoxate and both oxybutynin and tolterodine. We think that trospium, a quaternary amine, would probably have been tolerated without incidence, although we were not able to prove this by challenge testing.

More studies are needed to test cross-reactivity between oxybutynin, tolterodine, trospium, and flavoxate. To the best of our knowledge, this is the second case of hypersensitivity to flavoxate and the first case in which cross-reactivity has been studied.

References

1. Antimuscarínicos. In: Sweetman SC, editor. Martindale. Guía completa de consulta fármaco-terapéutica. Pharma Editores; 2003. p. 597-615.
2. Abrahams P, Andersson KE. Muscarinic receptor antagonists for overactive bladder. *BJU Int.* 2007 Nov; 100 (5): 987-1006.
3. Kimura Y, Sasaki Y, Hamada K, Fukui H, Ukai Y, Yoshikuri Y, Kimura K, Sugaya K, Nishizawa O. Mechanisms of the suppression of the bladder activity by flavoxate. *Int J Urol.* 1996; 2: 218-27.
4. Enomoto U, Ohnishi Y, Kimura M, Kawada A, Ishibashi A. Drug eruption due to flavoxate hydrochloride. *Contact Dermatitis.* 1999 Jun; 40(6): 337-8.

■ Manuscript received November 6, 2011; accepted for publication, February 22, 2012.

M. Carmen Moreno Escobosa
Unidad de Alergia
Hospital Torrecárdenas
Paraje Torrecárdenas, s/n
04009 Almería, Spain
E-mail: moreno.escobosa@terra.es

Food Protein-Induced Enterocolitis Syndrome (FPIES) to Corn: A Case Report

S Miceli Sopo, S Filoni, V Giorgio, S Monaco, R Onesimo
Department of Paediatrics, Università Cattolica del Sacro Cuore, Rome, Italy

Key words: Food protein-induced enterocolitis syndrome. Corn. Food allergy.

Palabras clave: Síndrome de enterocolitis inducida por proteínas alimentarias. Maíz. Alergia alimentaria.

E.S. started weaning at the age of 6 months. She ate pear homogenate (88% pear, a small amount of corn starch) and a diet consisting of vegetables, rice cream, and freeze-dried lamb (which contains a small amount of corn starch), without any evident problems. After 4 weeks, weaning was discontinued for 3 days because of a viral infection, and the infant was exclusively breastfed.

When she was 7 months old, she ate 4 teaspoons of vegetable, corn, and tapioca, and 2.5 hours later developed repeated episodes of diarrhea and vomiting with pallor, hypotonia, and lethargy. She was taken to the emergency department and after several hours was sent home in good clinical condition with a suspected diagnosis of acute viral gastrointestinal infection. Ten days later, she consumed breast milk followed by 80 g of pear homogenate (with corn starch), and developed profuse vomiting, diarrhea, pallor, and lethargy after 2 hours. She was admitted to hospital, where anaphylaxis due to cow's milk (CM) protein was suspected, although specific immunoglobulin (Ig) E was not investigated. CM was removed from the infant's and mother's diet. The infant was exclusively breastfed for 10 days, after which she ate 60 g of pear homogenate (still with corn starch). Four hours later, she experienced profuse vomiting, without pallor or lethargy. She was admitted to the emergency department and was examined, by chance, by a pediatrician with allergy expertise who suspected food protein-induced enterocolitis syndrome (FPIES) to corn, the only food present in all 3 critical episodes. She was discharged and prescribed a corn-free diet. CM was reintroduced into both the infant's and the mother's diet.

Prick to prick tests with corn and other grains not yet eaten by the infant (Kamut, wheat, buckwheat and spelt) were performed later and resulted negative. An oral food challenge (OFC) with a range of grains other than corn was also performed and no reactions were observed. Weaning onto age-appropriate food (except corn) was suggested. The infant consumed pear, lamb, vegetable with rice flour, grains other than corn, and cow's milk, and avoided all foods containing corn and its derivatives. She experienced no other episodes of FPIES with this diet. An OFC to test tolerance to corn was performed 1 year after the last episode, when the infant was 18-months-old, with negative results. At follow-up 2 months later, the child had eaten corn several times and experienced no further episodes of FPIES.

This is the first description of FPIES induced by corn.

It is very important to know all the foods that can induce this syndrome as knowledge is still lacking in this area [1]. Moreover, according to Caubet et al [2], diagnosis of FPIES is often delayed, especially when the syndrome is triggered by solid foods; this delay is attributed to a low index of suspicion and the presence of clinical features that overlap with those seen in other gastrointestinal disorders. In our case, diagnosis was delayed because of misdiagnosis: a gastrointestinal infection was suspected after the first reaction, and CM anaphylaxis after the second.

FPIES symptoms can occur after the first or second exposure to an offending food [3]. In our case, the patient ate food containing corn in small amounts (pear homogenate and freeze-dried lamb) for 2 weeks, without any evident problems. The first acute episode occurred when, after exclusive breastfeeding for 3 days, the infant was re-exposed to corn in larger quantities than before. It is possible that the 3-day corn-free diet played a key role in the development of acute FPIES after the reintroduction of corn. A similar pattern has been described for FPIES with a chronic onset, in which patients with intermittent chronic vomiting and diarrhea develop more violent and acute symptoms if they eat the trigger food after a period of trigger food-free diet [3,4]. This reaction has also been reported for cases of specific oral tolerance induction [5] and seems to suggest that removal of the offending food from a diet might be a destabilizing factor in a situation of unstable equilibrium. However, our patient did not present symptoms of chronic FPIES. Another important factor was probably the fact that the quantity of food that triggered the first episode was greater than quantities she had eaten previously.

In our case we did not perform a diagnostic OFC, but we complied with all the criteria established by Powell [4] and more recently confirmed [6,7]. An OFC to determine tolerance of corn was performed 1 year after the last episode, which is standard practice for IgE-mediated food allergies. There are no data in the literature about when an OFC should be performed in FPIES induced by solid foods; the only information available is that described for FPIES induced by CM [8,9].

Another interesting aspect of this case is that we did not advise the parents to exclude poultry or grains other than corn from the child's diet until the first year of life, or to replace common formula milk with hydrolyzed CM formula. These suggestions were proposed by Sicherer [10] since children with a history of FPIES to one type of grain seem to have a 50% chance of developing FPIES to other types of grains because of the "window of physiologic susceptibility" [7]. On the other hand, Caubet et al [3] claim that this is an unresolved issue, as it is not known whether children with FPIES to rice have an increased risk of FPIES to other grains, and the same probably

applies to FPIES to corn. We decided to perform OFCs with cereals other than corn before giving dietary prescriptions, and they all resulted negative.

In conclusion, this case shows that corn can cause FPIES. To the best of our knowledge, this is the first report of such a case. We still know little about the natural course of this syndrome and it would be desirable to have new reports of solid food FPIES to increase our knowledge in this area.

References

1. Fech-Bormann M, Winberg A, Rentzhog CH, Nordvall L. A pediatric lack of knowledge. FPIES--a non-IgE-mediated food allergy with dramatic symptoms. *Lakartidningen*. 2011;108:1767-9.
2. Caubet JC, Nowak-Węgrzyn A. Food protein-induced enterocolitis to hen's egg. *J Allergy Clin Immunol*. 2011; 128: 1386-8.
3. Caubet JC, Nowak-Węgrzyn A. Current understanding of the immune mechanisms of food protein-induced enterocolitis syndrome. *Expert Rev Clin Immunol*. 2011;7:317-27.
4. Powell GK. Food protein-induced enterocolitis of infancy: differential diagnosis and management. *Compr Ther*. 1986;12:28-37.
5. Rolinck-Werninghaus C, Staden U, Mehl A, Hamelmann E, Beyer K, Niggemann B. Specific oral tolerance induction with food in children: transient or persistent effect on food allergy? *Allergy*. 2005; 60:1320-2.
6. Nowak-Węgrzyn A, Sampson HA, Wood RA, Sicherer SH. Food protein induced enterocolitis syndrome caused by solid food proteins. *Pediatrics*. 2003;111:829-35.
7. Leonard SA, Nowak-Węgrzyn A. Food protein-induced enterocolitis syndrome: an update on natural history and review of management. *Ann Allergy Asthma Immunol*. 2011; 107:95-101.

■ *Manuscript received January 23, 2012; accepted for publication, February 23, 2012.*

Stefano Miceli Sopo

Department of Pediatrics, Università
Cattolica del Sacro Cuore
L.go A. Gemelli 8
00168 Roma, Italy
E-mail: smicelisopo@rm.unicatt.it