

Desensitization for Insulin Allergy: A Useful Treatment Also for Local Forms

I Eguíluz-Gracia,¹ M Rodríguez-Álvarez,¹ M Cimarra-Álvarez,¹ MC Sanabria-Pérez,² C Martínez-Cócer¹

¹Allergy Department, Hospital Clínico San Carlos, Madrid, Spain

²Endocrinology and Nutrition Department, Hospital Clínico San Carlos, Madrid, Spain

Key words: Drug allergy. Desensitization. Insulin.

Palabras clave: Alergia a medicamentos. Desensibilización. Insulina.

Insulin allergy is now a rare condition thanks to the introduction of human recombinant proteins in the 1980s. As a high-molecular-weight protein, insulin induces mainly type I hypersensitivity reactions, which can range from local erythema to anaphylaxis. Desensitization is the treatment of choice for systemic reactions in patients who require insulin and many authors recommend symptomatic treatment for local reactions [1]. Local forms of insulin allergy, however, can progress to systemic forms [2], and there has even been a report of fatal anaphylaxis in a patient who had previously experienced only local reactions [3].

We report the case of a 62-year old man who, in 2003, was diagnosed with type 2 diabetes mellitus, which was controlled with oral treatment for 7 years. In 2010, during admission to hospital due to hyperglycemic decompensation, he received intravenous insulin, which he tolerated well. On discharge, it was decided to initiate subcutaneous administration of insulin aspart plus protamine (12 units-0-12 units). Immediately after receiving the first dose, the patient developed a pruritic, erythematous nodule (5 cm diameter) that lasted for 48 hours. Treatment was changed to insulin glargine (12 units-0-12 units) and insulin detemir (14 units-0-14 units), but the lesion returned. Insulin was replaced by oral treatment and the patient was referred to our outpatient clinic.

Skin prick tests (SPTs) performed with all available insulin preparations in Spain, including insulin lispro [3,4], were positive in all cases. Specific immunoglobulin (Ig) E for insulin was 14.8 kUA/L (ImmunoCap Phadia). SPTs with latex and protamine were both negative. Patch tests with insulin aspart plus protamine, insulin detemir, insulin glargine, latex and zinc were all negative at 48 and 96 hours. A diagnosis of type I hypersensitivity to insulin was established.

A target dose of 6 units of subcutaneous insulin a day was established by an endocrinologist in accordance with the patient's insulin needs. We started by administering simultaneous fractionated doses (2 by 2) of the total target

Table. Desensitization Protocol

Day	Dose No.	Units/dose	Cumulative dose/d, units	Tolerated
1	1	0.0001	0.0001	Yes
1	2	0.001	0.0011	Yes
1	3	0.01	0.0111	Yes
1	4	0.1	0.1111	Yes
1	5	1	1.1111	Yes
1	6	2	3.1111	No
2	7	1	1	Yes
2	8	2	3	Yes
2	9	4	7	Yes
3	10	6 ^a	6	Yes

^aTwo simultaneous doses of 3 units.

dose in different parts of the body, but the patient developed immediate local induration and erythema, despite pretreatment with ebastine 20 mg and prednisone 60 mg. It was therefore decided to design a desensitization protocol to improve tolerance (Table 1). Each day, the patient took ebastine 20 mg and prednisone 60 mg thirty minutes before starting the procedure. Blood glucose levels were closely monitored by the endocrinologist throughout the desensitization protocol. On the first day, we administered 6 consecutive subcutaneous doses of regular insulin every 20 minutes. The first 5 doses (cumulative dose of <1.2 units) were all well tolerated, but the patient developed a local wheal immediately after the sixth dose (2 units). The procedure was stopped. On the following day, 3 consecutive doses of 1, 2, and 4 units at 20-minute intervals were administered and tolerated. On the third day, we reached the target dose of 6 units per day with simultaneous injections of 3 units at 2 different sites. No lesions were observed. Dosing of prednisone was initiated (with withdrawal of the drug after 3 days). The patient continued to take ebastine 20 mg and 6 units of insulin glargine (2 simultaneous injections of 3 units) every day. No relevant increases in blood glucose levels were observed during the procedure. There were 2 mild decreases (80 mg/dL) but these were easily controlled by the intake of fruit juice. After 3 months of follow-up, the patient continues to follow the same treatment regimen and has experienced no further symptoms.

As has been reported previously in both adults [5] and children [6], desensitization can improve tolerance to insulin in local hypersensitivity. Using the desensitization protocol described in this report, we improved patient comfort and reduced the risk of chronic skin lesions. It appears to be well established that a previous local reaction is the main risk factor for systemic reactions in the future [1]. Desensitization not only improves patient comfort, but might also help to prevent future episodes of anaphylaxis.

Acknowledgments

We thank nurses María Ángeles Gil-García and Prado Lucendo-Abarca for their help during the procedure.

References

1. Messadd D, Outtas O, Demoly P. Hypersensitivity to insulin. *Prese Med.* 2004; 33(9 Pt 1):631-8
2. Heinzerling L, Raile K, Rochlitz H, Zuberbier T, Worm M. Insulin allergy: clinical manifestations and management strategies. *Allergy.* 2008; 63(2):148-55.
3. Kaya A, Gungar K, Karakose S. Severe anaphylactic reaction to human insulin in a diabetic patient. *J Diabetes Complications.* 2007. 21(2):124-7.
4. Pánczél P, Hosszúfalusi N, Horváth MM, Horváth A. Advantage of insulin lispro in suspected insulin allergy. *Allergy.* 2000; 55(4):409-10
5. Lluch-Bernal M, Fernández M, Herrera-Pombo JL, Sastre J. Insulin lispro, an alternative in insulin hypersensitivity. *Allergy.* 1999; 54(2):186-7
6. Moyes V, Driver R, Croom A, Mirakian R, Chowdhury TA. Insulin allergy in a patient with type II diabetes successfully treated with continuous insulin infusion. *Diabet Med.* 2006. 23 (2): 204-6
7. Eapen SS, Conner EL, Gern JE. Insulin desensitization with insulin lispro and a insulin pump in a 5-year-old child. *Ann Allergy Asthma Immunol.* 2000. 85(5):395-7

■ Manuscript received June 20, 2011; accepted for publication, October 4, 2011.

I Eguíluz-Gracia

Hospital Clínico San Carlos
Calle Profesor Martín Lagos s/n
28040, Madrid, Spain
E-mail: kemenda@hotmail.com(8)

A Case of Cimetidine-Induced Immediate Hypersensitivity

HJ Cho, HS Yoo, SY Park, EM Yang, MG Yoon, HS Park, YM Ye

Department of Allergy and Clinical Immunology, Ajou University School of Medicine, Suwon, South Korea

Key words: Cimetidine. Immediate hypersensitivity. Basophils.
Palabras clave: Cimetidina. Hipersensibilidad inmediata. Basófilos.

Histamine receptor 2 (H₂) blockers such as cimetidine, famotidine, and ranitidine are mainly used for the treatment of disorders related to gastric acid hypersecretion [1]. A number of hypersensitivity reactions to H₂ antagonists, mostly demonstrated by oral provocation and skin tests, have been reported [2,3]. Basophil activation testing (BAT) was recently used for the in vitro diagnosis of immunoglobulin (Ig) E-mediated drug allergy [4]. To our knowledge, our case report is the first to describe cimetidine-induced acute urticaria and angioedema confirmed by both intradermal tests and BAT.

A 34-year-old female presented with angioedema and generalized urticaria 1 hour after intravenous administration of cimetidine 200 mg. Her medical and family history was unremarkable. About 1 month later, skin tests with cimetidine, ranitidine, and famotidine were performed. The skin prick tests were all negative, but intradermal tests performed at dilutions of 0.1, 1, and 10 mg/mL were positive for cimetidine and ranitidine at the 10-mg/mL concentration. The results for famotidine were negative. Intradermal tests in 5 nonatopic, healthy controls yielded negative results for 10mg/mL of cimetidine.

No specific IgE to cimetidine or ranitidine was detected in the patient's sera by enzyme-linked immunosorbent assay (ELISA). CD203c and CD63 expression on blood basophils of the patient was determined by flow cytometry at the time of reaction and during the convalescence phase. CD203c and CD63 expression levels were both increased on the day of cimetidine administration (71.5% and 28.9%, respectively) compared to during convalescence (43.7% and 7.8%, respectively). Following incubation of the basophils with cimetidine at dilutions of 10⁻⁵, 10⁻³, 10⁻¹, 1, 10 mg/mL for 30 minutes, CD203c expression decreased in a dose-dependent manner (Figure). There was no significant difference in CD203c expression on the basophils of a healthy volunteer before and after cimetidine administration (35.7% vs 37.0%).

After obtaining informed consent, we performed an open-label oral challenge with cimetidine and famotidine. An hour and a half after ingestion of cimetidine 200 mg, the patient developed angioedema on the face and urticaria on the neck and on the arms and legs. The oral challenge with famotidine was negative.

H₂ antagonists are generally well tolerated and adverse reactions are rare [1]. Although the use of these drugs is rarely

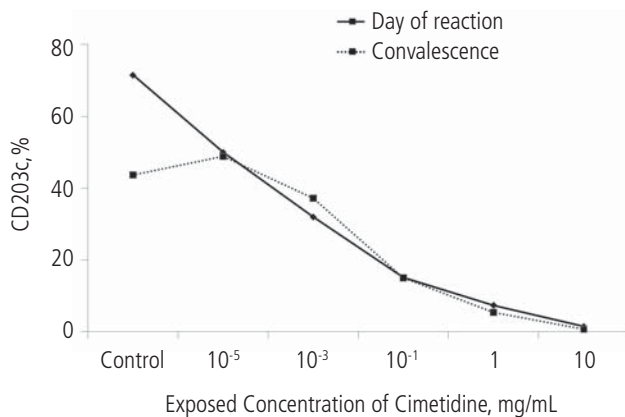


Figure. Basophil activation test results. Peripheral blood basophils from the patient were incubated with cimetidine at dilutions of 10^{-5} , 10^{-3} , 10^{-1} , 1, and 10 mg/ml. CD203c expression was increased on the day of reaction (71.5%) compared to during convalescence (43.7%). Expression levels, however, decreased in a dose-dependent manner after incubation of basophils with cimetidine.

associated with hypersensitivity reactions, there have been reports of asthma and rhinitis, urticaria, anaphylaxis and even toxic epidermal necrolysis and acute generalized exanthematous pustulosis [5]. However, as a strong inhibitor of the cytochrome P450, cimetidine, rather than inducing hypersensitivity reactions, generally gives rise to drug interactions.

In our case, we confirmed cimetidine-induced acute urticaria and angioedema by an oral challenge test. Possible cross-reactivity with ranitidine was suggested by the intradermal tests results, but no cross-reactivity was noted for famotidine. To elucidate the mechanism of immediate hypersensitivity reactions to cimetidine, we performed *in vitro* tests, including ELISA, to detect specific IgE antibodies and basophil surface expression of CD203c and CD63. Specific IgE to cimetidine was not identified in the sera of the patient. Moreover, cimetidine decreased basophil activation in the patient. Skin keratinocytes expressing cytochrome P450 enzymes are involved in drug metabolism [6], possibly explaining why intradermal testing with cimetidine was positive in the absence of serum specific IgE to cimetidine. Cimetidine metabolites thus, rather than cimetidine itself, might have been responsible for the allergic reaction in our patient. Ranitidine, nizatidine and famotidine, but not cimetidine, share similar side chains on the ring structures. This could explain why cross-reactivity between cimetidine and other H₂ antagonists is rarely seen [5]. A recent study reported a case of cimetidine-induced anaphylaxis with possible cross-reactivity between ranitidine and famotidine based on skin test results [2]. Considering that the sulfoxide is a metabolite of both cimetidine and ranitidine [7], it is possible that a cross-reaction occurred between metabolites common to the 2 drugs rather than between cimetidine and ranitidine

themselves. An oral challenge with ranitidine and testing of the metabolites of the 2 drugs by skin tests and BAT could provide more information to confirm our suspicion of cross-reactivity between cimetidine and ranitidine in our patient.

While the challenge test is the gold standard for diagnosing allergy, it has limitations in patients with a history of anaphylaxis or with severe comorbid disorders. Because the relevant immunogen, including intermediate metabolites, is unknown in most drugs [8], the predictive value of skin testing and other methods for detecting specific IgE to H₂ antagonists remains uncertain. We were unable to identify specific IgE to cimetidine in our patient using the protocol described in a previous report that demonstrated serum specific IgE in a patient with H₂ blocker-induced anaphylaxis [9].

CD203c is a useful marker for flow cytometric analysis of increased basophil surface expression in response to IgE-dependent stimuli [4]. It has been proven that BAT has high specificity and moderate sensitivity for diagnosing allergy to certain drugs such as β -lactam antibiotics, neuromuscular blocking agents, and clavulanic acid [4].

Considering that the incubation of the patient's basophils with cimetidine resulted in a gradual decrease in CD203c expression in the case reported, it can be postulated that H₂, like H₁ antagonists, may suppress basophil activation. This hypothesis is consistent with a previous report that demonstrated that H₂ antagonists potentiated the effects of H₁ antihistamines in suppressing histamine-induced wheals [10]. Therefore, conventional BAT, which involves incubating allergens with basophils, cannot be applied to the diagnosis of H₂ antagonist-induced hypersensitivity due to the inhibitory effect of these allergens on basophil activation. By contrast, investigating CD203c and CD63 expression on basophils at the time of the reaction would be a relatively safe and useful means of confirming IgE-mediated hypersensitivity *in vitro*.

In conclusion, our patient developed urticaria and angioedema following the administration of cimetidine. Based on a positive intradermal test to cimetidine and increased CD203c and CD63 expression levels on basophils on the day of the reaction, we suggest the involvement of an IgE-mediated mechanism.

Acknowledgments

This research was supported by a grant (09182KFDA847) from Korea Food & Drug Administration in 2011.

References

1. Brimblecombe RW, Duncan WAM, Durant GJ, Ganellin CR, Parsons ME, Black JW. The pharmacology of cimetidine, a new histamine H₂-receptor antagonist. *British Journal of Pharmacology*. 2010;160:S52-3.
2. Song W-J, Kim M-H, Lee S-M, Kwon Y-E, Kim S-H, Cho S-H, Min K-U, Kim Y-Y, Chang Y-S. Two Cases of H₂-Receptor Antagonist Hypersensitivity and Cross-Reactivity. *Allergy, Asthma and Immunology Research*. 2011;3:128-31.
3. Whalen JP. Hypersensitivity to cimetidine. *J Clin Pharmacol*. 1985;25:610.

4. Sanz ML, Gamboa PM, Mayorga C. Basophil activation tests in the evaluation of immediate drug hypersensitivity. *Curr Opin Allergy Clin Immunol*. 2009;9:298-304.
5. Kim YI, Park CK, Park DJ, Wi JO, Han ER, Koh YI. A case of famotidine-induced anaphylaxis. *J Invest Allergol Clin Immunol*. 2010;20:166-9.
6. Baron JM, Holler D, Schiffer R, Frankenberg S, Neis M, Merk HF, Jugert FK. Expression of multiple cytochrome p450 enzymes and multidrug resistance-associated transport proteins in human skin keratinocytes. *J Invest Dermatol*. 2001;116:541-8.
7. Burks TF. Drugs affecting gastrointestinal function. In: Munson PL, Mueller RA, Breese GR, editors. *Principles of pharmacology: basic concepts and clinical applications*. New York: Chapman & Hall; 1996. p1064-7.
8. Romano A, Torres MJ, Castells M, Sanz ML, Blanca M. Diagnosis and management of drug hypersensitivity reactions. *Journal of Allergy and Clinical Immunology*. 2011;127:S67-73.
9. YI K, HS P, IS C. Ranitidine-induced anaphylaxis: detection of serum specific IgE antibody. *Allergy*. 2006;61:269-70.
10. Dhanya NB, Rai R., Srinivas CR. Histamine 2 blocker potentiates the effects of histamine 1 blocker in suppressing histamine-induced wheal. *Indian J Dermatol Venereol Leprol*. 2008;74(5):475-7.

■ Manuscript received July 19, 2011; accepted for publication, October 13, 2011.

Young-Min Ye

Department of Allergy and Clinical Immunology
Ajou University School of Medicine,
San 5, Wonchun-dong, Yeongtong-gu
Suwon, Korea 443-721
E-mail: ye9007@ajou.ac.kr

Selective Nonimmediate Reaction to Ampicillin

L Sánchez-Morillas,¹ P Rojas Pérez-Ezquerro,¹ M Reaño-Martos,² R González-Mendiola,¹ C Mayorga,³ JJ Laguna Martínez¹

¹Allergology Department, Hospital Central de la Cruz Roja, Madrid, Spain

²Allergology Department, Hospital Universitario Puerta de Hierro Majadahonda, Madrid, Spain

³Allergology Department, Hospital Carlos Haya-Fundación IMABIS, Málaga, Spain

Key words: Aminopenicillins. Ampicillin. Delayed reaction. Cross-reactivity.

Palabras clave: Aminopenicilinas. Ampicilina. Reacción no inmediata. Reactividad cruzada.

Penicillins are the most frequently implicated drugs in immunologic adverse reactions such as immunoglobulin (Ig) E-mediated immediate reactions, maculopapular exanthema, erythema multiforme, and fixed drug eruptions [1].

Ampicillin has been widely used since it was introduced in 1961. Reported reactions include exanthema, desquamative contact eczema, urticaria, and anaphylaxis [2,3].

Reactions attributed to T cell-dependent responses vary from mild reactions, such as exanthema or delayed urticaria, to more severe reactions such as Stevens-Johnson syndrome or toxic epidermal necrolysis [4]. The most common type is exanthema (occurring in 25% of all cases with skin manifestations), followed to a lesser extent by urticaria [3].

A 42-year-old man with no history of atopy or allergy fainted after injection of intramuscular penicillin for the treatment of an infection. The patient did not remember the penicillin involved. We have no further details of this episode.

Prick and intradermal test results with benzylpenicilloyl polylysine as the major determinant (0.04 mg/mL) and minor determinant mixture (0.5 mg/mL) were negative. Both major and minor determinants were purchased from Diater SA. Skin test results with benzylpenicillin 10 000 IU/mL (Normon SA), amoxicillin 20 mg/ml (GlaxoSmithKline SA), ampicillin 20 mg/mL (Normon SA), cloxacillin 20 mg/mL (Normon SA), cefuroxime 2 mg/mL (GlaxoSmithKline SA), and ceftazidime 2 mg/mL (Combino Pharm SL) were all negative. Specific IgE antibodies to penicillin V, penicillin G, amoxicillin, and ampicillin (CAP-FEIA, Phadia) were also negative. Patch testing was performed on the patient's upper back with penicillin, amoxicillin, and ampicillin (all at a concentration of 5% in petrolatum). Patch tests were read at 48 and 96 hours, and the results were negative. A lymphoblastic transformation test with penicillin, amoxicillin, and ampicillin at 250 and 50 µg/mL also gave negative results.

After obtaining the patient's informed consent, we performed a single-blind oral challenge with phenoxymethylpenicillin (125, 250, and 500 mg), amoxicillin (125, 250, and 500 mg),

cloxacillin (125, 250, and 500 mg), and ampicillin (125, 250, and 500 mg), increasing doses at 1-hour intervals. To rule out a nonimmediate reaction, the therapeutic dose was subsequently taken at home every 8 hours for 3 days. An oral challenge with phenoxymethylpenicillin, amoxicillin, and cloxacillin was negative. The result of a single-blind oral challenge with ampicillin was positive, with a delayed reaction. Twenty-four hours after the challenge (cumulative dose of 1875 mg), a pruritic maculopapular rash was observed on the trunk and arms. The symptoms subsided in 48 hours with systemic antihistamines and corticosteroids.

As the patient had experienced the reaction more than 2 years earlier, and according to the recommendations set out in the position paper of the European Network for Drug Allergy [5], the skin tests were repeated after 4 weeks. The results were again negative. Due to the difference between the findings of the allergy workup and the history as reported by the patient, we decided to repeat the oral challenge to confirm that ampicillin had caused the reaction. The result of the second oral challenge with ampicillin was also positive. Twenty-four hours after the challenge, the patient developed the same symptoms as after the first challenge.

Maculopapular or morbilliform rashes are common during treatment with β -lactams, particularly ampicillin [6]. These rashes usually appear at least 2 to 3 days after the drug has been started, are not associated with IgE antibodies, and do not appear to predispose the patient to urticarial reactions. Over the last decade, however, various investigators have come to the conclusion that these rashes often represent type IV (cell-mediated) hypersensitivity, which is associated with patch test and/or delayed intradermal test positivity [6].

In nonimmediate reactions, patch and/or intradermal tests have been proposed for in vivo diagnosis. Although the lymphocyte transformation test has also been proposed for diagnostic purposes, its role has not been defined [4]. In a prospective study of nonimmediate reactions, Padial et al [4] found that only 9% of individuals had a positive intradermal test result. We performed both intradermal and patch tests and a lymphocyte transformation test, and the results were negative for all three. A drug challenge was necessary to establish the diagnosis.

Studies carried out with monoclonal antibodies [7] and polyclonal antibodies [8,9] in animals have shown that ampicillin can induce an immunological response linked to its side chain structure. In humans, there is not sufficient evidence to prove that ampicillin is able to induce a specific response. Experimental studies indicate that the side chain of ampicillin may generate unique epitopes and that low cross-reactivity with amoxicillin exists [2]. In our case, the patient was sensitized to ampicillin and tolerated amoxicillin; therefore, he may be sensitized to the specific epitopes to this drug. In addition, immunologic specificity was demonstrated by the fact that the patient tolerated oral phenoxymethylpenicillin, a molecule that differs from ampicillin only in that it lacks an amino group on the benzene ring.

In summary, we report a patient with a selective nonimmediate reaction to ampicillin with good tolerance to amoxicillin and phenoxymethylpenicillin. The diagnosis was confirmed using a positive single-blind oral challenge.

Acknowledgments

This work was supported by grants from the Spanish Health Ministry (FIS) network RIRAAF (RD07/0064).

References

1. Sánchez-Morillas L, Laguna-Martínez JJ, Reaño-Martos M, Gómez-Tembleque P, Rojo Andrés E. Fixed drug eruption caused by amoxicillin-clavulanic. *Ann Allergy Asthma Immunol.* 2008; 101(3): 335.
2. Romano A, Torres MJ, Fernández J, Vega JM, Mayorga C, García J, Blanca M. Allergic reactions to ampicillin. Studies on the specificity and selectivity in subjects with immediate reactions. *Clin Exp Allergy.* 1997; 27: 1425-31.
3. López S, Blanca-López N, Cornejo-García JA, Torres MJ, Mayorga C, Blanca M. Nonimmediate reactions to betalactams. *Curr Opin Allergy Clin Immunol.* 2007; 7(4): 310-6.
4. Padial A, Antunez C, Blanca-López N, Fernández TD, Cornejo-García JA, Mayorga C, Torres MJ, Blanca M. Non-immediate reactions to beta-lactams: diagnostic value of skin testing and drug provocation test. *Clin Exp Allergy.* 2008; 38(5): 822-8.
5. Torres MJ, Blanca M, Fernández J, Romano A, Weck A, Aberer W, Brockow K, Pichler WJ, Demoly P. Diagnosis of immediate allergic reactions to beta-lactams antibiotics. *Allergy.* 2003; 58: 961-72.
6. Romano A, Quarantino D, Papa G, Di Fonso M, Venuti A. Aminopenicillin allergy. *Arch Dis Child.* 1997; 76: 513-7.
7. Nagakura N, Souma S, Shimizu T, Yanaguiara Y. Anti-ampicillin monoclonal antibodies and their cross-reactivities to various betalactams. *J Anti Chemothe.* 1991; 28: 357-68.
8. Nishida K, Kinoshita Y, Atsumi T, Shibata K, Horihuchi Y. The analysis of combining sites of rabbit antipenicilloyl antibodies. *Immunochemistry.* 1972; 9: 1195-202.
9. Bondaruk J, Curcio-Vonlanthen V, Schneider CH. Basic aspects related to penicillin-allergy skin testing: on the variability of the hapten-paratope interaction. *Allergy.* 1995; 50: 671-6.

■ *Manuscript received July 27, 2011; accepted for publication, October 13, 2011.*

Leticia Sánchez Morillas

Servicio de Alergia. Hospital Central de la
Cruz Roja.
Reina Victoria 22
28003 Madrid
Spain
E-mail: lsanchezmorillas@hotmail.com

Lymphoid Tissue Histology in a Patient With ICF Syndrome

B Makay,¹ Ö Anal,¹ G Köse,¹ Ö Bozkaya,² E Özer,³ E Bora,² A Ülgenalp,² D Erçal²

¹Department of Pediatrics, Division of Immunology-Rheumatology, Dokuz Eylül University Hospital, Balçova-Izmir, Turkey

²Department of Pediatrics, Division of Genetics, Dokuz Eylül University Hospital, Balçova-Izmir, Turkey

³Department of Pathology, Dokuz Eylül University Hospital, Balçova-Izmir, Turkey

Key words: ICF syndrome. Lymphoid histology.

Palabras clave: Síndrome ICF. Histología linfóide.

The immunodeficiency, centromeric instability, and facial anomalies (ICF) syndrome is an inherited immunodeficiency syndrome characterized by a variable degree of mental and motor retardation and dysmorphic facial features [1,2]. Mutations in the DNA methyltransferase 3B gene (*DNMT3B*) are responsible for the majority of ICF cases reported to date [3]. These mutations cause instability in the juxtacentromeric heterochromatin regions of chromosomes 1 and 16, and, sometimes chromosome 9 [4,5]. Clinical features of the ICF syndrome include unusual facial features such as hypertelorism, flat nasal bridge, and macroglossia, mental retardation, intestinal dysfunction, psychomotor impairment, and delayed developmental milestones [6].

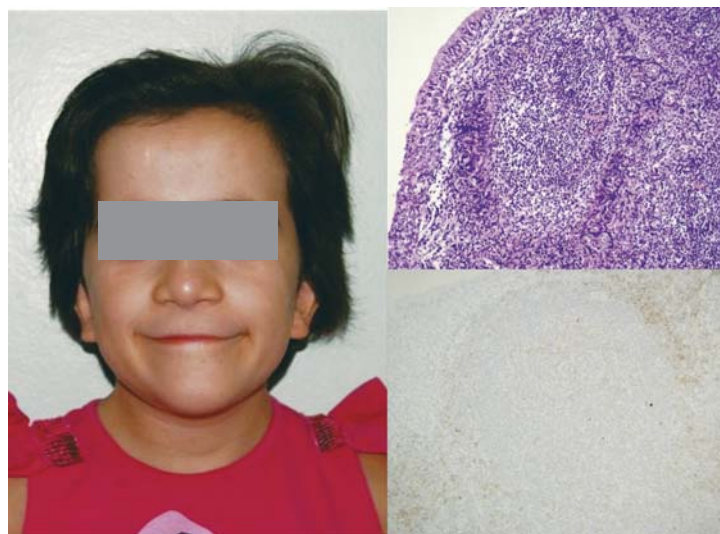


Figure. Note the atypical facies of the patient on the left. Primary follicle under the mucosal layer with inconspicuous germinal center (hematoxylin-eosin staining, original magnification $\times 20$) in the top right corner. Small number of CD 20⁺ lymphocytes outside the germinal centers (CD20 staining, original magnification $\times 20$) in the bottom right corner.

Immunodeficiency in ICF ranges from severe agammaglobulinemia to a mild reduction in immune response, although B cells are present in sufficient numbers in peripheral blood [6]. The aim of this paper was to demonstrate the immune histology of lymphoid tissue from an ICF patient who had undergone adenotonsillectomy.

A 5-year-old girl was referred to the pediatric immunology department of our hospital because of recurrent infections. She was the first child of nonconsanguineous parents. She had had recurrent acute otitis media and sinusitis since 3 months of age and also had recurrent conjunctivitis. Her developmental milestones were normal and her family history unremarkable.

On physical examination, she was 14.5 kg in weight (25th percentile) and 100 cm (3rd-10th percentile) in height. Her face was dysmorphic, with hypertelorism, flat nasal bridge, low-set ears, high forehead, and macroglossia. Her tonsils were hypertrophic. She had uvula bifidus and a high-arched palate with mandibular prognathism (Figure). The tympanic membranes were bilaterally perforated. She had mild thoracic scoliosis and joint laxity with cubitus valgus. The remainder of the examination was unremarkable.

Laboratory examinations revealed normal leukocyte, erythrocyte, and platelet counts, and immunological studies revealed panhypogammaglobulinemia. Serum immunoglobulin (Ig) G was 42.1 mg/dL (reference range, 345-1236 mg/dL), IgA was <6.6 mg/dL (reference range, 14-159 mg/dL), and IgM was 17 mg/dL (reference range, 43-207 mg/dL). The thymus was visible on chest X-ray. Total serum protein and albumin levels were normal and there was no proteinuria. Repeated serum immunoglobulin levels were all below the lower limit of normal. Anti-rubeola IgG was negative. Natural isoheamagglutinins (anti-A and anti-B) were negative. The percentage and number of peripheral blood B cells were normal for her age (21.5 % and $0.37 \times 10^9/L$, respectively.)

The atypical facies and hypogammaglobulinemia in association with normal B cell numbers suggested ICF syndrome. The centromeric instability of chromosomes 1, 9, and 16, shown by standard cytogenetic analysis, confirmed the diagnosis. The patient was started on monthly intravenous immunoglobulin (IVIg) therapy. The frequency and duration of the infections decreased. However, adenotonsillar hypertrophy causing upper airway obstruction required surgical intervention. One year after the start of IVIg therapy, she underwent adenotonsillectomy.

The histopathological examination of the adenoid and tonsillary tissue revealed preserved general architecture. Primary follicles were seen under the mucosal layer but germinal centers were inconspicuous (Figure). CD20⁺ lymphocytes were scarce outside the germinal centers (Figure) and CD3⁺ lymphocytes were condensed in the paracortical area. Immunofluorescence staining revealed numerous IgM⁺ cells, but very few IgA⁺ and IgG⁺ cells.

ICF has been described in fewer than 50 patients worldwide since it was first described in 1978 [7]. Among the main features of the disease are hypogammaglobulinemia and agammaglobulinemia. In one study, 27 out of 44 patients had agammaglobulinemia, although they had B cells in the peripheral blood [6]. Recently, Blanco-

Betancourt et al [8] investigated B-cell defects in this syndrome and showed that peripheral blood contained only naïve B cells and that there was a deficiency of memory and gut plasma cells. This suggested that negative selection breakdown and peripheral B-cell maturation blockage might contribute to agammaglobulinemia in ICF. Immune responses usually take place in secondary lymphoid organs such as lymph nodes, and most lymphocytes within these organs are transitory. T cells and B cells segregate into separate regions. B-cell compartments include naïve cells within follicles and marginal zones, with the formation of germinal centers and plasma cells when B cells respond to antigens [9]. The poorly formed germinal centers in the present case confirmed that the B cells had a low response to antigens. The scarcity of CD20⁺ cells was consistent with this finding. A dense CD3⁺ T cell population was shown in the paracortical area. Although the patient had a normal B-cell count in peripheral blood, there were few B cells in the lymphoid tissue. Interestingly, although serum levels of IgA, IgG, and IgM were low, immunofluorescence staining revealed large numbers of IgM⁺ cells but very few IgA⁺ and IgG⁺ cells. IgM-bearing B cells are formed in the bone marrow. When activated by helper T cell signals (CD40L, cytokines), B cells undergo switching to different Ig isotypes in peripheral lymphoid tissues [10]. The presence of IgM⁺ cells accompanied by a virtual absence of IgA⁺ and IgG⁺ cells may suggest deficient isotype switching.

Blanco-Betancourt et al [8] showed that ICF B cells are competent for class switch recombination and immunoglobulin secretion after in vitro stimulation by CD40L in the presence of cytokines. Our findings suggest that ICF patients, or at least ICF patients like ours, may have a defect in the activation of B cells by helper T cell signals. Our patient had a normal percentage of T cells, including CD4⁺ helper cells. Unfortunately, we were unable to study T-cell functions. In a meta-analysis of 45 ICF patients, Hagleitner et al [6] reported that of 28 patients who underwent T-cell function testing, 3 showed decreased or absent proliferation of T cells following stimulation with the mitogen phytohemagglutinin.

In conclusion, the histological findings of the lymphoid tissue in the present case, with poorly formed germinal centers and significant changes in lymphoid cell composition and B-cell immunoglobulin expression, may help to explain the mechanisms of immunodeficiency in the ICF syndrome.

References

- Howard PY, Lewis YJ, Haris F, Walker S. Centromeric instability of chromosomes 1 and 16 with variable immune deficiency: a new syndrome. *Clin Genet.* 1985; 27: 501-505.
- Franceschini P, Martino S, Ciocchini M, Ciuti E, Vardeu MP, Guala A, Signorile F, Camerano P, Franceschini D, Tovo PA. Variability of clinical and immunological phenotype in immunodeficiency-centromeric instability-facial anomalies syndrome: report of two new patients and review of the literature. *Europ J Pediat.* 1995; 154: 840-846.
- Hansen RS, Wijmenga C, Luo P, Stanek AM, Canfield TK, Weemaes CM, Gartler SM. The DNMT3B DNA methyltransferase gene is mutated in the ICF immunodeficiency syndrome. *Proc Natl Acad Scis* 1999; 96:14412-7.
- Valkova G, Ghenev E, Tzancheva M. Centromeric instability of chromosomes 1, 9 and 16 with variable immune deficiency: support of a new syndrome. *Clin Genet.* 1987; 31: 119-124.
- Sumner AT, Mitchell AR, Ellis PM. A FISH study of chromosome fusion in the ICF syndrome: involvement of paracentric heterochromatin but not of the centromeres themselves. *J Med Genet.* 1998; 35: 833-835.
- Hagleitner MM, Lankester A, Maraschio P, Hultén M, Fryns JP, Schuetz C, Gimelli G, Davies EG, Gennery A, Belohradsky BH, de Groot R, Gerritsen EJ, Mattina T, Howard PJ, Fasth A, Reisli I, Furthner D, Slatter MA, Cant AJ, Cazzola G, van Dijken PJ, van Deuren M, de Greef JC, van der Maarel SM, Weemaes CM. Clinical spectrum of immunodeficiency, centromeric instability and facial dysmorphism (ICF syndrome). *J Med Genet.* 2008; 45:93-9.
- Tiepolo L, Maraschio P, Gimelli G, Cuocco C, Gargani GF, Romano C. Multibranching chromosomes 1, 9 and 16 in a patient with combined IgA and IgE deficiency. *Hum Genet.* 1979; 51: 127-137.
- Blanco-Betancourt CE, Moncla A, Milili M, Jiang YL, Viegas-Péquignot EM, Roquelaure B, Thuret I, Schiff C. Defective B-cell-negative selection and terminal differentiation in the ICF syndrome. *Blood.* 2004; 103:2683-90.
- Abbas AK, Lichtman AH. B cell activation and antibody production. In: Abbas AK and Lichtman AH, editors. *Cellular and Molecular Immunology.* Philadelphia: Elsevier Saunders; 2005: 189-215.
- Vinuesa CG, Cook MC. The Molecular Basis of Lymphoid Architecture and B cell Responses: Implications for Immunodeficiency and Immunopathology. *Curr Mol Med.* 2001; 1:689-725.

■ Manuscript received August 12, 2011; accepted for publication, October 19, 2011.

B Makay

Dokuz Eylül University Hospital,
Department of Pediatrics,
Division of Immunology-Rheumatology
35340, Balçova-Izmir
Turkey
E mail: balahan.bora@deu.edu.tr

Cold Urticaria Induced by Alprazolam

M Gandolfo-Cano, E González-Mancebo, D González-de-Olano, A Meléndez-Baltanás, E Mohedano-Vicente
Allergy Unit, Hospital Universitario de Fuenlabrada, Madrid, Spain

Key words: Cold urticaria. Alprazolam. Ice cube test.

Palabras clave: Urticaria a frigore. Alprazolam. Test del cubito de hielo.

Cold urticaria is characterized by the rapid onset of pruritus, erythema, and wheals after exposure to a cold stimulus. Cases of cold urticaria after exposure to agents such as drugs are infrequent [1,2]. Allergic reactions due to benzodiazepines are extremely rare, and most have been described with diazepam [3]. We present a case of cold urticaria induced by alprazolam.

A 44-year-old man developed pruritus, edema, and wheals in the parts of his body that had come into contact with cold water. Symptoms resolved spontaneously without treatment. He had started taking alprazolam 10 days previously. The patient's anxiety improved and he stopped taking alprazolam. He was able to swim in both a pool and the sea. Four months later, he was again prescribed alprazolam. One week after initiating treatment he developed wheals and pruritus on his legs and right hand while watering the garden.

The results of a prick test (0.5 mg/mL) and oral challenge with alprazolam (cumulative dose of 1 mg) were both negative. The patient was advised to continue taking alprazolam 0.5 mg/d at home. The results of an ice cube test and a cold water test performed 1 week later were positive [1,4]. Alprazolam was stopped and the ice cube test and cold water test were repeated 1 month later with negative results. A biochemistry workup comprising a liver panel, leukocytes, erythrocytes, platelets, antinuclear antibodies, serology, cryoglobulins, cryoagglutinins, complement, and rheumatoid factor revealed normal values [1]. Diagnosis was confirmed using a double-blind placebo-controlled ice cube test with and without alprazolam. The result was positive with alprazolam only.

Cold urticaria accounts for 3%-5% of all cases of physical urticaria. It involves wheals and pruritus after exposure of the skin to cold. This disorder can be classified as familial or acquired. The acquired form can be typical or atypical, depending on the positivity or negativity of the ice cube test [1,4]. Typical cold urticaria is classified into 2 groups: primary cold urticaria (72%) and secondary cold urticaria (28%). The reported causes of secondary cold urticaria are cryoglobulinemia, cryoagglutinins, cryohemolysins, cryofibrinogens, leukocytoclastic vasculitis, infectious diseases, hypothyroidism, celiac disease, and isolated induction due to drugs (penicillin, oral contraceptives, and griseofulvin) [1,2,5]. Atypical cold urticaria comprises systemic forms, cold-dependent dermographism, cold-induced cholinergic urticaria, delayed cold urticaria, and cold reflex urticaria [1,4,5]. The pathogenesis of this type of urticaria is not well known, but the release of mast cell mediators seems to be an essential component. Histamine, prostaglandin D₂, platelet-activating

factor, and tumor necrosis factor α have been found in the skin and serum of patients with cold urticaria [1,4].

Alprazolam is a potent short-acting benzodiazepine. It is primarily used to treat moderate to severe anxiety, panic attacks, and nausea due to chemotherapy. Exceptionally, alprazolam induces angioedema and other allergic reactions [6]. It has also been reported to be a successful treatment for chronic drug-resistant urticaria, possibly owing to its anti-H₁ effect [7]. In 1 case of cold urticaria reported during induction of anesthesia with atropine, midazolam, fentanyl, thiopental, and atracurium at 21°C, the ice cube test was positive without ingestion of drugs [8].

We present the case of a man who tolerated cold water but presented cold urticaria while receiving treatment with alprazolam. Although the immunological mechanism remains unclear, we suggest that benzodiazepines (a well-known trigger for histamine release) together with the cold stimulus might induce the release of mast cell mediators. To our knowledge, this is the first report of cold urticaria induced by alprazolam.

References

1. Ferrer M, Luquin E, Gaig P. Urticaria. In: A. Peláez Hernández, IJ. Dávila González, editors. *Tratado de Alergología*. Madrid: Ergon; 2007; Vol II, p. 1031-47.
2. Gaig P, Olona M, Muñoz Lejarazu D, Caballero MT, Domínguez FJ, Echechipia S, García Abujeta JL, Gonzalo MA, Leonart R, Martínez Cócera C, Rodríguez A, Ferrer M. Epidemiology of urticaria in Spain. *J Invest Allergol Clin Immunol*. 2004;14:214-20.
3. García Ortega P, Audicana Berasategui MT, Corominas M, Lobera Labairu T. Reacciones alérgicas durante la anestesia general. In: A. Peláez Hernández, IJ. Dávila González, editors. *Tratado de Alergología*. Madrid: Ergon; 2007; Vol II, p. 1483-1504.
4. Carrasquer C, López-Baeza JL, Fernández Alonso E, Durá M, Peláez A. Urticaria a frigore: características clínicas y diagnósticas. *Allergol Inmunol Clin*. 2001;16:218-24.
5. Pedrosa Delgado M, Martín Muñoz F, Polanco Allué I, Martín Esteban M. Cold urticaria and celiac disease. *J Invest Allergol Clin Immunol*. 2008;18(2):123-5.
6. Sella-Dupré G, Nieto-López M, García-Vicente JA, Salvador-Chiva J. Angioedema lingual por alprazolam. *Med Clin (Barc)* 2006;127(10):398-9.
7. Dueñas-Laita A, Ruiz-Muñoz P, Armentia A, Pinacho F, Marín-Armentia B. Successful treatment of chronic drug-resistant urticaria with alprazolam. *J Allergy Clin Immunol*. 2009;123(2):504-5.
8. Ariño P, Aguado L, Cortada V, Baltasar M, Puig M. Cold urticaria with intraoperative hypotension and facial edema. *Anesthesiology*. 1999;90:907-9.

■ Manuscript received July 27, 2011; accepted for publication October 21, 2011.

Mar Gandolfo Cano

Allergy Unit.
 Hospital Universitario de Fuenlabrada.
 Camino del Molino, 2.
 28942 Fuenlabrada (Madrid), Spain.
 E-mail: mgandolfo.hflr@salud.madrid.org

Custard Apple and Latex Allergy: A New Type of Cross-reaction?

S Santos-Magadán,¹ B Bartolomé-Zavala,² B Rodríguez-Jiménez,¹ D González-de-Olano,³ F Heras-Mendoza,⁴ L Conde-Salazar,⁴ C Martínez-Cócerca,¹ M Fernández-Rivas¹
¹Allergy Unit, Hospital Clínico San Carlos, Madrid, Spain
²R+D Department, Bial-Aristegui Laboratory, Bilbao, Spain
³Hospital Universitario de Fuenlabrada, Madrid, Spain
⁴Departamento de Dermatología Ocupacional, Instituto Carlos III, Madrid, Spain

Key words: Custard apple. Hevein. Cross-reaction Class I chitinases. Latex-fruit syndrome.

Palabras clave: Chirimoya. Heveína. Reactividad cruzada. Quitinasas clase I. Síndrome látex-frutas.

Custard apple, or cherimoya, is a tropical fruit belonging to the Annonaceae family. Some of the cases of allergy to this fruit that have been reported were related to cross-reaction with latex. Fruit class I chitinases with an N-terminal hevein-like domain and latex hevein (Hev b 6.02) have been identified as the main allergens (panallergens) responsible for this type of cross-reaction [1].

A 28-year-old woman who worked as a fishmonger was examined at our hospital. During the previous year, she had developed pruritus, erythema, and wheals on her fingers, hands, and forearms while working. These symptoms improved on weekends and vacation. She wore latex gloves at work and reported no symptoms when touching or eating fish. During the previous 4 years, she had also experienced tongue and pharyngeal pruritus and labial erythema after eating custard apple. She presented no symptoms with any other fruits, including avocado, chestnut, banana, and papaya. As the only additional atopic background, she reported seasonal rhinoconjunctivitis.

Skin prick tests with commercial extracts of latex, common inhalants and fruits, date palm pollen profilin, and Pru p 3 gave positive results (mean wheal diameter ≥ 3 mm) for latex (6 mm), chestnut (5 mm), and profilin (6 mm), as well as the following pollens: grass (9 mm), olive (8 mm), plane tree (4 mm), *Plantago lanceolata* (5 mm), mugwort (4 mm), and *Chenopodium album* (8 mm). A prick-prick test with fresh custard apple elicited a positive response (7 mm). Total and specific immunoglobulin (Ig) E were assessed using the CAP system (Phadia): serum specific IgE was positive (>0.35 kU_A/L) for grass pollen (>100 kU_A/L), olive tree pollen (23.5 kU_A/L), plane tree pollen (11.9 kU_A/L), avocado (0.85 kU_A/L), chestnut (0.38 kU_A/L), banana (0.68 kU_A/L), papaya (2.50 kU_A/L), latex (4.1 kU_A/L), rHev b 6.02 (0.38 kU_A/L), and rBet v 2 (6.25 kU_A/L). Total IgE was 800 IU/mL. Specific IgE tests against additional latex recombinant proteins (rHeb v 1, rHeb v 3, rHeb v 5, and rHeb v 6.01) were negative. Skin patch tests (True Test) with readings at 48 hours and 96 hours were also negative.

We did not perform an additional oral challenge, as

the patient reported several adverse reactions (oral allergy syndrome) after eating custard apple. The latex glove use test was not performed because of the positive skin prick test and CAP results and a very suggestive clinical history. She also experienced symptoms with latex condoms and remained completely asymptomatic as soon as she stopped using latex at work.

Sodium dodecyl sulfate polyacrylamide gel electrophoresis (SDS-PAGE) performed with the custard apple extract showed bands ranging from 70 kDa to 12 kDa. IgE immunoblotting carried out with the patient's serum revealed a prominent IgE binding band of 14 kDa (Figure 1A, lane P). Additional bands of 40-42 kDa could not be considered specific as they also appeared in the control serum (Figure 1A, lane C).

Immunoblot-inhibition assays with extracts of custard apple, avocado, papaya, latex, latex profilin, mugwort profilin, and Hev b 1 revealed cross-reaction between custard apple and the extracts of avocado, papaya, and latex. Nevertheless, no inhibition was detected between custard apple and the 2 profilins (Figure 1B), and poor inhibition was observed with rHev b 1 (Figure 1C) (allergens with molecular masses of around 14 kDa).

Proteins of the IgE-binding band were identified using mass spectrometry. The gel band was manually excised from micropreparative gels using biopsy punches. The protein selected for analysis was reduced, alkylated, and digested in-gel with trypsin according to the procedure of Shevchenko et al [2]. After digestion, the supernatant was analyzed in a matrix-assisted laser desorption/ionization-time of flight mass spectrometer (4700 Proteomics Analyzer, Applied Biosystems). Tandem mass spectrometry was performed at the Genomics and Proteomics Center, Universidad Complutense de Madrid, Madrid, Spain.

High sequence homology was found between a peptide belonging to 1 of the proteins of this band and the acyl carrier protein, which is widely distributed throughout the vegetable kingdom. This protein is an essential cofactor in the synthesis of fatty acids by the fatty acid synthetase system in bacteria and plants.

Allergy to custard apple is rare [3-5]. The first report involved a description of the presence of a 20-25-kDa allergen in custard-apple [3], and further studies detected cross-reactivity between custard apple and latex involving bands of around 40-45 kDa [4-7]. An allergen of 45 kDa was subsequently identified as a chitinase by means of rabbit monospecific antichitinase antibodies [6]. The N-terminal hevein domain in class I chitinases is usually responsible for cross-reactivity with latex hevein. Other in vitro assays also suggest that relevant epitopes are contained in the catalytic domain of these allergens (26 kDa) [1].

We report a case of IgE-mediated allergy to custard apple associated with latex allergy. A custard apple IgE-binding band of 14 kDa was detected. This allergen displayed cross-reactivity with latex, papaya, and avocado, but not with Hev b 1 or profilin. High sequence homology was found between peptides of this 14-kDa band and acyl carrier protein. We suggest that this could be a new allergen involved in cherimoya and latex cross-reaction, although further studies would be necessary to prove its allergenicity.

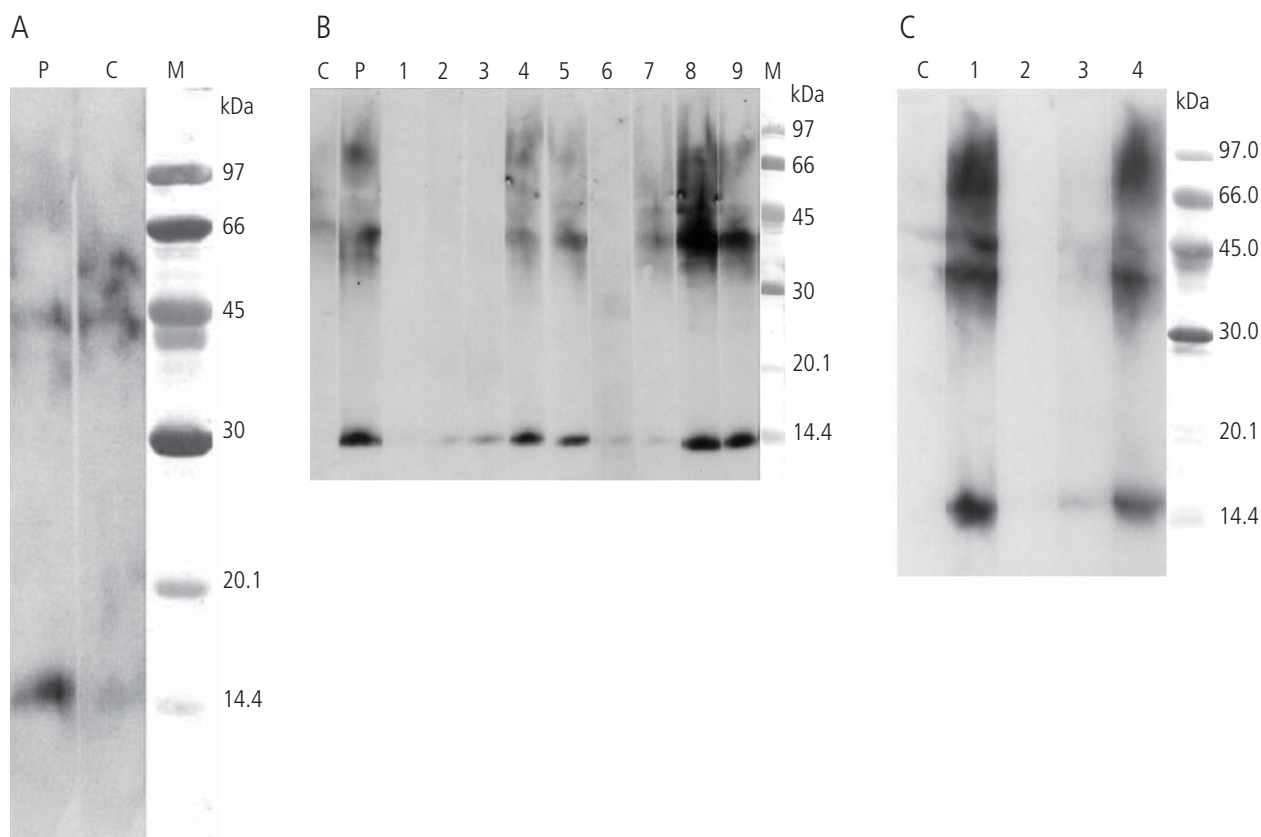


Figure. Results of SDS-PAGE immunoblotting with custard apple extract. A, Lane P, patient serum; lane C, control serum (pool of sera of nonatopic subjects); lane M, molecular mass markers. B, SDS-PAGE immunoblotting-inhibition results. Custard apple extract in the solid phase. Inhibition phase: lane C, control serum (pool of sera of nonatopic subjects); lane P, patient serum; lane 1, custard apple (peel); lane 2, custard apple (pulp); lane 3, latex; lane 4, latex profilin; lane 5, mugwort pollen profilin; lane 6, avocado; lane 7, papaya; lane 8, lamb; lane 9, bovine serum albumin; lane M, molecular mass markers. C, SDS-PAGE immunoblotting inhibition results. Custard apple extract in the solid phase. Inhibition phase: lane C, control serum (pool of sera of nonatopic subjects); lane 1, patient serum; lane 2, custard apple (peel); lane 3, Hev b 1 (160 µg/mL); lane 4, bovine serum albumin; lane M, molecular mass markers. SDS-PAGE indicates sodium dodecyl sulfate polyacrylamide gel electrophoresis.

References

- Díaz Perales A, Sánchez Monge R, Blanco C, Lombardero M, Carrillo T, Salcedo G. What is the role of the hevein-like domain of fruit class I chitinases in their allergenic capacity? *Clin Exp Allergy*. 2002;32:448-54.
- Shevchenko A, Wilm M, Vorm O, Mann M. Mass spectrometric sequencing of proteins from silver-stained polyacrylamide gels. *Anal Chem*. 1996;68 (5):850-8.
- Gonzalo MA, Moneo I, Ventas P, Polo F, García JM. IgE mediated hypersensitivity to custard-apple. *Allergy*. 1997;52:597.
- Sanchez Guerrero IM, Escudero AI, Tortosa JA, Lombardero M. Anaphylaxis to cherimoya. *Allergy*. 2000;55:976-7.
- Sánchez-Morillas L, Moneo I, Sedano E, Iglesias A, Caballero ML, Rodríguez M. Oral allergy syndrome after ingestion of custard apple. *Allergy*. 2003;58 (3):260-1.
- Gamboa PM, Sánchez-Monge R, Díaz Perales G, Salcedo G, Anstegui ML. Latex-vegetable syndrome due to custard-apple and aubergine: new variations of the hevein symphony. *J Invest Allergol Clin Immunol*. 2005;12(4):308-11.
- Díaz-Perales A, Collada C, Blanco C, Sánchez-Monge R, Carrillo T, Aragoncillo C, Salcedo G. Cross-reactions in the latex-fruit syndrome: A relevant role of chitinases but not of complex asparagine-linked glycans. *J Allergy Clin Immunol*. 1999;104 (3 Pt 1):681-7.

■ Manuscript received May 29, 2011; accepted for publication October 25, 2011.

Sara Santos Magadán

Allergy Department
Hospital Clínico San Carlos. Madrid
Profesor Martín Lagos, s/n
28040 Madrid, Spain
E-mail: sarasantosmagadan@hotmail.com

Aseptic Meningitis Induced by Vitamin B Complex

PA Galindo Bonilla,¹ N Sánchez Rodríguez,¹ A Castro Jiménez,¹ JJ Muñoz-Torrero Rodríguez,² T Bellón Heredia,³ F Feo Brito¹

¹Allergy Section, General University Hospital, Ciudad Real, Spain

²Neurology Section, General University Hospital, Ciudad Real, Spain

³Health Research Institute-IdiPaz, La Paz Hospital, Madrid, Spain

Key words: Drug-induced aseptic meningitis. Vitamin B hypersensitivity.

Palabras clave: Meningitis aséptica inducida por medicamentos. Hipersensibilidad a vitamina B.

Drug-induced aseptic meningitis (DIAM) is a rare adverse effect of several drugs. The major causative agents are nonsteroidal anti-inflammatory drugs, especially ibuprofen [1] and antibiotics (trimethoprim-containing and penicillin-derived antibiotics are the most commonly identified) [2-5].

We report the first case of aseptic meningitis (AM) due to a hypersensitivity reaction to vitamin B complex.

A 29-year-old woman with a history of autoimmune subclinical hypothyroidism attended the emergency room with generalized seizure, neck stiffness, and lethargy. She required sedation and was admitted to the intensive care unit.

Laboratory data revealed a white blood cell count of 11 200/cm³ (normal formula), hemoglobin 10.5 g/dL, total proteins 4.4 g/dL, and aspartate aminotransferase 60 IU/L. The results of clotting tests, urinalysis, and blood gas analysis were normal. Computed tomography (CT) scans and

magnetic resonance imaging (MRI) of the head were normal. Cerebrospinal fluid (CSF) analysis revealed pleocytosis with 31 leukocytes/mm³ (lymphocytes, 90%), increased proteins (7.6 g/L), and normal glucose. No bacterial microorganisms, tumor cells, or Mollaret cells were found. Blood cultures did not yield growth of microorganisms. Serology testing for viruses and bacteria was negative.

Empirical treatment with antibiotics and acyclovir was started, and the patient recovered within 24 hours. She was discharged with a diagnosis of probable viral meningitis.

The patient was readmitted 7 days later due to fever (39°C), malaise, facial itching, globus sensation, and neck stiffness. CSF analysis revealed pleocytosis with 171 leukocytes/mm³ (polymorphonuclear, 95%), increased proteins (5.9 g/L), and normal glucose. No treatment was prescribed. After 2 weeks, while still hospitalized for observation, she presented fever (38.5°C), headache, facial itching, and dyspnea. The patient associated these symptoms with taking 1 tablet of vitamin B complex (Hidroxil B1,B6,B12, Almirall SA; thiamine hydrochloride [B1] 250 mg, pyridoxine hydrochloride [B6] 250 mg, hydroxocobalamin hydrochloride [B12] 500 mg) 2 hours earlier. A new CSF analysis revealed pleocytosis with 55 leukocytes/mm³ (polymorphonuclear, 90%). As DIAM was suspected, the patient was studied in our allergy department.

The patient had started treatment with vitamin B complex 1 month before the first admission. Treatment was stopped during her stay in hospital and restarted after discharge. An allergy workup was performed and included prick tests with thiamine (100 mg/mL), pyridoxine (150 mg/mL), and cyanocobalamin (500 µg/mL), as well as intradermal tests with the same drugs at 1/100 and 1/10 of the initial concentration. Patch tests were also performed with the same drugs. Readings taken at 20 minutes and 2 and 48 hours were negative.

A lymphocyte transformation test (LTT) was performed according to the methodology of Pichler et al [6] with the pure forms of B1, B6, and B12 (kindly provided by Almirall, SA) (Table). The result was positive with B1 (stimulation index, >2)

Table. Lymphocyte Transformation Test With Active Drugs

Concentrations Vitamin B1 and B6, µg/mL ^a	Vitamin B1+B6+B12 ^a	Vitamin B1	Vitamin B6	Concentrations Vitamin B12, µg/mL	Vitamin B12	PHA ^b
200	0.90	1.96	0.35	10	1.89	15
100	1.51	1.68	1.07	5	2.34 ^c	
50	1.32	1.81	1.05	2.5	1.10	
25	1.56	1.51	1.22	1	1.59	
10	2.19 ^c	2.98 ^c	1.09	0.5	1.34	
1	2.21 ^c	1.58	1.32	0.05	1.39	
0.1	1.87	1.98	1.54	0.005	0.92	

Abbreviation: PHA, phytohemagglutinin A.

^aConcentrations corresponding to vitamins B1 and B6 in the pharmaceutical presentation Antineurina. The concentration of vitamin B12 is 25-fold lower.

^bPhytohemagglutinin A (PHA) was used as a control mitogen.

^cPositive result

at high and low concentrations. LTT was also positive with B12 but only with high concentrations. LTT with B6 was negative. Therefore, the patient was sensitized to B1, possibly sensitized to B12, and not sensitized to B6.

We did not perform any exposure test with the drug responsible for the reaction, because the clinical history was very suggestive (recurrence on 3 occasions after taking the drug), the LTT result was positive, and oral challenge was dangerous.

The definitive diagnosis was DIAM caused by hypersensitivity to vitamin B complex.

Aseptic meningitis is characterized by inflammation of the meninges that is not induced by an infectious agent [4]. DIAM is a rare adverse effect of several drugs.

The clinical features of DIAM are similar to those of other types of meningitis (fever, headache, and neck stiffness), although other signs and symptoms (eg, skin rash, arthralgia, hepatic dysfunction, and conjunctivitis) have been reported [2]. CSF findings are similar to those of other causes of aseptic meningitis, with pleocytosis (>5 cells/ mm^3). CSF protein is elevated, with a normal CSF to blood glucose ratio. By definition, CSF cultures are negative [2]. CT and MRI findings are usually normal [2], and prognosis is good, with total resolution of the syndrome 2-3 days after withdrawal of the drug.

The pathogenesis of DIAM is not fully understood. Type III and type IV hypersensitivity mechanisms are the most likely to be involved.

An immunologically mediated hypersensitivity reaction, such as a pathogenic mechanism of DIAM [2,7,8], seems to account for our patient's condition, based on the following: *a*) The symptoms are not dose-dependent; *b*) The latency period between drug intake and the onset of symptoms is usually 24-48 hours; *c*) Previous exposure to the drug is mandatory (onset of meningitis is between several weeks and 4 months after ingestion); *d*) The rapidity and severity of symptoms increases on subsequent re-exposure; *e*) The symptoms resolve upon discontinuation.

It has been proposed that the drug combines with a CSF or meningeal protein that acts as a hapten, leading to an inflammatory response in the meninges [8]. Immune complex deposition and detection have been found in many cases of DIAM, suggesting a type III reaction [2].

In a patient with DIAM due to ibuprofen, Martin et al [7] detected a highly elevated concentration of total immunoglobulin (Ig) E (1099 $\mu\text{g/mL}$), and after total resolution of symptoms, serum IgE returned to normal.

Specific IgG against ceftazidime was found in a patient with recurrent DIAM by induced by cephalexin, cefazolin, and ceftazidime, and the skin tests with cefazolin caused recurrence of meningitis [3].

Diagnosis of DIAM is difficult. A close temporal relationship between ingestion of a drug and onset of clinical symptoms and CSF findings consistent with meningitis supports the diagnosis, which is a diagnosis of exclusion. The suspected drug should be withdrawn. The only confirmatory test would be rechallenge with the drug, although this is not ethically justified [8]. Our patient was inadvertently rechallenged with vitamin B complex, and meningitis reappeared.

The criteria for diagnosis of DIAM are as follows: *a*) a temporal relationship with drug intake; *b*) CSF pleocytosis; *c*) negative testing for microorganisms; *d*) absence of another explanation; and *e*) complete resolution following discontinuation of the drug [5]. Our patient met all these criteria, including rechallenge with the drug and a positive LTT. The skin tests were not useful.

Acknowledgments

The authors thank the nurses of our respective sections (Elena Andrés, M^a José Muñoz, M^a José Ruiz, and Patricia García) for their collaboration. We thank Victoria Merino for assistance in the English version of this report.

The case described was presented at Sesiones Interhospitalarias de la Sociedad Madrid-Castilla La Mancha de Alergología e Inmunología Clínica, October 2010, Madrid, Spain.

References

1. Cano Vargas-Machuca E, Mondéjar-Marín B, Navarro-Muñoz S, Pérez-Molina I, Garrido-Robres JA, Alvarez-Tejerina A. Meningitis recurrente aséptica secundaria a toma de ibuprofeno y ketorolaco Rev Neurol. 2006;42(4):217-219.
2. Hopkins S, Jolles S. Drug-induced aseptic meningitis. Expert Opin Drug Saf. 2005 Mar;4(2):285-97
3. Creel GB, Hurtt M. Cephalosporin-induced recurrent aseptic meningitis. Ann Neurol. 1995; 37(6):815-7.
4. Wambulwa C, Bwayo S, Laiyemo AO, Lombardo F. Trimethoprim-sulfamethoxazole-induced aseptic meningitis. J Natl Med Assoc. 2005; 97 (12):1725-7.
5. Thauinat O, Gilquin J, Lazareth I, Priollet P. Amoxicillin-induced aseptic meningo-encephalitis. Allergy. 2003;58(7):687-8.
6. Pichler WJ, Tilch J. The lymphocyte transformation test in the diagnosis of drug hypersensitivity. Allergy. 2004;59:809-20.
7. Bluth MH, Beleza P, Hajee F, Jordao MJ, Figuereido J, Almeida F, Smith-Norowitz T. IgE-mediated hypersensitivity after ibuprofen administration. Ann Clin Lab Scienc. 2007; 37(4):362-5.
8. Moris G, García-Monco JC. The challenge of drug-induced aseptic meningitis. Arch Intern Med. 1999;159:1185-94.

■ Manuscript received September 14, 2011; accepted for publication October 26, 2011.

Pedro A Galindo Bonilla

Sección de Alergología
Hospital General Universitario de Ciudad Real
C/ Obispo Rafael Torija, s/n
13005 Ciudad Real, Spain
E-mail: agalindo_2@yahoo.com

Asthma After Chicken Consumption due to Cross-reactivity Between Fish and Chicken Parvalbumin

D González-de-Olano,¹ B Bartolomé,² AS Maroto,³
F Vivanco,³ C Pastor-Vargas³

¹ Allergy Unit, Hospital Universitario de Fuenlabrada, Madrid, Spain

² Research & Development Department, Bial-Arístegui, Bilbao, Spain

³ Instituto de Investigación Sanitaria-Fundación Jiménez Díaz, Madrid, Spain

Key words: Allergy. Asthma. Chicken. Cross-Reactivity. Fish. Parvalbumin.

Palabras clave: Alergia. Asma. Parvalbúmina. Pescado. Pollo. Reactividad cruzada.

Fish is a staple of human nutrition and is consumed worldwide. Fish allergy is the third cause of pediatric food allergy in our environment and the sixth in adults [1]. Parvalbumins have been reported to be the main panallergen in fish allergy [2]. Although cross-reactivity between fish and amphibian parvalbumins has been documented [3], there are no reports of adverse reactions to other widely consumed foods (eg, chicken) caused by cross-reactivity with fish parvalbumins.

A 23-year-old woman presented with chest tightness and wheezing within minutes of eating chicken. She did not have symptoms with other meats or with egg and she did not report contact with birds. Her atopic history included chest tightness, wheezing, and facial angioedema after ingestion of fish at the age of 9. She has avoided fish or its derivatives since then.

Skin prick tests (SPTs) to commercial extracts from meats (chicken, pork, lamb, and veal), egg white, egg yolk, ovalbumin, ovomucoid, and feather mixture were positive to chicken (wheal of 4 × 5 mm) and negative to the other allergens. The patient refused to undergo SPT against commercial fish extracts (and *Anisakis simplex*), since she had presented an anaphylactic episode after an SPT as a child. Serum specific immunoglobulin (Ig) E levels were measured using the enzyme allergosorbent technique (Specific IgE EIA kit HYTEC HYCOR Biomedical Ltd). Determination of specific IgE revealed the following values: chicken, 7.6 kU_A/mL; pork, 0.6 kU_A/mL; salmon, 10.6 kU_A/mL; hake, 95.6 kU_A/mL; and sardine, 58.3 kU_A/mL. Total IgE was 105 IU/mL. Specific IgE against *A simplex* was <0.35 kU_A/L. Protein extracts from raw and cooked chicken extract (CE) and from hake extract (HE) were prepared by homogenization in phosphate-buffered saline, followed by dialyzation and lyophilization. Sodium dodecyl sulfate polyacrylamide gel electrophoresis (SDS-PAGE) IgE immunoblotting

assays revealed IgE reactivity with proteins of 13, 16, and 55 kDa in the CE and 13, 37, 50, and 55 kDa in the HE (Figure 1A). SDS-PAGE immunoblotting inhibition using CE in the solid phase showed complete inhibition of IgE binding when the patient's serum was preincubated with HE (Figure, B, lane 2). The inhibition was not complete when CE was used as an inhibitor (Figure, B, lane 1), thus reinforcing fish parvalbumin as the primary sensitizing allergen. The 16-kDa IgE binding band from CE and the 13-kDa binding band from HE were manually excised from both gels, digested with trypsin, and analyzed using matrix-assisted laser desorption/ionization time of flight (MALDI-TOF) spectrometry and liquid chromatography electrospray ionization. Based on comparison with a database, the resulting peptides were analyzed using mass spectrometry or tandem mass spectrometry, which revealed α parvalbumin in the CE and β parvalbumin in the HE.

Parvalbumins are calcium-binding albumin proteins that are usually localized in fast-contracting muscles, and, to a lesser extent, in brain and endocrine tissue. Parvalbumins can be subdivided into 2 different evolutionary lineages, namely, α and β . α -Parvalbumins are abundant in the muscle of fish and amphibians, but much less so in the muscle of birds and mammals. They are not generally allergenic. β -Parvalbumins are common allergens in fish, although they are not found in human muscle and show reduced identity to human α parvalbumin [3,4]. α - and β -Parvalbumins have been reported to share a high homology (51% identity and 66% positive), which is increased in the calcium-binding domain, where IgE-reactive sites have been described [5]. Cases of cross-reactivity between different species of parvalbumins are rare; IgE-antibodies of fish-allergic patients have been reported to cross-react with frog parvalbumin [3]. Kuenh et al [6] reported

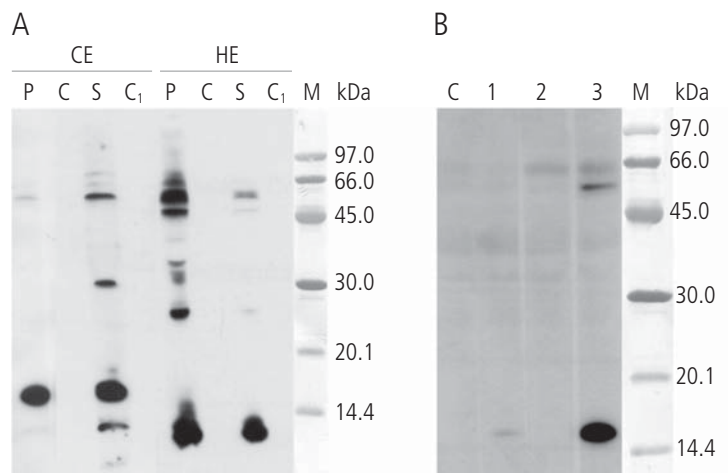


Figure. A, SDS-PAGE. CE, chicken extract. HE, hake extract. Lane P, patient's serum; Lane C, control serum (pool of sera from nonatopic subjects); Lane S, antiparvalbumin rabbit serum; Lane C1, rabbit serum before parvalbumin immunization. B, SDS-PAGE immunoblotting inhibition study. Lane C, control serum; Lane 1, patient's serum preincubated with CE (0.8 mg/mL) (homologous inhibition with positive control of inhibition); Lane 2, patient's serum preincubated with HE (0.8 mg/mL); Lane 3, patient's serum preincubated with sunflower pollen extract (0.8 mg/mL); M: molecular weight marker. SDS-PAGE indicates sodium dodecyl sulfate polyacrylamide gel electrophoresis.

reaction to chicken meat caused by IgE reactivity to muscle α parvalbumin with mild oral reactions after ingestion of tuna and salmon, although no cross-reactivity between fish and chicken parvalbumins was demonstrated, suggesting that chicken was the primary sensitizing allergen. Allergic reactions to chicken have also been reported in patients who are highly sensitized to *A simplex* [7]; however, our patient did not show detectable IgE levels against this nematode.

We present the first case of chicken allergy involving parvalbumin as the relevant allergen in a fish-allergic patient, with demonstrated cross-reactivity between α and β parvalbumin. Physicians should be aware of clinical cross-reactions involving panallergens such as parvalbumins, which might be present in widely consumed foods.

References

1. Fernández-Rivas M. Alergia a alimentos. In Colás Sanz C, Chivato Pérez T, Díaz de Rojas F, Leonart Bellfill R, Nieto García A, Peláez Hernández A, Tabar Purroy AI, editors. *Alergológica 2005. Factores epidemiológicos, clínicos y socioeconómicos de las enfermedades alérgicas en España en 2005*. Madrid: Egraf, 2006:229-53.
2. Bernhisel-Broadbent J, Scanlon SM, Sampson HA. Fish hypersensitivity. I. In vitro and oral challenge results in fish-allergic patients. *J Allergy Clin Immunol*. 1992;89:730-7.
3. Hilger C, Thill L, Grigioni F, Lehnert C, Falagiani P, Ferrara A, Romano C, Stevens W, Hentges F. IgE antibodies of fish allergic patients cross-react with frog parvalbumin. *Allergy*. 2004;59(6):653-60.
4. Jenkins JA, Breiteneder H, Mills EN. Evolutionary distance from human homologs reflects allergenicity of animal food proteins. *J Allergy Clin Immunol*. 2007;120:1399-1405.
5. Pérez-Gordo M, Lin J, Bardina L, Pastor Vargas C, Ortega Cases B, Vivanco F, Cuesta Herranz J, Sampson H. Epitope mapping of Atlantic salmon major allergen by peptide microarray immunoassay. *Int Arch Allergy Immunol*. 2012;157:31-40.
6. Kuenh A, Lehnert C, Hilger C, Hentges F. Food allergy to chicken meat with IgE reactivity to muscle alpha-parvalbumin. *Allergy*. 2009;64:1557-8.
7. Armentia A, Martín-Gil FJ, Pascual C, Martín-Esteban, Callejo A, Martínez C. Anisakis simplex allergy after eating chicken meat. *J Invest Allergol Clin Immunol*. 2006;16:258-63.

■ Manuscript received July 12, 2011; accepted for publication October 27, 2011.

David González-de-Olano
Allergy Unit
Hospital Universitario de Fuenlabrada
Camino del Molino, 2
28942 Fuenlabrada (Madrid), Spain
E-mail: dgolano@yahoo.es

Nine Cases of Allergy to Omeprazole

E Abdul Razzak, M Tomás, P Tornero, T Herrero
*Allergy Service, Hospital General Universitario Gregorio
Marañón, Madrid, Spain*

Key words: Omeprazole allergy. Proton pump inhibitors. Benzimidazole derivatives. Dot-blot. Cross-reactivity.

Palabras clave: Alergia a omeprazol. Inhibidores de la bomba de protones. Derivados benzimidazólicos. Dot-blot. Reactividad cruzada.

The benzimidazole derivative omeprazole was the first proton pump inhibitor to be marketed (1988). The 5 proton pump inhibitors currently used in Spain are omeprazole, lansoprazole, pantoprazole, rabeprazole, and esomeprazole, all of which belong to a group of benzimidazole derivatives comprising agents such as mebendazole, domperidone, and mizolastine. These drugs share a sulfanyl group in the bond between the benzimidazole ring and pyrimidine ring that gives them a similar structure in which only the free radicals are different. Omeprazole is widely used, yet few cases of allergy to this agent have been reported. The incidence of allergic reactions to omeprazole has increased in recent years.

We studied 9 patients (3 men and 6 women; mean age, 43 years [range, 23-63 years]) who had experienced allergic reactions to omeprazole. The reaction was immediate in 8 cases (urticaria/angioedema in 4 and anaphylaxis in 4) and delayed in the remaining case (exudative erythema multiforme).

All patients underwent skin testing. The 8 patients who had had an immediate reaction underwent prick testing with omeprazole (4 mg/mL) and intradermal testing with omeprazole (0.4 mg/ml) and pantoprazole (0.4 mg/mL). When the result of skin testing was negative, a challenge test was performed with omeprazole (3/8). In 4 cases, challenge testing was performed with other benzimidazole derivatives (domperidone, mebendazole, and mizolastine). Challenge tests were performed in 4 cases where other drugs were believed to be involved.

The results of prick testing were negative in all patients (8/8). The intradermal test with omeprazole was positive in 5 patients and the challenge test with omeprazole was positive in 3 cases (3/8). When challenge testing was performed with other benzimidazole derivatives (4/8) and with other medicines (4/8), the result was negative.

Dot-blot testing was performed in 1 patient (patient 6), and the result was positive.

As the reaction was delayed in patient number 9, patch testing was performed with readings at 48 hours and 96 hours. The result was negative with omeprazole (1% pet). Challenge testing with omeprazole was positive. Challenge testing with the other benzimidazole derivatives and the other drugs involved was negative.

The results of the allergy work-up are shown in the Table.

Although omeprazole is widely used, few allergic reactions have been reported. However, due to increased use of this

Table. Allergy Workup

Case	Skin Test (Prick/ID)		Patch	Dot-blot	Challenge Tests	
	Omeprazole (Prick/ID)	Pantoprazole (ID)			Omeprazole	Benzimidazoles
1	-/-	-	ND	ND	+	ND
2	-/+	-	ND	ND	ND	-
3	-/+	ND	ND	ND	ND	ND
4	-/+	-	ND	ND	ND	-
5	-/-	-	ND	ND	+	ND
6	-/+	+	ND	+	ND	-
7	-/+	+	ND	ND	ND	-
8	-/-	ND	ND	ND	+	ND
9	ND	ND	-	ND	+	ND

Abbreviations: ID, intradermal; ND, not done.

agent in clinical practice, the number of cases has increased in recent years.

Most publications describe isolated cases. Lobera et al [1] report a broad range of reactions to omeprazole. In their series, 9 patients had allergic reactions (8 immediate and 1 delayed), and in 8 of these, diagnosis was based on positive skin test results. In addition, cross-reactivity between omeprazole and pantoprazole was observed in 6 of the 9 cases reported (by skin testing in 4 and by challenge testing in 2).

We present a series of 9 cases of allergic reaction to omeprazole diagnosed using skin tests in 5 cases and challenge tests in the remaining 4. The diagnosis was urticaria/angioedema in 4 cases, anaphylaxis in 4 cases, and exudative erythema multiforme in 1 case; these findings are consistent with the severity of reactions observed elsewhere [2,3]. The occurrence of exudative erythema multiforme is surprising, because this was a delayed reaction that involved several drugs and was less suggestive of omeprazole.

In our series, symptoms, positive skin test results, and the positive dot-blot result in 1 case suggest a hypersensitivity mechanism mediated by immunoglobulin (Ig) E. Skin testing may be useful for diagnosis in clinical practice. Positive results and in vitro analysis make it possible to confirm an IgE-mediated mechanism.

We studied cross-reactivity between omeprazole and pantoprazole and verified this reaction with intradermal testing in 2 cases. Since 2 of the patients reported that this was the first time they had taken proton pump inhibitors, we decided to study cross-reactivity with other benzimidazole derivatives, observing tolerance to domperidone, mebendazole, and mizolastine by means of challenge tests in 4 patients.

Cross-reactivity between proton pump inhibitors has been described elsewhere, and cross-reactivity between omeprazole, pantoprazole, and lansoprazole has been demonstrated by skin prick testing [4,5]. Galindo et al [6] showed cross-reactivity between omeprazole and lansoprazole using skin testing. Cross-reactivity between omeprazole and pantoprazole has also been demonstrated using skin tests [7] and challenge tests [8]. Cross-reactivity between omeprazole and other benzimidazole

derivatives has received little attention, and no studies have verified its existence [9].

Given the widespread use of omeprazole in medical practice and the increased incidence of allergic reactions to it, we must consider omeprazole as a possible cause of hypersensitivity reactions. We emphasize the need for an appropriate allergy work-up, given the seriousness of most reactions. In addition, cross-reactivity studies must be performed between the various proton pump inhibitors in order to improve therapy.

The authors have no financial relationship with the pharmaceutical industry.

References

1. Lobera T, Navarro B, Del Pozo MD, González I, Blasco A, Escudero R, Venturini M, Alarcón E. Nine cases of omeprazole allergy: cross-reactivity between proton pump inhibitors. *J Invest Allergol Clin Immunol*. 2009;19:57-60.
2. Serrano González L. Shock anafilático por omeprazol. *Sociedad Madrid-Castilla La Mancha de Alergología e Inmunología Clínica, Sesiones interhospitalarias. Curso 94-95*. Madrid: Luzán 5, S.A. de Ediciones, 1995:163-174.
3. Stefanaki EC, Vovolis V, Letsa I, Koutsustathis N. Anaphylactic reaction to omeprazole. *Am J Gastroenterol*. 2008;103:1581-3.
4. González P, Soriano V, López P, Niveiro E. Anaphylaxis to proton pump inhibitors. *Allergol Immunopathol (Madr)*. 2002;30:342-3.
5. Garmendia Zallo M, Sánchez Azkarate A, Kraemer Mbula R, Liarte Ruano I, Núñez Hernández A, Cid de Rivera C. ¿Existe reactividad cruzada entre inhibidores de protones? *Allergol et Immunopathol*. 2004;32:92-5.
6. Galindo PA, Borja J, Feo F, Gómez E, García R, Cabrera M, Martínez C. Anaphylaxis to omeprazole. *Ann Allergy Asthma Immunol*. 1999;82:52-4.
7. Confino-Cohen R, Goldberg A. Anaphylaxis to omeprazole: diagnosis and desensitization protocol. *Ann Allergy Immunol*. 2006;96:33-6.

8. Reyes Balaguer J, Campos Andreu A, Hernández Fernández de Rojas D. Anaphylaxis to proton pump inhibitors. *Med Clin (Barc)*. 2007;128:799.
9. Cordobés Durán C, Gonzalo-Garijo MA, Jiménez-Ferrera G, Bobadilla-González P. Hypersensitivity reaction to mizolastine: study of cross reaction. *J Investig Allergol Clin Immunol*. 2006;16:391-3.
10. Prieto Lastra L. Hipersensibilidad a Inhibidores de la bomba de protones. *Sociedad Madrid-Castilla La Mancha de Alergología e Inmunología Clínica, Sesiones interhospitalarias. Curso 2004-05*. 2005:53-57.

■ Manuscript received July 16, 2011; accepted for publication November 7, 2011.

Eva Abdul Razzak, MD

Servicio de Alergología
Hospital General Universitario Gregorio
Marañón
Doctor Esquerdo, 46
28007 Madrid, Spain
E-mail: eva_arm@hotmail.com

Severe Drug Hypersensitivity Induced by Erdosteine and Doxofylline as Confirmed by Patch and Lymphocyte Transformation Tests: A Case Report

W-J Song,^{1,2} E-J Shim,^{1,2} M-G Kang,^{1,2} S-W Sohn,³
H-R Kang^{1,2}

¹*Department of Internal Medicine, Seoul National University College of Medicine, Seoul, Korea*

²*Institute of Allergy and Clinical Immunology, Seoul National University Medical Research Center, Seoul, Korea*

³*Department of Internal Medicine, Dongguk University Ilsan Hospital, Goyang, Korea*

Key words: Doxofylline. Erdosteine. Lymphocyte transformation test. Multiple drug hypersensitivity. Patch test.

Palabras clave: Doxofilina. Erdosteina. Prueba transformación linfoblástica. Hipersensibilidad a múltiples fármacos. Prueba del parche.

Erdosteine, a mucolytic agent used to treat chronic pulmonary diseases, exerts its pharmacological effect after conversion to the active metabolite *N*-thiodiglycolylhomocysteine [1]. Doxofylline is a xanthine derivative that differs from theophylline by the dioxolane group in its structure [2]. No severe hypersensitivity reactions have been reported to either erdosteine or doxofylline. We report the first case of severe drug hypersensitivity syndrome induced by erdosteine and doxofylline in which the association was proven by patch tests and lymphocyte transformation tests (LTTs).

A 39-year-old woman developed severe generalized maculopapular eruptions, facial edema, and fever 4 hours after taking erdosteine (300 mg) (Erdos; Daewoong Pharmaceutical Co., Ltd.) and doxofylline (400 mg) (Asima; Bukwang Pharmaceutical Co., Ltd.). Laboratory tests revealed eosinophilia (519/ μ L) and elevated C-reactive protein levels (2.62 mg/dL), but were otherwise normal. Serology tests for viral hepatitis and human immunodeficiency virus were negative, while tests for latent viruses such as Epstein-Barr virus or human herpesvirus were not performed.

The clinical history revealed that the patient had been treated for a drug reaction with eosinophilia and systemic symptoms (DRESS) syndrome 1 year previously. She had been admitted to another hospital with fever, generalized maculopapular eruptions, facial edema, liver dysfunction, and eosinophilia, which developed 4 weeks after initiation of erdosteine, doxofylline, and levofloxacin. An investigation to identify the agents responsible had not been performed, as the patient had pulmonary tuberculosis, the onset of which was 4 months after developing DRESS syndrome. The patient had also been suspected of having Behçet disease, based on recurrent oral ulcers and arthralgia.

Considering the severity of the patient's clinical history, oral corticosteroid treatment (prednisolone, 20 mg/d) was

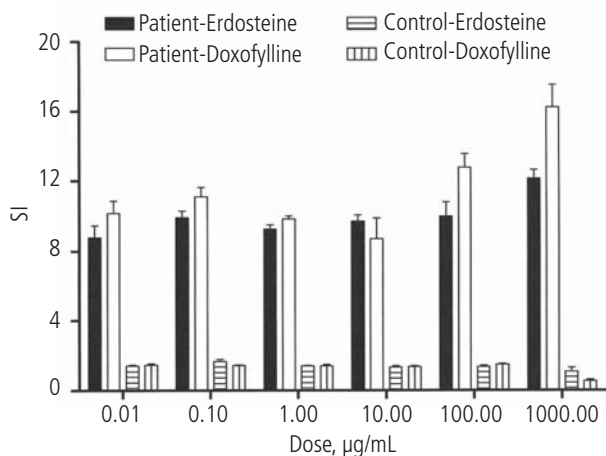


Figure. Lymphocyte transformation tests with increasing doses of erdosteine and doxofylline. The results are shown as SI (stimulation index), which indicates the fold increase in lymphocyte proliferation in cultures with the drug compared to cultures without the drug. Data are expressed as mean (SEM).

initiated immediately, despite there being no confirmed internal organ involvement. The maculopapular eruption resolved after 10 days of treatment. As the patient had been taking erdosteine and doxofylline before both episodes of hypersensitivity, we considered 1 of them to be the likely causative agent. Ten months after complete resolution, investigations were performed using both drugs. However, oral challenge tests could not be performed owing to the risk of systemic reaction. Patch tests were carried out using 10% erdosteine and 10% doxofylline (in petrolatum). Positive reactions to erdosteine (erythema with papules) and doxofylline (erythema) were recorded at 48 and 72 hours in our patient, whereas no skin reactions occurred when the drugs were tested on 5 healthy volunteers. In order to identify the causative agent, an LTT was performed using pure erdosteine and doxofylline with no excipients. Lymphocytes from the patient and 2 healthy controls were incubated for 5 days with various concentrations of erdosteine or doxofylline, and ^3H -thymidine uptake was measured [3]. Lymphocytes from the patient showed active proliferation, with a stimulation index of >3 , while those from the controls were negative (Figure). Based on these findings, we concluded that both drugs were linked to DRESS syndrome and drug eruptions. The manifestations of the second reaction were immediate and mild without severe organ involvement; however, the rapid onset of symptoms supports the conclusion that the drugs to which the patient had previously been exposed were responsible.

DRESS syndrome is a potentially life-threatening drug hypersensitivity reaction characterized by eruption, eosinophilia, and organ involvement. Anticonvulsants, allopurinol, and antibiotics are the drugs most commonly associated with this condition [4]. Identification of the causative agent is essential for management. Treatment with the causative agent should be discontinued promptly after diagnosis, and re-exposure should be avoided. However, the identification of the causative agent is often complicated by

polypharmacy or delayed onset of the syndrome. In a recent literature review, more than half of the causative agents were associated with a single case [4]. Therefore, less commonly prescribed drugs should be considered when treating patients with suspected DRESS syndrome.

Direct oral challenge is the gold standard for confirming causal relationships. However, oral challenge tests are contraindicated in severe cases because of the risk of life-threatening reactions. Indirect tests such as patch tests and LTTs are safe alternatives, and their use in clinical practice has been reviewed [3,5]. These tests can indicate the status of sensitization but not its cause; nevertheless, the results may provide important clues as to the identity of the causative agent. The LTT is an optimal approach for detection of drug hypersensitivity. Its advantages include simultaneous assessment of several drugs and absence of the risk of resensitization through in vivo provocation or skin testing [6]. The test has a sensitivity of 60%-70% and specificity of 85%-93% and is more useful in patients with DRESS syndrome [3,6].

As our case was associated with 2 drugs, a diagnosis of multiple-drug hypersensitivity can be proposed. The term multiple-drug hypersensitivity syndrome is used to describe a clinical entity characterized by immune-mediated reactions to 2 or more structurally unrelated drugs [7,8]. Its prevalence and incidence are considered to be low, but it could be about 10% among patients with confirmed drug allergy [7]. A dysregulated tolerance mechanism or persistent pre-activation of drug-reactive CD4^+ T cells might account for the simultaneous or sequential sensitization, although the mechanism involved remains unclear [7]. Colombo et al [9] reported a high rate of concomitant autoimmune diseases among patients with multiple-drug hypersensitivity, suggesting a possible link between autoimmunity and drug sensitization. Our patient had a history of Behçet disease and tuberculosis infection, which could imply immune dysregulation. Antibiotics, anticonvulsants, and nonsteroidal anti-inflammatory drugs are the agents most frequently involved, although other drugs, such as lidocaine, loratadine, cetirizine, fentanyl, triazolam, and propranolol, have also been reported [8,9]. As for DRESS syndrome, few cases have been reported with carbamazepine/fluvoxamine, phenytoin/sulfamethoxazole, and phenobarbital/ceftriaxone [8,10]. Based on this information, our patient was diagnosed with severe drug reaction accompanied by features of multiple-drug hypersensitivity.

In conclusion, we report an unusual case of severe drug hypersensitivity syndrome with features of multiple-drug hypersensitivity induced by erdosteine and doxofylline. The association was supported by the clinical history and the results of diagnostic tests, including patch tests and LTTs.

Acknowledgments

This research was supported by the Basic Science Research Program through the National Research Foundation of Korea (NRF) funded by the Ministry of Education, Science and Technology (No. 2009-0072738). The authors have no conflicts of interest to declare.

References

1. Moretti M, Marchioni CF. An overview of erdosteine antioxidant activity in experimental research. *Pharmacol Res.* 2007;55:249-54.
2. Page CP. Doxofylline: a "novofylline". *Pulm Pharmacol Ther.* 2010;23:231-4.
3. Pichler WJ, Tilch J. The lymphocyte transformation test in the diagnosis of drug hypersensitivity. *Allergy.* 2004;59:809-20.
4. Cacoub P, Musette P, Descamps V, Meyer O, Speirs C, Finzi L, Roujeau JC. The DRESS syndrome: a literature review. *Am J Med.* 2011;124:588-97.
5. Barbaud A. Drug patch testing in systemic cutaneous drug allergy. *Toxicology.* 2005;209:209-16.
6. Porebski G, Gschwend-Zawodniak A, Pichler WJ. In vitro diagnosis of T cell-mediated drug allergy. *Clin Exp Allergy.* 2011;41:461-70.
7. Pichler WJ, Daubner B, Kawabata T. Drug hypersensitivity: flare-up reactions, cross-reactivity and multiple drug hypersensitivity. *J Dermatol.* 2011;38:216-21.
8. Gex-Collet C, Helbling A, Pichler WJ. Multiple drug hypersensitivity—proof of multiple drug hypersensitivity by patch and lymphocyte transformation tests. *J Investig Allergol Clin Immunol.* 2005;15:293-6.
9. Colombo G, Yacoub M, Burastero S, Garattini E, Girlanda S, Saporiti N, Salvo F, Sabbadini M. Multiple drug hypersensitivity: insight into the underlying mechanism and correlation with autoimmune diseases. *Eur Ann Allergy Clinical Immunol.* 2009;41:50-5.
10. Voltolini S, Bignardi D, Minale P, Pellegrini S, Troise C. Phenobarbital-induced DiHS and ceftriaxone hypersensitivity reaction: a case of multiple drug allergy. *Eur Ann Allergy Clin Immunol.* 2009;41:62-3.

■ Manuscript received August 23, 2011; accepted for publication November 15, 2011.

Hye-Ryun Kang, MD, PhD

Department of Internal Medicine
Seoul National University Hospital
101 Daehak-ro Jongno-Gu, Seoul 110-744, Korea
E-mail: helenmed@hanmail.net

Serum IL-9 Levels in Patients With Spontaneous Urticaria: A Preliminary Study

G Ciprandi,¹ M De Amici,² S Legoratto,³ V Giunta,² M Vignini,³ G Borroni³

¹IRCCS - Azienda Ospedaliera Universitaria San Martino, Genoa, Italy

²Foundation IRCCS San Matteo, ImmunoAllergy Lab, Pavia Italy

³Foundation IRCCS San Matteo, Dermatology Clinic, Pavia, Italy

Key words: Serum IL-9. Urticaria. Symptom duration.

Palabras clave: IL-9 en suero. Urticaria. Duración de síntomas.

Various subpopulations of effector and regulatory T cells have been shown to play a crucial role in inflammation [1]. Depending on the exposure to antigens and status of the cells and cytokines in the milieu, naïve CD4⁺ T cells can differentiate into type 1 effector helper T cells (T_H1), T_H2, T_H9, or T_H17 [2]. T_H9 cells lack suppressive function and constitute a distinct subpopulation of effector T cells that promote tissue inflammation and mucus production [3]. In particular, interleukin (IL) 9 is an important stimulus for tissue infiltration by mast cells; IL-9 also stimulates mucous production in patients with asthma. The cell sources of IL-9 include T cells, eosinophils, neutrophils, and mast cells. A study based on nasal biopsies demonstrated that IL-9 is upregulated in the nasal mucosa during the pollen season and correlates with tissue infiltration by eosinophils [4]. It was recently reported that serum IL-9 levels were correlated with symptom severity in patients with pollen-induced allergic rhinitis and depended on exposure to allergen [5].

Spontaneous urticaria (SU) is a multifactorial disorder that may also depend on immune system activation [6,7]. SU may be classified on the basis of symptom duration as acute (ASU) and chronic (CSU), as stated by European and international guidelines [8]. The pathogenesis of SU is complex and remains partially unknown. Biomarkers are urgently needed for ASU and CSU. Therefore, it could be interesting to investigate the potential role of serum IL-9 in these cutaneous disorders. This preliminary study was designed to measure serum IL-9 levels in patients with ASU and CSU.

The study sample comprised 157 participants; 109 patients (52 males and 57 females; median age, 41 years) with SU and 48 healthy volunteers (22 males and 26 females; median age, 45.7 years). Blood samples were taken to assess serum IL-9 in all patients.

SU was diagnosed according to validated guidelines [8]: the exclusion criteria were diagnosis of physical, aquagenic, cholinergic, contact, and exercise-induced urticaria according to the tests recommended by these guidelines, as well as the presence of infections.

The severity of idiopathic urticaria was assessed using the

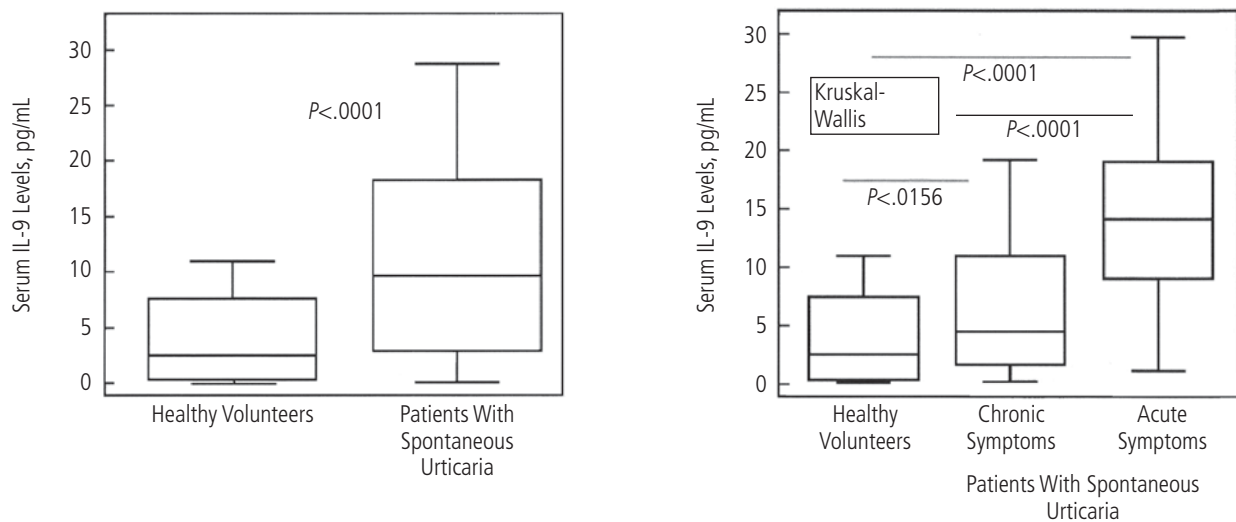


Figure. Left panel, serum IL-9 levels in healthy volunteers and in patients with spontaneous urticaria. Values are represented as median (white line) and IQR (black box). Right panel, serum IL-9 levels in healthy volunteers, patients with chronic symptoms, and patients with acute symptoms. Values are represented as median (white line) and IQR (black box). P values between the groups are shown.

urticaria activity score defined in the guidelines (4-point scale [0-3] for wheals and pruritus) [8].

Patients stopped topical or systemic therapy at least 2 weeks before the study began. The study was approved by the local ethics committee and performed with the written informed consent of all participants.

The human IL-9 reagent set (Human IL-9 ELISA Ready-SET-Go!, eBioscience) contains the reagents, buffers, and diluents necessary for performing quantitative enzyme linked immunosorbent assays, as previously reported [5].

Variables were expressed as median (IQR). The Wilcoxon signed rank test was used to compare samples. Serum IL-9 levels in both groups were analyzed using the Kruskal-Wallis test. All calculations were performed using Medcalc 9 (Frank Schoonjans, BE).

Median serum levels of IL-9 differed significantly between healthy volunteers (2.29 [0.35-7.5] pg/mL) and patients with SU (10.07 [2.85-17.49] pg/mL) ($P < .0001$) (Figure).

Participants were further classified into 3 groups: healthy volunteers (30.6%), patients with ASU (35.6%), and patients with CSU (33.8%). Serum IL-9 concentrations were significantly different between the groups (Kruskal-Wallis test, $P < .0001$) (Figure). In addition, patients with CSU had higher levels than controls ($P = .0156$), as did patients with ASU ($P < .0001$). There was a significant difference between patients with ASU and CSU ($P = .0001$), although no significant relationship was established between symptom severity and serum IL-9 levels (data not shown).

The recently identified T-cell subset T_H9 is characterized by the production of IL-9 [1,2]. However, IL-9 is also produced by T_H2 cells. Serum IL-9 has been shown to depend on allergen exposure in patients with allergic rhinitis [5]. The present pilot study was designed to investigate serum IL-9 levels in

SU patients. The findings show that serum IL-9 levels were significantly higher in SU than in normal controls and that IL-9 levels depended on symptom duration, but not on symptom severity. Indeed, patients with acute symptoms had the highest IL-9 levels. Although a pathogenic role has been suspected for IL-9 in patients with rhinitis, we present the first preliminary evidence that IL-9 is increased in patients with SU and could depend on symptom duration. However, further studies should be conducted to define a possible pathogenic role of IL-9 in SU and to investigate whether medical treatment could influence IL-9 levels.

The present study demonstrates that acute urticaria is characterized by high levels of IL-9, thus supporting the notion that IL-9 could be involved in the acute phase of inflammatory disorders.

In conclusion, this preliminary study reports that serum IL-9 levels are increased in patients with SU and depend on symptom duration.

Acknowledgments

The authors wish to thank Cristina Torre for outstanding technical support and Serena Buzzacchino for data analysis.

References

1. Akdis CA. T cells in health and disease. *J Allergy Clin Immunol*. 2009;123:1022-3.
2. Akdis CA, Akdis M. Mechanisms and treatment of allergic disease in the big picture of T regulatory cells. *J Allergy Clin Immunol*. 2009;123:735-46

3. Dardalhon V, Awasthi A, Kwon H, Galileos G, Gao W, Sobel RA, Mitsdoerffer M, Strom TB, Elyaman W, Ho IC, Khoury S, Oukka M, Kuchroo VK. IL-4 inhibits TGF-beta-induced Foxp3+ T cells and, together TGF-beta, generates IL-9+ IL-10+ Foxp3(-) effector T cells. *Nat Immunol.* 2008;9:1347-55
4. Nouri-Aria KT, Pilette C, Jacobson MR, Watanabe H, Durham SR. IL-9 and c-Kit+ mast cells in allergic rhinitis during seasonal allergen exposure: effect of immunotherapy. *J Allergy Clin Immunol.* 2005;116:73-9
5. Ciprandi G. Serum IL-9 in allergic rhinitis. *Annals Allergy Asthma Immunol.* 2010;104:180-1
6. Kaplan AP, Greaves M. Pathogenesis of chronic urticaria. *Clin Exp Allergy.* 2009;39:777-87
7. Hidvégi B, Nagy E, Szabó T, Temesvári E, Marschalkó M, Kárpáti S, Horváth A, Gergely P. Correlation between T-cell and mast cell activity in patients with chronic urticaria. *Int Arch Allergy Immunol.* 2003;132:177-82.
8. Zuberbier T, Asero R, Bindslev-Jensen C, Canonica G, Church MK, Giménez-Arnau A, Grattan CE, Kapp A, Maurer M, Merk HF, Rogala B, Saini S, Sánchez-Borges M, Schmid-Grendelmeier P, Schünemann H, Staubach P, Vena GA, Wedi B; Dermatology Section of the European Academy of Allergology and Clinical Immunology; Global Allergy and Asthma European Network; European Dermatology Forum; World Allergy Organization. EAACI/GA(2)LEN/EDF/WAO guideline: definition, classification and diagnosis of urticaria. *Allergy.* 2009;64:1417-26.

■ Manuscript received January 31, 2012; accepted for publication February 28, 2012.

Giorgio Ciprandi, MD
 Viale Benedetto XV 6
 16132 Genoa, Italy
 E-mail: gio.cip@libero.it

Can Birdseed Contribute to the Spread of Ragweed?

M Thibaudon,¹ C Colonnello,¹ JP Besancenot,¹ Y Toloba,² H François,² D Caillaud²

¹French Network of Aerobiological Monitoring, Brussieu, France

²Pulmonary-Allergology Department, University Hospital, Clermont-Ferrand, France

Key words: Ragweed. Birdseed. Contamination. Spread. Invasive plant.

Palabras clave: Ambrosia. Alimento de pájaros. Contaminación. Plantas invasivas.

Invasive plant species represent a growing threat to the economy, public health, and ecological integrity of many countries. Explaining and predicting the pathways and means of dispersal of these species is essential to ensure prevention and early warning efforts. The present paper addresses *Ambrosia artemisiifolia* L. (common ragweed). This annual plant is a well-documented cause of late-summer allergic rhinitis and seasonal asthma [1]. Native to North America, it entered Europe accidentally during the 19th century and has gradually colonized cultivated fields, wasteland, roadsides, building sites, and disturbed soils, mainly owing to its large seed production. The seeds are very small, not exceeding 3.5-6 mm in their greater dimension, and are difficult to remove from contaminated crop seeds. Their quantity varies widely, although 60 000 per individual seems to be the maximum. Furthermore, they may remain dormant and germinable for decades. Several studies from different countries [2-6] have implicated commercially available bird feed as a possible vector in the dissemination of ragweed in noninvaded areas: for example, 42% of the ragweed populations existing in Bavaria in 2008 could have been introduced with contaminated seeds used for feeding wild and caged birds. Indeed, not many authors assume that the role of pet food has been overestimated to date [7]. In Germany, contamination of retail birdseed mixtures ranges from 0 to 34 seeds per kilogram, with a mean value of 23.8 and an exceptional maximum value of 170 [4]. In France, Chauvel et al [8] quantified the amount of ragweed seeds in sunflower seeds (*Helianthus annuus* L.) and found that if the results varied with the origin of the samples, sunflower for bird feed, more than for crop, was able to spread ragweed seeds, with a viability estimated at about 10%.

However, the situation seems to be improving, for 3 reasons [4]. First, many authors assume that the standards, regulations, and directives promulgated for sunflower seeds intended for cultivation, with a ban on the marketing of batches containing more than 5 alien seeds (all species) per kilogram, would have a knock-on effect on birdseed producers. Second, even if European Union legislation does not set maximum levels of ragweed seed in feedstuffs, since the early 2000s various nonbinding texts have encouraged efforts to achieve the specific purity of birdseed, especially in areas with high

Table. Results of Monitoring of the Ragweed Seeds From 8 Bags of Bird Feed

Sample	Packaging, kg	Number of Seeds in the Package	Number of Ragweed Seeds	Percentage of Ragweed Seeds in Weight/Amount	Number of Seeds Put up to Germinate	Number of Seeds Having Germinated
A	1	61 400	41	0.12/0.07	10	3
B	1.5	21 915	61	0.35/0.28	10	0
C	2	47 620	56	0.13/0.12	10	1
D	3	57 840	22	0.18/0.04	10	0
E	1.25	19 438	5	0.06/0.03	5	0
F	2	46 160	1	0/0.002	1	0
G	0.75	12 458	0	0/0	0	0
H	1.5	21 960	0	0/0	0	0

densities of *Ambrosia* [9]. Third, several countries have already enacted specific legislation: in Switzerland, for instance, since March 2005, commercially available birdseed, whether locally produced or imported, has to be free of ragweed seeds [2]. We examine the situation in France in 2010-2011. In addition, as practically all previous studies are published in botanical, ecological, or agronomical journals, this short paper presents our findings to the allergy community.

Eight bags of birdseed of different brands were bought in several types of shops (eg, small businesses, shopping malls, garden centers). Seven of these bags, referred to below as B to H, contained only sunflower seeds, while the eighth, referred to as A, contained mixed seeds. The content of each bag was passed through 2 punched sieves, the upper sieve having a mesh size of 6.3 mm and the lower sieve a mesh size of 1.6 mm, thereby separating the sample into 3 parts depending on the particle size. The diaspores and their fragments were then identified by their morphological characteristics, both with the naked eye and with the help of a binocular magnifying glass. All the seeds were counted and weighed. When their number allowed, 10 were placed to germinate in Petri dishes near a window and watered every day.

The Table indicates that the presence of ragweed seeds in bird feed varied considerably from one brand to another. Bags G and H did not contain any seed. Bags E and F were very slightly contaminated, with ratios of 0.03% and 0.002%, respectively; however, bags A to D had slightly more ragweed, with ratios of 0.04% to 0.28%. Moreover, 4 out of the 46 seeds that were planted (9%) germinated successfully.

If our germination ratio is close to the estimation of Chauvel et al [8] and almost 5 times higher than that of Vitalos and Karrer [7], the contamination ratio is much lower than that reported in the literature. A possible explanation is that our experiment was conducted on bags packaged very recently (end of 2010), thus verifying, albeit to a slight extent, the hypothesis that more effective processing is applied to birdseed today at harvest time. Nevertheless, even if the proportion of seeds is not significant in terms of amount or in terms of weight, contamination with ragweed is sufficient to be a potential source for dispersal, especially since almost 1 seed out of 10 is able to germinate.

Seeds used in livestock farming have to be ground and exposed to heat and/or high pressure. These processes eliminate 99% of viable seeds [10]. However, bird feed is not yet treated in any way by the feed industry to destroy all the seeds of harmful plants. Therefore, our results point to the need for tougher laws. Advances are being made. In France, a bill dated July 13, 2011 suggested limiting the level of ragweed seeds in bird feed. At the same time, on June 16, 2011, the European Commission enacted regulation No. 574/2011 concerning the tolerable level of undesirable substances in animal feed, including birdseed: the maximum content was fixed at 3000 ppm (ie, 3000 mg/kg) for weed seeds in general and at 50 ppm for *Ambrosia* species. The provisions regarding ragweed became applicable on January 1, 2012. However, the most suitable measure would probably be to authorize the production of birdseed only in noninvaded areas.

Acknowledgments

All the authors certify that they have no actual or potential conflicts of interest in relation to this article. They did not receive any funding for the present study.

References

1. Laaidi M, Laaidi K, Besancenot JP, Thibaudon M. Ragweed in France: an invasive plant and its allergenic pollen. *Ann Allergy Asthma Immunol.* 2003;91:195-201.
2. Bohren C. *Ambrosia artemisiifolia* L. in Switzerland: concerted actions to prevent further spreading. *Nachrichtenbl Dtsch Pflanzenschutzd.* 2006;58:304-8.
3. Brandes D, Nitzsche J. Biology, introduction, dispersal, and distribution of common ragweed (*Ambrosia artemisiifolia* L.) with special regard to Germany. *Nachrichtenbl Dtsch Pflanzenschutzd.* 2006;58:286-91.
4. Van Denderen PD, Tamis WLM, Van Valkenburg JLCH. Risks of introduction of alien plant species, particularly from the genus *Ambrosia*, via seeds imported for fodder and birdseed. *Gorteria.* 2010;34:65-85.

5. European Food Safety Authority. Scientific Opinion on the effect on public or animal health or on the environment on the presence of seeds of *Ambrosia* spp. in animal feed. EFSA Journal. 2010;8:1-37.
6. Hackl G, Reichhart U, Baumgarten A. Studies on the relevance of common ragweed (*Ambrosia artemisiifolia* L.) in seed, birdseed and compost. In: Bohren C, Bertossa M, Schoenenberger N, Rossinelli M, Conedera M. 3rd International symposium on weeds and invasive plants. Ascona: European Weed Research Society; 2011; p. 123.
7. Vitalos M, Karrer G. Distribution of *Ambrosia artemisiifolia* L. – is birdseed a relevant vector? J Plant Dis Prot. 2008;21(sp.):345-8.
8. Chauvel B, Vieren E, Fumanal B, Bretagnolle F. Possibilité de dissémination d'*Ambrosia artemisiifolia* L. via les semences de tournesol. In: XIIème colloque international sur la biologie des mauvaises herbes. Paris: ANPP; 2004. p. 445-52.
9. European Food Safety Authority. Opinion of the Scientific Panel on plant health on the pest risk assessment made by Poland on *Ambrosia*. EFSA Journal. 2007;528:1-32.
10. Cash S, Zamora D, Lenssen A. Viability of weed seeds in feed pellet processing. J Range Manage. 1998;51:181-5.

■ *Manuscript received February 14, 2012; accepted for publication February 28, 2012.*

Jean-Pierre Besancenot

RNSA
Le Plat du Pin
69690 Brussieu
France

E-mail: jean-pierre.besancenot@wanadoo.fr