

Eosinophilic Gastroenteritis Due to Allergy to Cow's Milk

B Rodríguez Jiménez, J Domínguez Ortega, JM González García,
C Kindelan Recarte

¹Unidad de Alergia, Hospital Universitario de Getafe, Madrid, Spain

■ Abstract

Eosinophilic gastroenteritis is an uncommon condition that is characterized by infiltration of the gastrointestinal tract by eosinophils. We report the case of a 24-year-old woman who presented 4 episodes of eosinophilic gastroenteritis. Skin prick tests and patch tests with different allergens were all negative. The patient's eosinophil cationic protein (ECP) level was very high. Given that one of the most common causes of this condition is allergy to cow's milk, ECP levels were determined during a diet with and without cow's milk. ECP levels were considerably elevated during the diet with milk, although they returned to normal values several months after milk was withdrawn. The favorable clinical outcome and normalization of ECP levels point to a very probable association with cow's milk in the eosinophilic gastroenteritis presented by our patient.

Key words: Food allergy. Eosinophil. Eosinophilic gastroenteritis. Eosinophil cationic protein.

■ Resumen

La gastroenteritis eosinofílica es una entidad poco frecuente, caracterizada por la infiltración de eosinófilos en el tracto gastrointestinal. Presentamos el caso de una mujer de 24 años, que ha presentado 4 episodios de gastroenteritis eosinofílica. Las pruebas en prick y epicutáneas con distintos alérgenos, fueron negativas. Los niveles de la proteína catiónica del eosinófilo (ECP) estaban elevados. Puesto que una de las causas más frecuentes de esta patología es la alergia a leche de vaca, se determinaron los niveles de ECP durante una dieta con y sin leche. Los niveles de ECP, que se encontraban considerablemente elevados durante la dieta con leche, alcanzaron la normalidad después de varios meses de retirada de la leche de la dieta de la paciente. La buena evolución clínica y la normalización de los niveles de ECP, indican una muy probable relación de la leche de vaca en la gastroenteritis eosinofílica presentada por la paciente.

Palabras clave: Alergia a alimentos. Eosinófilo. Gastroenteritis eosinofílica. Proteína catiónica del eosinófilo.

Introduction

Eosinophilic gastroenteritis is an uncommon inflammatory disease characterized by patchy eosinophilic infiltration in the gastrointestinal tract [1]. It affects both children and adults, in whom it most commonly presents between the third and fifth decades of life [2].

Its etiology is unknown. However, it may have an allergic origin, since most patients are sensitized to environmental allergens, and up to 62% of cases are sensitized to food [3]. A considerable clinical and histologic improvement has been observed after elimination diets, elemental amino acid diets, or both [4].

The clinical manifestations of eosinophilic gastroenteritis vary depending on location and degree of involvement of the

different layers of the digestive tract. Accordingly, eosinophilic gastroenteritis has been classified as mucosal, submucosal (muscle), and serosal [5]. Mucosal involvement is the most common and develops with nausea, vomiting, abdominal pain, diarrhea, and weight loss. Involvement of the submucosal layer is accompanied by symptoms of intestinal obstruction, which may be complicated by intestinal perforation. Serosal involvement is less common and is characterized by intense peripheral eosinophilia, eosinophilic ascites, and a rapid response to treatment with corticosteroids [6]. Relapses are frequent; therefore, repeated treatment with corticosteroids is occasionally necessary. Clinical and histologic resolution has been reported after more than 2 years' therapy with montelukast [7]. As is the case in eosinophilic esophagitis, elimination diets and elemental diets have led to a clear improvement in some patients [2,8]

Case Description

A 24-year-old woman with no history of allergy was referred to the allergology department after experiencing 4 episodes of eosinophilic gastroenteritis. In the first episode, when she was 14 years old, she presented with a 4-day history of abdominal pain, diarrhea, vomiting, and abdominal distension. She was admitted for a workup, and basic biochemistry analysis revealed eosinophilia (5490/ μ L). Upper digestive endoscopy revealed a defect of gastric motility and patchy antral mucosa with reddish areas and thickened duodenal folds. Analysis of biopsy specimens of the stomach and duodenum revealed inflammatory abnormalities, with eosinophilic infiltration. Ultrasound scan of the abdomen revealed free intraperitoneal and intra-abdominal fluid, with thickened bowel loops in the small intestine and minimal ascites (Figure 1). Cytology of ascitic fluid showed an intense eosinophilic effusion.

Testing for parasites in stool, *Toxocara canis* serology testing, and hydatid cyst determination were negative. The patient was treated with oral corticosteroids (prednisolone 1 mg/kg/d) for 6 weeks, after which time her symptoms resolved. The following 3 episodes had similar clinical characteristics and were treated with oral corticosteroids administered on an outpatient basis. During the last episode, 1 month before presenting at our center, the patient had peripheral blood eosinophilia (10,450/ μ L). She did not have to be admitted to hospital, although oral corticosteroids were started for 8 weeks.

At the allergology unit, the patient underwent skin prick tests with commercial extracts of the most common pollens in our area, profilin, Pru p 3 quantified peach extract (30 μ g/mL) (ALK-Abelló, Madrid, Spain), and a battery of commercial food extracts including egg, milk, cereals, fish, fruit, nuts, pulses, and meat (Leti, Barcelona, Spain). All the results were negative. Patch testing was performed with cow's milk, egg white and yolk, wheat and rice flour, soya, lentil, and bovine serum albumin (Diater, Madrid, Spain). All the results were negative.

Total immunoglobulin (Ig) E was 458 kU_A/L. Specific IgE was determined (CAP System, Phadia, Uppsala, Sweden) for cow's milk, casein, α -lactalbumin and β -lactoglobulin. All results were negative. When the treatment with corticosteroids had finished, eosinophil cationic protein (ECP) was 20.30 μ g/L (CAP System). Serum ECP 3 months after the end of treatment with corticosteroids was 102 μ g/L. Given that a high percentage of cases of eosinophilic gastroenteritis are associated with food allergy [2,3,9]—cow's milk is the allergen in up to 61% of cases, followed by peanut and egg [3]—we decided to put our patient on a cow's milk-free diet and prescribe a 4-week course of corticosteroids. Two months later, serum ECP levels were 51 μ g/L. We reintroduced cow's milk into the patient's diet, and 4 weeks later she presented a serum ECP level of 183 μ g/L. From that point onward, the patient eliminated cow's milk from her diet. After 4 months on the elimination diet with no corticosteroid therapy, her ECP levels were normal (Figure 2).

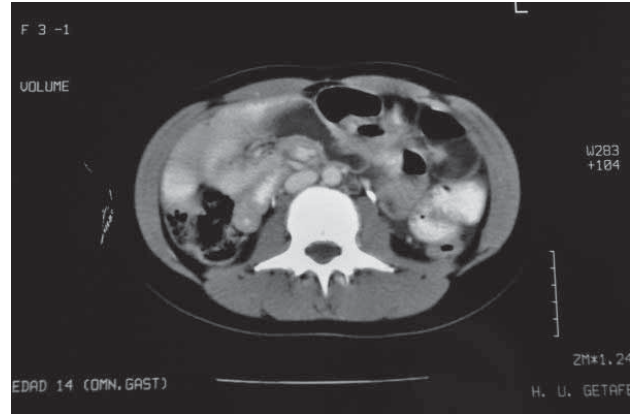


Figure 1. Abdominal computed tomography image of the first episode of eosinophilic gastroenteritis showing thickening in the small bowel wall and ascites.

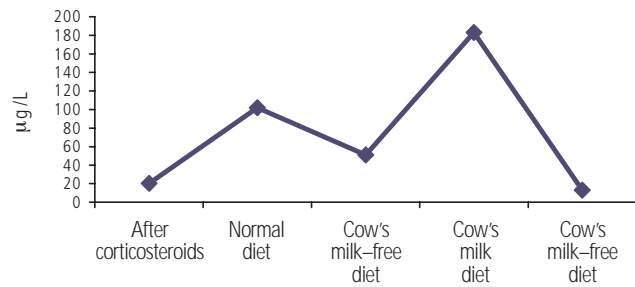


Figure 2. Evolution of serum eosinophil cationic protein during treatment.

Discussion

Eosinophilic gastroenteritis is a rare disease. Not many cases have been reported, in contrast to eosinophilic esophagitis, whose prevalence has been increasing in recent years. The pathogenesis of eosinophilic gastroenteritis is unknown, although it seems that eosinophils play an important role in the mechanism of tissue injury. In 1985, Keshavarzian et al [10] used an anti-ECP monoclonal antibody to show that activated eosinophils were present in biopsy specimens from patients with eosinophilic gastroenteritis.

The patient's first symptoms appeared at 14 years of age. However, her condition was not diagnosed until histologic evidence of eosinophilic infiltration was available. This approach is sometimes difficult, since the distribution of the disease is patchy, with the result that several biopsy specimens are necessary before the diagnosis can be confirmed. Therefore, we decided to monitor ECP levels before and after the elimination diet. It is noteworthy that the patient's ECP level returned to normal values by merely removing cow's milk from her diet, with no need for corticosteroids.

Although a new biopsy would be advisable to confirm reduction of the inflammatory infiltrate, favorable progress of symptoms and a return to normal ECP levels point to an association with cow's milk. Unfortunately, as the patient felt well, she refused to undergo a new endoscopic evaluation.

Determination of serum ECP could render serial endoscopy unnecessary in the evaluation of disease progression and the association with specific foods. However, measurement of ECP in blood requires clear standardization of sampling procedures, as concentrations of assessed cationic proteins are influenced by many factors (incubation temperature, time of the day when blood samples are extracted, recovery time) [11].

We still need to analyze the long-term outcome of these patients; therefore, studies with larger samples and longer follow-up are necessary.

Acknowledgements

No external funding was required for the present study.

References

1. Sheikh RA, Prindiville TP, Pecha RE, Ruebner BH. Unusual presentations of eosinophilic gastroenteritis: Case series and review of literature. *World J Gastroenterol.* 2009;15:2156-61.
2. Chen MJ, Chu CH, Lin SC, Shih SC, Wang TE. Eosinophilic gastroenteritis: Clinical experience with 15 patients. *World J Gastroenterol.* 2003;9:2813-16.
3. Guajardo JR, Plotnick LM, Fende JM, Collins MH, Putnam PE, Rothenberg ME. Eosinophilic-associated gastrointestinal disorders: A world-wide-web based registry. *J Pediatr.* 2002;141:576-81.
4. Rothenberg ME. Eosinophilic Gastroenteropathies. In: Middleton's Allergy: Principles and Practice. Elsevier Inc. Philadelphia; 2009:879-93.
5. Klein NC, Hargrove RL, Sleisenger MH, Jeffries GH. Eosinophilic gastroenteritis. *Medicine (Baltimore).* 1970;49:299-319.
6. Talley NJ, Shorter RG, Phillips SF, Zinsmeister AR. Eosinophilic gastroenteritis: A clinicopathological study of patients with disease of the mucosa, muscle layer and subserosal tissues. *Gut.* 1990;31:54-8.
7. Quack I, Sellin L, Buchner NJ, Theegarten D, Rump LC, Henning BF. Eosinophilic gastroenteritis in a young girl—long term remission under Montelukast. *BMC Gastroenterology* 2005;5:24-8.
8. Armisen M, Vidal C, López-Rosés L, Rodríguez V, Bartolomé B. Eosinophilic esophagitis due to allergy to sheep and goat milk proteins. *Rev Esp Enferm Dig.* 2008;1:53-6.
9. Khan S. Eosinophilic gastroenteritis. *Best Pract Res Clin Gastroenterol.* 2005;19:177-98.
10. Keshavarzian A, Saverymattu SH, Tai PC, Thompson M, Barter S, Spry CJF, Chadwick VS. Activated Eosinophils in Familial eosinophilic Gastroenteritis. *Gastroenterology.* 1985;88:1041-9.
11. Bischoff SC. Food allergy and eosinophilic gastroenteritis and colitis. *Curr Opin Allergy Clin Immunol.* 2010;10:238-45.

■ *Manuscript received May 10, 2010; accepted for publication July 28, 2010.*

■ **Beatriz Rodríguez Jiménez**

Allergy Unit
Hospital Universitario de Getafe
Carretera de Toledo Km 12,500
28905 Getafe (Madrid), Spain
E-mail: alergologia.hugf@salud.madrid.org