

Prothrombotic State in Churg-Strauss Syndrome: A Case Report

AV Marzano,¹ A Tedeschi,² R Rosso,³ D Fanoni,¹ M Cugno³

¹U.O. Dermatologia, Università degli Studi di Milano, Fondazione IRCCS Ca' Granda - Ospedale Maggiore Policlinico, Milano, Italy

²U.O. Allergologia e Immunologia Clinica, Fondazione IRCCS Ca' Granda - Ospedale Maggiore Policlinico, Milano, Italy

³Dipartimento di Medicina Interna, Università degli Studi di Milano, Fondazione IRCCS Ca' Granda - Ospedale Maggiore Policlinico, Milano, Italy

■ Abstract

An increased risk of thrombosis has been described in patients with hypereosinophilic syndromes, including Churg-Strauss syndrome (CSS). We report the case of a 43-year-old man with CSS who presented with asthma, pansinusitis, blood eosinophilia (9650/ μ L), peripheral neuropathy, cutaneous eosinophilic vasculitis, and a positive result for antineutrophil cytoplasmic antibodies. An analysis of plasma during active disease revealed elevated levels of prothrombin fragment 1+2 (marker of thrombin generation) (832 pM; normal range, 68-229 pM) and D-dimer (marker of fibrin degradation) (2300 ng/mL; normal range, 130-250 ng/mL), which indicate an increased risk of thrombosis. Both parameters returned to normal values during remission after immunosuppressive treatment. Skin histology showed leukocytoclastic vasculitis with numerous eosinophils in the dermal infiltrate. Immunohistochemistry revealed expression of tissue factor by skin-infiltrating eosinophils, as confirmed by colocalization with eosinophil cationic protein, a classic marker of eosinophil granulocytes. In conclusion, we present a patient with active CSS and a prothrombotic state that reverted during remission achieved by immunosuppressive therapy.

Key words: Churg-Strauss syndrome. Eosinophil. Tissue factor. Thrombosis.

■ Resumen

Se ha descrito un mayor riesgo de trombosis en los pacientes con síndromes hipereosinófilos, incluido el síndrome de Churg-Strauss (SCS). Se presenta el caso de un hombre de 43 años de edad con SCS y asma, pansinusitis, eosinofilia sanguínea (9.650/mm³), neuropatía periférica, vasculitis eosinófila cutánea y presencia de anticuerpos anticitoplasma de neutrófilos p-ANCA. Un análisis de plasma realizado durante la fase activa de la enfermedad reveló niveles elevados del fragmento 1+2 de la protrombina (marcador de la generación de trombina) (832 pM; intervalo normal, 68-229 pM) y dímero D (marcador de degradación de fibrina) (2.300 ng/ml; intervalo normal, 130-250 ng/ml), lo que indica un alto riesgo de trombosis. Ambos parámetros recuperaron los valores normales durante la remisión tras el tratamiento inmunodepresor. La histología cutánea mostró vasculitis leucocitoclástica con numerosos eosinófilos en el infiltrado dérmico. La inmunohistoquímica reveló expresión del factor tisular por infiltración de eosinófilos en la piel, según se confirmó mediante colocalización con proteína catiónica eosinófila, un marcador clásico de inflamación en el asma. En conclusión, se presenta un paciente con SCS activo y estado protrombótico que revirtió durante la remisión alcanzada con el tratamiento inmunosupresor.

Palabras clave: Síndrome de Churg-Strauss. Eosinófilo. Factor tisular. Trombosis.

Introduction

Peripheral blood eosinophilia (defined as a persisting eosinophil count >1500/ μ L) has been associated with an increased risk of venous and arterial thromboembolic events [1-3]. One-quarter of patients with hypereosinophilic syndromes develop thromboembolic complications and 5% to 10% die [3].

Hypereosinophilia is a characteristic of Churg-Strauss syndrome (CSS), a systemic vasculitis involving small vessels (ie, arterioles, venules, and capillaries) and affecting several organs and systems. CSS is a rare disorder with an annual incidence of 2.7 cases/million [4]. It usually starts with asthma, often accompanied by allergic rhinitis and sinusitis, before progressing to peripheral and tissue eosinophilia and eventually resulting in overt vasculitis [5]. The survival rate of CSS ranges

from 68% to 100% at 5 years [6]. Although there have been several reports of an association between CSS and thrombosis [7-9], little is known about the link between CSS and the activation of blood coagulation, a mechanism involved in the pathogenesis of thrombosis. Recently, eosinophils were shown to be a major intravascular source of tissue factor (TF), the main initiator of the coagulation cascade [10]. TF expression by skin-infiltrating eosinophils has been associated with systemic markers of coagulation activation in autoimmune cutaneous disorders and may account for an increased risk of thrombosis in at least one of these, namely, bullous pemphigoid [11,12]. Therefore, it is conceivable that eosinophil-derived TF also plays a role in the mechanism leading to thrombosis in patients with CSS or hypereosinophilic syndrome. We report the case of a 43-year-old man with classic CSS showing activation of the coagulation cascade in plasma and expression of TF by skin-infiltrating eosinophils.

Case Description

A 43-year-old man attended our clinic because of purpura and papulonodular skin lesions on both legs. These lesions had appeared 3 months earlier and were becoming necrotic and ulcerous. The patient had no history of smoking, drinking, or allergy, although he reported having suffered from asthma during the previous 3 years. He had been hospitalized in another institution 2 years earlier because of multiple pulmonary infiltrates and was successfully treated with levofloxacin and intravenous methylprednisolone. At that time, laboratory investigations revealed leucocytosis (21 300/ μ L to 14 900/ μ L) with eosinophilia (63.7% to 41.1%), whereas renal, hepatic, and thyroid parameters were normal, as were tumor markers. Serology for the human immunodeficiency virus and hepatitis B and C were negative. He was discharged with formoterol 24 μ g bid, fluticasone 250 μ g qd, prednisone 12.5 mg qd, and omeprazole 20 mg qd.

At admission, his temperature was 36.3°C, pulse rate 78 bpm, and respiratory rate 15 breaths/min. Blood pressure was 130/75 mmHg. Physical examination revealed no abnormalities except in the legs. There was mild pitting edema associated with purpura on the lower legs. Papulonodular and ulcerative-necrotic skin lesions were present over the extensor surfaces of both legs (Figure 1). The patient also reported distal lower-limb symmetrical paresthesia and asthenia.

Laboratory analyses showed an increased white blood cell count (20 100/ μ L) with predominance of eosinophils (48%), normocytic anemia (hemoglobin, 12.2 g/dL), slightly elevated C-reactive protein (1.8 mg/dL), and positive perinuclear antineutrophil cytoplasmic antibodies (p-ANCA). We observed elevated plasma levels of prothrombin fragment 1+2 (marker of thrombin generation) (832 pM; normal range, 68-229 pM) and fibrin fragment D-dimer (2300 ng/mL; normal range, 130-250 ng/mL).

A skin biopsy was performed from a papular lesion and histology revealed leukocytoclastic vasculitis with a high number of eosinophils in the dermal inflammatory infiltrate (Figure 2). Immunohistochemical studies revealed expression

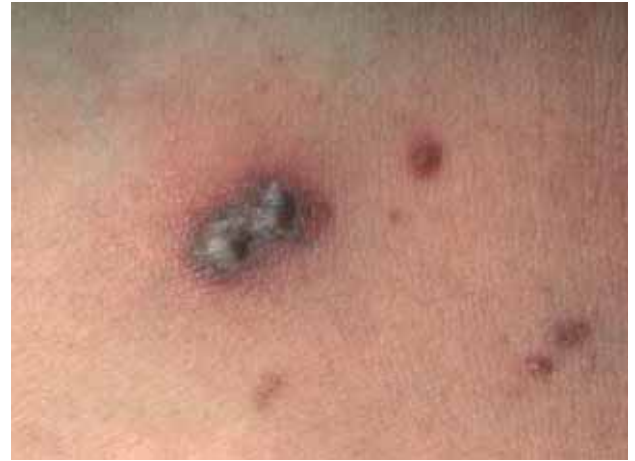

Figure 1. Papular purpuric and ulcerative-necrotic skin lesions.

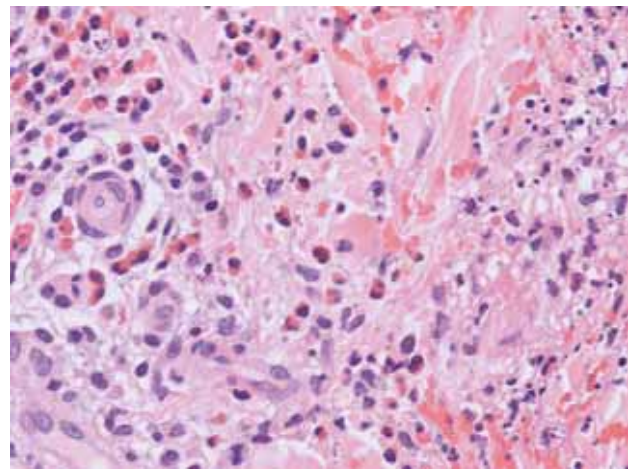


Figure 2. Histological study of a biopsy specimen from damaged skin in a patient with Churg-Strauss syndrome shows a mixed inflammatory infiltrate around a dermal small blood vessel with nuclear dust. The image is consistent with leukocytoclastic vasculitis. Notice the high number of eosinophils within the infiltrate (hematoxylin-eosin; original magnification, $\times 400$).

of TF in the dermal infiltrate, particularly around small blood vessels (Figure 3). Double staining experiments revealed that TF was colocalized with eosinophil cationic protein, a classic marker of eosinophil granulocytes.

A computed tomography (CT) scan of the head and face revealed pansinusitis. Thoracic CT showed multiple pulmonary infiltrates. Transthoracic echocardiography showed normal systolic and diastolic function with moderate mitral insufficiency. The results of nerve conduction velocity studies were normal for the upper limbs and revealed axonal sensorimotor neuropathy of the lower limbs.

Abdominal ultrasound was normal. Bone marrow biopsy specimens disclosed an increased number of eosinophilic myeloid cells.

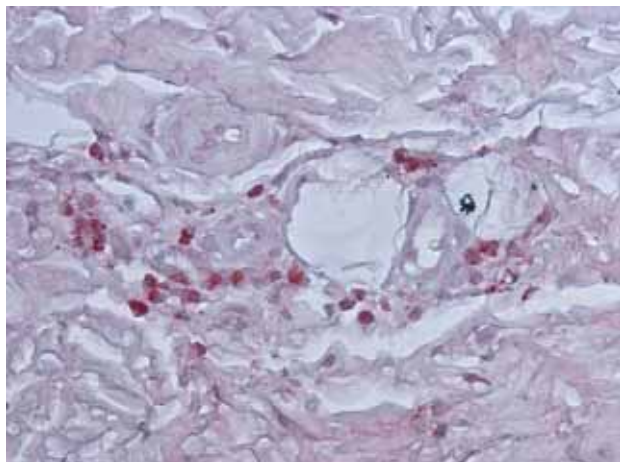


Figure 3. Immunohistochemical study of a biopsy specimen from the damaged skin of a patient with Churg-Strauss syndrome. Tissue factor is expressed in a granular pattern by dermal inflammatory cells morphologically resembling eosinophils (staining for tissue factor; original magnification, $\times 400$).

The diagnosis of CSS was made on the basis of the presence of asthma, pansinusitis, blood eosinophilia $>10\%$, peripheral neuropathy in association with ANCA positivity, and cutaneous eosinophilic vasculitis.

The patient was treated with intravenous methylprednisolone 500 mg daily for 3 consecutive days, followed by oral prednisone 1 mg/kg daily at progressively tapering dosages. The patient also received pulsed weekly therapy with intravenous cyclophosphamide (750 mg/m^2) for 6 weeks followed by azathioprine (100 mg qd) for 1 year. At the time of writing, the patient was in clinical remission with a blood eosinophil count lower than 10% and under maintenance therapy with oral prednisone at 7.5 mg daily. Plasma levels of prothrombin fragment 1+2 and D-dimer were normal (156 pM and 187 ng/mL, respectively).

Discussion

Thromboembolism is a frequent event in eosinophil-mediated disorders [1-3,7-9], and several hypotheses have been proposed to link eosinophilia and thrombosis, involving endothelium damage, and activation of platelets and coagulation. Endothelial cells may be damaged by eosinophil peroxidase products. Moreover, peroxidase and several additional proteins contained in eosinophil granules, such as eosinophil cationic protein and major basic protein, can stimulate platelet activation and aggregation [13]. Eosinophils express CD40 ligand, which is involved in initiation and progression of thrombosis through amplification of the inflammatory network [13]. Finally, eosinophils store the coagulation initiator TF, which is mainly embodied within their specific granules and is exposed upon eosinophil activation [10]. TF exposure can facilitate transendothelial migration of eosinophils and trigger activation of the extrinsic pathway of blood coagulation,

thus leading to a prothrombotic state. Our previous studies demonstrated expression of TF by eosinophils in damaged skin and plasma markers of coagulation activation in patients with active bullous pemphigoid, an autoimmune blistering disorder characterized by eosinophil-rich inflammatory infiltrate and increased thrombotic risk [11,12].

Immunohistochemical analysis of skin biopsy specimens in our patient revealed expression of TF by dermal inflammatory cells with an eosinophilic distribution pattern (Figures 2 and 3). Expression of TF in eosinophils was confirmed by colocalization experiments using specific antibodies to TF and eosinophil cationic protein, a classic marker of eosinophil granulocytes. The study of our patient's plasma during active disease revealed elevated levels of prothrombin fragment 1+2 and D-dimer, which indicate a high risk of thrombosis [14,15]. Both parameters returned to normal values when the patient was re-evaluated in clinical remission following immunosuppressive treatment.

In conclusion, we report a patient with CSS showing TF expression by skin-infiltrating eosinophils along with elevated plasma levels of prothrombin fragment 1+2 and D-dimer during active disease. Both parameters indicate a prothrombotic state that reverted after clinical remission achieved using immunosuppressive therapy.

References

1. Liao YH, Su YW, Tsay W, Chiu HC. Association of cutaneous necrotizing eosinophilic vasculitis and deep vein thrombosis in hypereosinophilic syndrome. *Arch Dermatol*. 2005;141:1051-3.
2. Liapis H, Ho AK, Brown D, Mindel G, Gleich G. Thrombotic microangiopathy associated with the hypereosinophilic syndrome. *Kidney Int*. 2005;67:1806-11.
3. Ogbogu P, Rosing DR, Horne MK III. Cardiovascular manifestations of hypereosinophilic syndromes. *Immunol Allergy Clin North Am*. 2007;27:457-75.
4. Watts RA, Lane SE, Bentham G, Scott DG. Epidemiology of systemic vasculitis: a ten-year study in the United Kingdom. *Arthritis Rheum*. 2000;43:414-9.
5. Noth I, Streck ME, Leff AR. Churg-Strauss syndrome. *Lancet*. 2003;361:587-94.
6. Phillip R, Luqmani R. Mortality in systemic vasculitis: a systematic review. *Clin Exp Rheumatol*. 2008;26:S94-104.
7. Guillevin L, Cohen P, Gayraud M, Lhote F, Jarrousse B, Casassus P. Churg-Strauss syndrome: clinical study and long-term follow-up of 96 patients. *Medicine (Baltimore)*. 1999;78:26-37.
8. Garcia G, Achouh L, Cobarzan D, Fichet D, Humbert M. Severe thromboembolic disease in Churg-Strauss syndrome. *Allergy*. 2005;60:409-10.
9. Allenbach Y, Seror R, Pagnoux C, Teixeira L, Guilpain P, Guillevin L, French Vasculitis Study Group. High frequency of venous thromboembolic events in Churg-Strauss syndrome, Wegener's granulomatosis and microscopic polyangiitis but not polyarteritis nodosa: a systematic retrospective study on 1130 patients. *Ann Rheum Dis*. 2009;68:564-7.
10. Moosbauer C, Morgenstern E, Cuvelier SL, Manukyan D, Bidzhekov K, Albrecht S, Lohse P, Patel KD, Engelmann B.

- Eosinophils are a major intravascular location for tissue factor storage and exposure. *Blood*. 2007;109:995-1002.
11. Marzano AV, Tedeschi A, Fanoni D, Bonanni E, Venegoni L, Berti E, Cugno M. Activation of blood coagulation in bullous pemphigoid: role of eosinophils, and local and systemic implications. *Br J Dermatol*. 2009;160:266-72.
 12. Marzano AV, Tedeschi A, Spinelli D, Fanoni D, Crosti C, Cugno M. Coagulation activation in autoimmune bullous diseases. *Clin Exp Immunol*. 2009;158:31-6.
 13. Lippi G, Montagnana M, Salvagno GL, Franchini M, Targher G, Guidi GC. Eosinophilia and first-line coagulation testing. *J Thromb Thrombolysis*. 2009;28:90-3.
 14. Ota S, Wada H, Abe Y, Yamada E, Sakaguchi A, Nishioka J, Hatada T, Ishikura K, Yamada N, Sudo A, Uchida A, Nobori T. Elevated levels of prothrombin fragment 1+2 indicate high risk of thrombosis. *Clin Appl Thromb Hemost*. 2008;14:279-85.
 15. Pabinger I, Ay C. Biomarkers and venous thromboembolism. *Arterioscler Thromb Vasc Biol*. 2009;29:332-6.

■ *Manuscript received March 24, 2010; accepted for publication May 6, 2010.*

■ **A Tedeschi**

U.O. Allergologia e Immunologia Clinica
Fondazione IRCCS Ca' Granda
Ospedale Maggiore Policlinico
Via Pace 9,
20122 Milano, Italy
E-mail: albited@alice.it