

Use of the Lymphocyte Transformation Test in the Diagnosis of DRESS Syndrome Induced by Ceftriaxone and Piperacillin-tazobactam: Two Case Reports

J Jurado-Palomo,¹ R Cabañas,¹ N Prior,¹ ID Bobolea,¹ AM Fiandor-Román,¹ MC López-Serrano,¹ S Quirce,¹ T Bellón²

¹Department of Allergology, Hospital Universitario La Paz, Madrid, Spain

²Hospital La Paz Health Research Institute-IdiPaz, Madrid, Spain

■ Abstract

Drug-related rash with eosinophilia and systemic symptoms (DRESS) syndrome, or drug-induced hypersensitivity syndrome (DIHS), is a life-threatening multiorgan systemic reaction characterized by rash, fever, lymphadenopathy, hepatitis, and leukocytosis with eosinophilia. Aromatic anticonvulsant drugs and allopurinol have been reported to be the most frequent eliciting agents. Our search of the literature revealed only 2 cases induced by piperacillin and 1 case by ceftriaxone. We present 2 cases of DRESS syndrome induced by the β -lactam drugs ceftriaxone and piperacillin-tazobactam. An allergological workup including skin prick test, intradermal tests, patch tests, and lymphocyte transformation test (LTT) was performed. LTT was shown to be a useful technique in both cases to help to identify the drugs involved.

Key words: Delayed hypersensitivity. Drug-related rash with eosinophilia and systemic symptoms syndrome. Lymphocyte transformation test. Ceftriaxone. Piperacillin-tazobactam.

■ Resumen

El síndrome de erupción cutánea, eosinofilia y síntomas sistémicos causado por fármacos (DRESS), también denominado síndrome de hipersensibilidad inducida por fármacos (DIHS) es una reacción sistémica grave amenazante para la vida caracterizada por erupción cutánea, fiebre, linfadenopatías, hepatitis y leucocitosis con eosinofilia. Los anticonvulsivantes del grupo aromático y el alopurinol son los fármacos que más frecuentemente lo provocan. Hasta ahora, sólo se habían publicado dos casos inducidos por piperacilina y uno por ceftriaxona. Se describen dos casos de DRESS inducidos por betalactámicos: ceftriaxona y piperacilina-tazobactam. Se llevó a cabo un estudio alergológico que incluía pruebas cutáneas mediante técnica de prick, intradermorreacción y/o pruebas epicutáneas y test de transformación linfocitaria (TTL). El TTL demostró ser una técnica útil en estos casos para ayudar a identificar los fármacos implicados.

Palabras clave: Hipersensibilidad retardada. Síndrome de erupción cutánea, eosinofilia y síntomas sistémicos, causado por fármacos. Test de transformación linfocitaria. Ceftriaxona. Piperacilina-tazobactam.

Introduction

Drug-related rash with eosinophilia and systemic symptoms (DRESS) syndrome, also known as drug-induced hypersensitivity syndrome (DIHS), is a life-threatening multiorgan systemic reaction characterized by rash, fever, lymphadenopathy, hepatitis, and leukocytosis with eosinophilia [1]. Aromatic

anticonvulsant drugs and allopurinol have been reported to be the most frequent eliciting agents. To our knowledge, only 2 cases induced by piperacillin [2,3] and 1 case induced by ceftriaxone [4] have been reported in literature. Although DRESS is reported throughout the world, it is underdiagnosed in many countries, probably due to a lack of awareness of the syndrome.

Case Description

Patient 1: A 40-year-old man was treated with ceftriaxone (2 g/12 h iv), phenytoin (100 mg/12 h), and metronidazole (100 mg/12 h) for status epilepticus due to a cerebral abscess. During the fourth week of treatment, he developed itching and a generalized erythematous rash affecting mainly his trunk and upper limbs, fever (38.3°C), and cervical lymphadenopathy. Blood tests revealed eosinophilia (19.4%, 1600/mm³) and an increase in liver enzyme levels (aspartate aminotransferase, 128 IU/L; alanine aminotransferase, 269 IU/L; gammaglutamyl transpeptidase, 295 IU/L). Ceftriaxone was stopped and phenytoin was gradually switched to valproic acid over 3 days. The patient was treated with systemic corticosteroids and antihistamines and continued treatment with metronidazole, valproic acid, and levofloxacin. He was afebrile after 24 hours and his symptoms resolved within 48 hours. Liver enzyme levels had decreased at the 48-hour evaluation and their values were normal 1 week later. As for eosinophilia, at 24 hours there was no change, and at 48 hours the value had decreased to 9.8% (1050/mm³). After 1 month it was 7.9% (850/mm³), and after 6 months no eosinophilia was detected (3.9%, 480/mm³). No eosinophilia was present on admission (2.3%, 500/mm³) before treatment with these drugs.

Two months later, the patient underwent an allergological workup at our clinic. Intradermal tests were performed with benzylpenicilloyl polylysine (PPL, 6×10^{-5} M) (DAP, Diater,

Madrid, Spain), minor determinant mixture (MDM, 10^{-2} M) (DAP, Diater), penicillin G (10 000 IU/mL), ceftriaxone, amoxicillin, and ampicillin (1-20 mg/mL), with a negative result. Patch tests were then performed with all these drugs at 10% in petrolatum, with negative readings at 48 and 96 hours. One year later, we also performed a lymphocyte transformation test (LTT) following the methodology of Pichler et al [5-7], with phenytoin, ceftriaxone, amoxicillin, and piperacillin-tazobactam added to the medium at concentrations ranging from 1 to 200 µg/mL, and phytohemagglutinin A (PHA) as a control mitogen. All tests were regularly performed in triplicate, with 6 days of incubation. A control culture without drugs was also performed. The stimulation index (SI) was calculated as proliferation with drug (cpm)/proliferation without drug (cpm). According to Pichler et al [7], LTT is considered positive if the SI is >3, particularly if the test is positive in more than 1 concentration. The LTT was clearly positive to ceftriaxone with an SI of 5.8 at 100 µg/mL and an SI of 8.5 at 200 µg/mL. There was no proliferation upon incubation with the other drugs tested (Figure 1).

Patient 2: A 43-year-old woman with ulcerative colitis was treated with piperacillin-tazobactam (4/0.5 g/12 h iv), metamizole (2 g/6 h iv), and paracetamol (1 g/6 h iv) after a pancolectomy. On the sixteenth day of treatment she developed itching and a generalized erythematous maculopapular rash (mainly affecting the trunk and limbs), fever (38°C), and

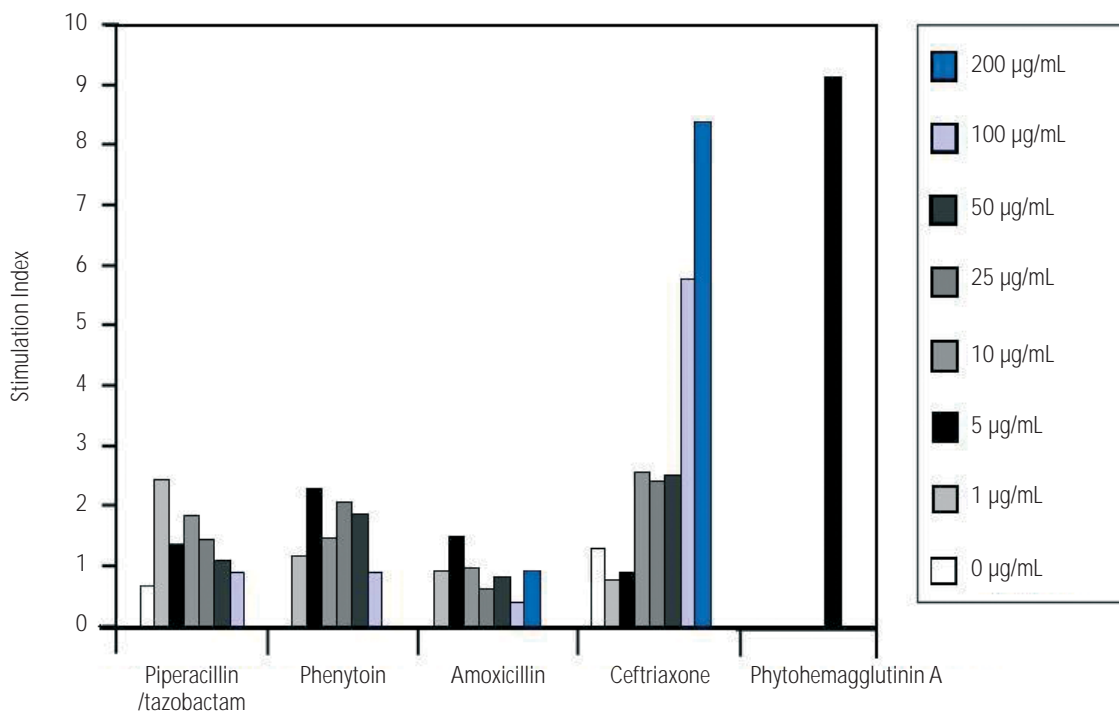


Figure 1. Proliferation of peripheral blood mononuclear cells from patient 1 upon stimulation with increasing concentrations of the drugs involved. The lymphocyte transformation test was performed according to Pichler et al [5,7]. The mean stimulation index of triplicate cultures is shown.

inguinal lymphadenopathy. A flare-up of her cutaneous symptoms was observed with the piperacillin-tazobactam infusion. Blood tests revealed eosinophilia 14.3% ($980/\text{mm}^3$), atypical lymphocytes, large granular lymphocytes, and increased liver enzymes (aspartate aminotransferase, 66 IU/L; alanine aminotransferase, 108 IU/L; gammaglutamyl transpeptidase, 605 IU/L). The patient was treated with antihistamines and systemic corticosteroids, piperacillin/tazobactam was stopped, and analgesic therapy was continued. Nevertheless, neither the rash nor the eosinophilia improved in the following 3 days, so treatment with metamizole was also stopped. Eosinophilia and liver enzymes started to decrease within 72 hours after withdrawal of the antibiotics and returned to normal values 1 week later, when the rash had also clearly improved.

Three months later the patient was studied in our allergy department. Patch tests were performed at 10% in petrolatum with piperacillin-tazobactam, penicillin G, penicillin V, amoxicillin, ampicillin, and metamizole. Readings at 48 and 96 hours were negative. Immunoglobulin G against human herpesvirus (HHV) 6 was detected by an enzyme-linked immunosorbent assay and titrated by indirect immunofluorescence. The result was positive (1/80).

An LTT was performed 3 months after the reaction according to the methodology of Pichler et al [5-7] and as described above for Patient 1, with metamizole, imipenem, amoxicillin, cefuroxime, and piperacillin-tazobactam. LTT was clearly positive to piperacillin-tazobactam with an SI >3 at 4 different concentrations: 3.3 at 1 $\mu\text{g}/\text{mL}$, 7.0 at 5 $\mu\text{g}/\text{mL}$, 14.3 at 100 $\mu\text{g}/\text{mL}$, and 25.8 at 200 $\mu\text{g}/\text{mL}$. There

was no proliferation upon incubation with the other drugs, including the other β -lactam drugs (Figure 2).

Discussion

We present 2 cases of DRESS syndrome induced by β -lactam drugs. A Japanese consensus group has established 7 criteria for diagnosis of this syndrome [1,8]: 1) maculopapular rash developing >3 weeks after initiating a limited number of drugs; 2) prolonged clinical symptoms; 3) fever; 4) leukocyte abnormalities (leukocytosis and/or atypical lymphocytosis and/or eosinophilia); 5) elevation of liver enzymes; 6) lymphadenopathy; and 7) reactivation of HHV-6 in the second to third week after the onset of symptoms. A probable diagnosis (atypical DRESS) requires the presence of 5 of these 7 criteria and a definitive diagnosis (typical DRESS) requires all 7.

We describe a case of atypical DRESS induced by ceftriaxone, ie, it fulfilled 5 of the 7 criteria mentioned above (namely, 1, 3, 4, 5, and 6). We were unable to determine HHV-6 reactivation in the second to third week, because the patient was referred for study 2 months after the reaction. As the neurologist decided not to disrupt treatment with phenytoin, but to gradually switch to valproic acid over 3 days, clinical improvement began when the patient was still taking phenytoin 100 mg/12 h; the patient received the last dose of phenytoin on the first day he was completely asymptomatic. This clinical improvement, together with the LTT results, supports the hypothesis that ceftriaxone—not phenytoin—was

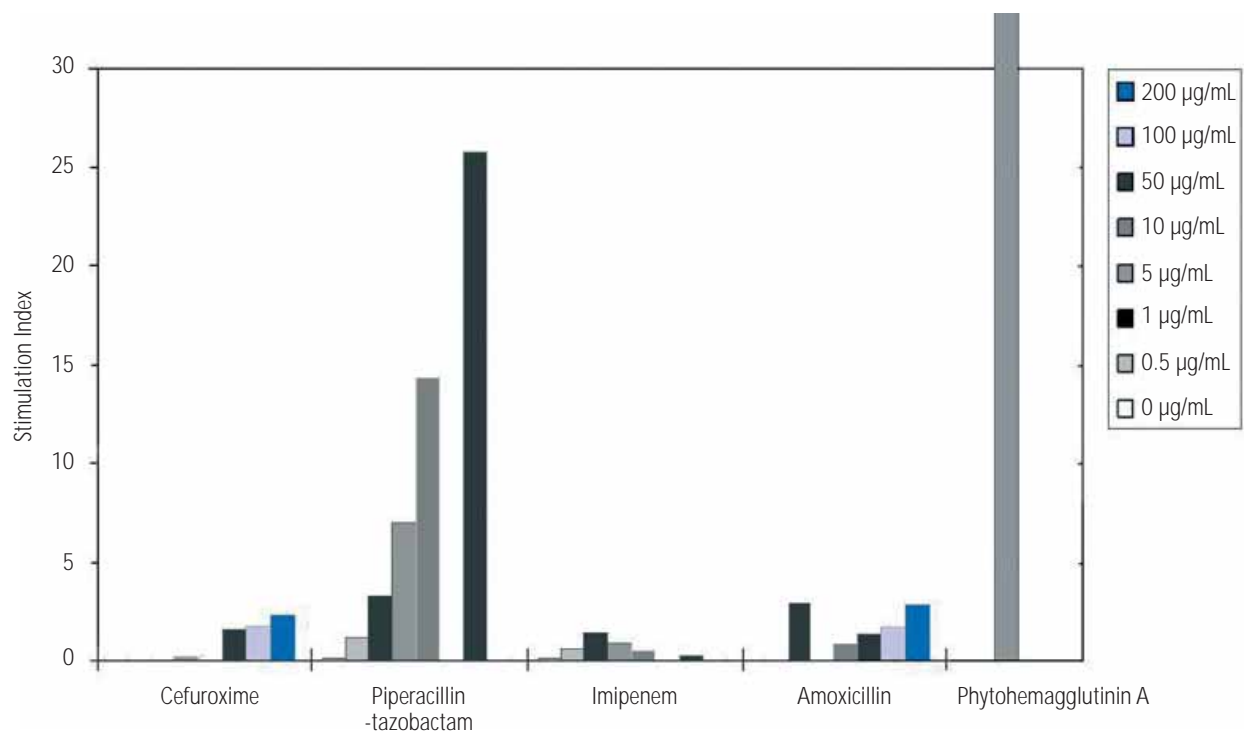


Figure 2. Proliferation of peripheral blood mononuclear cells from patient 2 upon stimulation with increasing concentrations of the drugs involved. The lymphocyte transformation test was performed according to Pichler et al [5,7]. The mean stimulation index of triplicate cultures is shown.

the responsible drug. Nevertheless, we advised the patient that if he ever needed to take phenytoin again, he should return to our clinic for controlled reintroduction of the drug.

We also describe atypical DRESS syndrome induced by piperacillin-tazobactam that fulfilled 6 of the 7 criteria. The first criterion was partially matched. The patient developed a rash, although onset was before the third week of treatment (day 16). This delay could differ with the culprit drug. As for reactivation of HHV-6, we made only 1 determination for this patient 9 months after the reaction and the result was positive (1/80); however, we do not really know if there was a reactivation in the second to third week after the onset of symptoms. The patient was studied in our allergy department 3 months after the reaction.

To our knowledge, there has been only 1 report of DRESS induced by ceftriaxone [4]. The patient suffered a severe skin rash with eosinophilia, atypical lymphocytosis, and fever 4 days after cessation of treatment with ceftriaxone, which he had been taking for 3 weeks. The findings in this case resolved after 3 days, and a quick recovery was also observed in our case. No allergological workup was performed.

In our case, LTT was useful in identifying the drug responsible for the reaction, ceftriaxone, although phenytoin is more often involved in DRESS. This result was positive when performed 1 year after the reaction. Shiohara et al [8] reported positive results in this test, even after 1 year. The fact that the result of the LTT performed with amoxicillin, piperacillin-tazobactam, and imipenem was negative highlights the selective positive response to ceftriaxone detected in our patient.

Cabañas et al [3] described a case of hypersensitivity to piperacillin. The patient had been treated with piperacillin-tazobactam and many other drugs. On his fourteenth day of treatment he developed itching and a generalized erythematous maculopapular rash, fever, and eosinophilia. After withdrawal of piperacillin-tazobactam and treatment with anti-H₁ and systemic corticosteroids, he recovered within a month, although with marked desquamation. The results of intradermal and skin prick tests with the drugs were negative. The results of patch tests with piperacillin/tazobactam, piperacillin 10%, and piperacillin 20% were positive; with the other drugs he had received, they were negative. Fahim et al [2] described drug hypersensitivity syndrome induced by piperacillin-tazobactam in 1 patient, with rash, facial edema, kidney and liver involvement, and lymphadenopathy, but with no eosinophilia. The patient's condition resolved with prednisone. No allergological workup was performed. In our case, LTT proved useful in identifying the drug involved in the reaction.

To date, neither ceftriaxone nor piperacillin-tazobactam has been included in the list of drugs producing DRESS (carbamazepine, phenytoin, phenobarbital, mexiletine, dapsone, salazosulfapyridine, allopurinol, minocycline, zonisamide, lamotrigine, abacavir, nevirapine) [8], although we feel that they should.

LTT helped to identify the drugs involved in both our cases. The technique has a general sensitivity in the range of 60-70% and an overall specificity of at least 85% [7].

A positive LTT result helps to define the culprit drug in the drug hypersensitivity reaction; however, as the sensitivity of the LTT is limited, a negative test result cannot exclude drug hypersensitivity [7]. Consequently, diagnosis of drug hypersensitivity should rely on a combination of history and different tests, as none of the single tests available has sufficiently good sensitivity.

Since DRESS is a life-threatening reaction, we should make every effort to identify the eliciting drug with available diagnostic tools.

Acknowledgments

This work was supported by grant FIS PI060441 (awarded to TB).

References

1. Shiohara T, Inaoka M, Kano Y. Drug-induced hypersensitivity syndrome (DIHS): a reaction induced by a complex interplay among herpesviruses and antiviral and antidrug immune responses. *Allergol Int.* 2006;55:1-8.
2. Fahim S, Jain V, Victor G, Pierscianowski T. Piperacillin-tazobactam-induced drug hypersensitivity syndrome. *Cutis.* 2006;77:353-7.
3. Cabañas R, Muñoz L, López-Serrano C, Contreras J, Padial A, Caballero T, Moreno-Ancillo A, Barranco P. Hypersensitivity to piperacillin. *Allergy.* 1998;53:819-20.
4. Akcam FZ, Aygun FO, Akkaya VB. DRESS like severe drug rash with eosinophilia, atypic lymphocytosis and fever secondary to ceftriaxone. *J Infect.* 2006;53:51-3.
5. Nyfeler B, Pichler WJ. The lymphocyte transformation test for the diagnosis of drug allergy: sensitivity and specificity. *Clin Exp Allergy* 1997;27:175-81.
6. Kano Y, Hirahara K, Mitsuyama Y, Takahashi R, Shiohara T. Utility of the lymphocyte transformation test in the diagnosis of drug sensitivity: dependence on its timing and the type of drug eruption. *Allergy.* 2007;62:1439-44.
7. Pichler WJ, Tilch J. The lymphocyte transformation test in the diagnosis of drug hypersensitivity. *Allergy.* 2004;59:809-20.
8. Shiohara T, Takahashi R, Kano Y. Drug-induced hypersensitivity syndrome and viral reactivation. In Pichler WJ (ed): *Drug Hypersensitivity*. Basel, Karger, 2007:251-66.

■ *Manuscript received November 2, 2009; accepted for publication January 11, 2010.*

■ Rosario Cabañas

Department of Allergology
Hospital Universitario La Paz
Paseo de la Castellana, 261
28046 Madrid, Spain
E-mail: charo.cabanass@gmail.com