

Nine Cases of Omeprazole Allergy: Cross-Reactivity Between Proton Pump Inhibitors

T Lobera, B Navarro, MD Del Pozo, I González, A Blasco, R Escudero, M Venturini, E Alarcón

Department of Allergy, Hospital San Pedro/San Millán, Logroño, Spain

■ Abstract

Although rare, anaphylactic reactions induced by proton pump inhibitors have been reported. The presence of cross-reactivity between different members of the group is not clear.

We studied 9 patients with adverse reactions to omeprazole. Clinical symptoms appeared immediately in 8 patients and after 4 hours in 1. Symptoms ranged from urticaria/angioedema in 7 cases to anaphylaxis in 2 cases. Skin prick tests and oral controlled challenge tests with omeprazole, lansoprazole, and pantoprazole were performed.

Skin prick or intradermal tests with omeprazole were positive in 8 patients. Four were also positive to pantoprazole. Prick tests with lansoprazole were always negative. Lansoprazole was administered to all 9 patients, with good tolerance in 8. Only 3 patients were challenged with pantoprazole and developed widespread urticaria.

We present 9 patients with immunoglobulin E-mediated allergy to omeprazole. In most of our cases, lansoprazole proved to be a good alternative treatment.

Key words: Proton pump inhibitors. Omeprazole. Lansoprazole. Drug allergy. Cross-reactivity.

■ Resumen

Aunque no son frecuentes, se han publicado varios casos de reacciones anafilácticas por inhibidores de la bomba de protones. La presencia de reactividad cruzada entre los componentes de este grupo de fármacos todavía no está aclarada.

Estudiamos 9 pacientes con reacción adversa después de la toma de omeprazol. La sintomatología clínica apareció de forma inmediata en 8 pacientes y después de 4 horas en 1. La sintomatología fue de urticaria / angioedema en 7 casos y de anafilaxia en 2 casos. Se realizan pruebas cutáneas y pruebas de exposición controlada con omeprazol, lansoprazol y pantoprazol.

Las pruebas cutáneas con omeprazol fueron positivas en 8 pacientes. En cuatro también se obtuvo resultado positivo con pantoprazol. En todos los casos las pruebas de punción con lansoprazol fueron negativas. Lansoprazol fue administrado a los 9 pacientes, con buena tolerancia en 8 casos. Solamente se realizó exposición a pantoprazol en 3 casos, desarrollándose en todos ellos un cuadro de urticaria generalizada.

Presentamos 9 pacientes con alergia IgE mediada frente a omeprazol. En la mayoría de ellos, lansoprazol ha resultado un tratamiento alternativo seguro.

Palabras clave: Inhibidores de la bomba de protones. Omeprazol. Lansoprazol. Alergia a medicamentos. Reactividad cruzada.

Introduction

Proton pump inhibitors (PPI), the most potent inhibitors of gastric acid secretion, have revolutionized the treatment of acid-related disorders, including gastroesophageal reflux disease,

peptic ulcer disease, and gastropathy induced by nonsteroidal anti-inflammatory drugs (NSAIDs). They are combined with antibiotics to eradicate *Helicobacter pylori*. Since the introduction of omeprazole, several other PPIs—lansoprazole, rabeprazole, pantoprazole, and esomeprazole—have been developed. They

are generally well tolerated, with minimal adverse effects, most of which are related to the drug's pharmacokinetic interaction profiles [1]. Although hypersensitivity reactions are rare, several anaphylactic reactions have been reported [2-10]. Some reports describe the presence of cross-reactivity between different members of the group, although no definite pattern has emerged [11-14]. We present 9 patients with omeprazole-induced anaphylactic reactions that were diagnosed by skin tests, oral challenge tests, or both. In order to offer a safe alternative, cross-reactivity studies with lansoprazole and pantoprazole were performed.

Case Description

Patients

Nine nonatopic women (no history of allergic reaction) aged 35-54 years (mean 42.5 years) were referred to our allergy department with adverse reaction to omeprazole. Clinical symptoms appeared immediately (less than 60 min) in 8 patients and after 4 hours in 1. Symptoms ranged from urticaria/angioedema in 7 cases to anaphylaxis in 2 cases. In 7 cases, the reaction also involved other drugs, which were studied and ruled out. Patient age and the characteristics of the reactions are shown in Table 1. The patients signed a written informed consent form before the skin tests and controlled challenge tests were performed.

Skin Tests

Skin prick tests with omeprazole (40 mg/mL), lansoprazole (15-mg tablet), and pantoprazole (20-mg tablet) were performed on the volar side of the forearm, according to published procedures [15]. Reactions were considered positive

Table 1. Characteristics of the Reactions

Patient Number	Age	Latency	Symptoms
1	50	45 min	Urticaria/angioedema
2	39	30 min	Urticaria/angioedema
3	39	60 min	Urticaria
4	54	4 h	Urticaria
5	35	45 min	Abdominal pain, sickness, Urticaria/angioedema
6	43	60 min	Urticaria/angioedema
7	36	30 min	Abdominal pain/Urticaria
8	48	30 min	Urticaria/angioedema
9	39	30 min	Abdominal pain/Urticaria

when a wheal greater than 3 mm in diameter was present 20 minutes later. An intradermal test with omeprazole (1 mg/mL) was performed if the skin prick test was negative. Readings were made 20 minutes after the injection. Results were considered positive when wheals greater than 5 mm were present. Histamine (at 10 mg/mL) was used as a positive control for the skin prick test. Normal saline was used as a negative control for skin prick and intradermal tests.

Ten individuals with no previous history of allergy to proton pump inhibitors and 10 patients with suspected adverse reactions to omeprazole and negative skin prick test results who proved to be tolerant to omeprazole.

Skin prick or intradermal tests with omeprazole were positive in 8 patients. Four were also positive to pantoprazole. Prick tests with lansoprazole were always negative. Skin prick tests and intradermal tests were negative in the controls. The results of the skin tests are summarized in Table 2.

Table 2. Results of the Allergy Study

Patient Number	Skin Tests			Controlled Challenge Tests		
	Omeprazole SPT/IDT	Lansoprazole SPT	Pantoprazole SPT	Omeprazole	Lansoprazole	Pantoprazole
1	Positive/NP	Negative	Positive	^a	Negative	NP
2	Negative/Positive	Negative	Positive	^a	Negative	Positive
3	Positive/NP	Negative	Negative	NP	Positive	NP
4	Negative/Negative	Negative	Negative	Positive	Negative	NP
5	Positive/NP	Negative	Positive	NP	Negative	NP
6	Positive/NP	Negative	Positive	NP	Negative	NP
7	Negative/Positive	Negative	Negative	NP	Negative	Positive
8	Positive/NP	Negative	Negative	NP	Negative	NP
9	Positive/NP	Negative	Negative	NP	Negative	Positive

Abbreviations: IDT, intradermal test; NP, not performed; SPT, skin prick test.

^a Patients 1 and 2 were exposed to the drug orally outside the context of a controlled challenge test and experienced an allergic reaction.

Controlled Oral Challenge Tests

Increasing doses of omeprazole (5, 10, and 20 mg), lansoprazole (3.25, 7.5, and 15 mg), or pantoprazole (5, 10, and 20 mg) were administered orally at 60-minute intervals until the therapeutic doses were reached or symptoms appeared.

Omeprazole was administered to the only patient with a negative skin test result. Four hours after ingestion of the final dose (cumulative 35 mg), the patient developed widespread urticaria and chest tightness, which resolved after treatment with methylprednisolone and dexchlorpheniramine. Two patients (1 and 2 in Table 2) with positive skin test results for omeprazole were exposed to the drug orally outside the context of a controlled challenge test and experienced an allergic reaction.

Lansoprazole was administered to all 9 patients until the therapeutic dose was reached. Eight showed good tolerance. Only 1 patient suffered widespread urticaria 1 hour after taking the final dose. She was a 39-year-old woman with dyspepsia and gastroesophageal reflux disease who experienced pruritus and generalized cutaneous eruption 60 minutes after ingestion of omeprazole and ketorolac. Skin tests were positive for omeprazole and negative for ketorolac, which was tolerated in a controlled challenge test. As ranitidine did not improve her digestive symptoms, a controlled challenge test with lansoprazole was carried out.

Only 3 patients were challenged with pantoprazole, and all of them developed pruritus and urticaria within less than 30 minutes after the second dose (cumulative 15 mg). This reaction resolved 60 minutes after treatment with methylprednisolone and dexchlorpheniramine. These 3 patients had tolerated lansoprazole. The results of the controlled challenge tests are shown in Table 2.

Discussion

We report 9 women diagnosed with allergy to omeprazole. The time course between the reaction and the ingestion of the drug, characteristics of the reaction, and skin test or challenge test results suggest an immunoglobulin E-mediated mechanism. There have been several reports of allergy to different PPIs [2-5,7-14,16-22]; however, to our knowledge, this is the largest published series.

Diagnosis of PPI allergy is not easy. On the one hand, many drugs are usually involved in the reaction, since PPI are frequently used in combination with antibiotics to eradicate *H pylori* or with NSAIDs for protection against gastric damage. On the other hand, these drugs are frequently used without medical prescription, and they are not recorded in the medical history. In our opinion, patients must always be asked whether they take PPI in order to avoid underdiagnosis and unplanned re-exposures.

The earliest reports base the diagnosis of PPI allergy on clinical data or challenge tests [2-4,8,11]. However, most authors [5,9,12,13,16] state that skin tests are useful diagnostic tools. In our series, 8 patients had positive skin test results for omeprazole and a challenge test was necessary to confirm the diagnosis in only 1 case. In this case, the reaction occurred

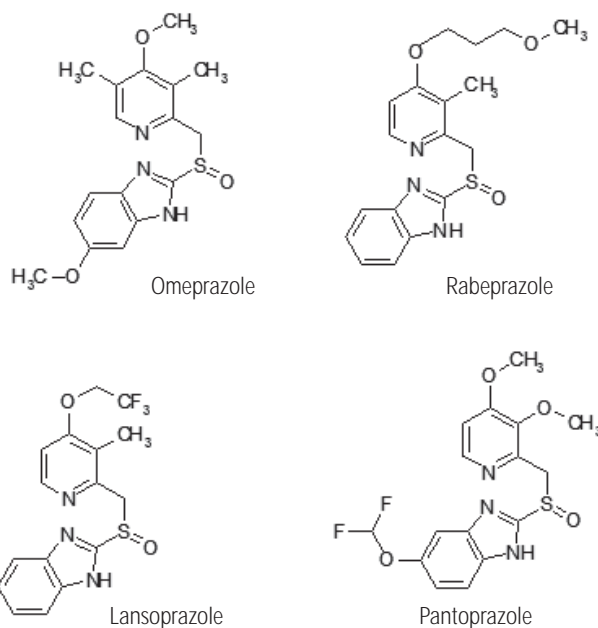


Figure. Chemical structure of proton pump inhibitors.

later than in the other 8, a circumstance that had been reported elsewhere involving pantoprazole with a negative skin prick test and a positive oral challenge result [17,18]. Our results show that skin tests have high sensitivity and specificity.

Skin prick tests with lansoprazole were negative in all the cases and tolerance was confirmed in 8 of them. Only 1 patient developed an allergic reaction to lansoprazole in a controlled challenge test. However, 3 of our patients had positive skin tests to pantoprazole and another 2 patients challenged with this drug developed allergic reactions. Therefore, in most of our cases, lansoprazole was a valid alternative PPI, whereas the results obtained with pantoprazole provide evidence of a high rate of cross-reactivity. Nevertheless, we believe that skin tests and controlled oral challenge tests with lansoprazole are mandatory before offering it as a safe therapeutic alternative. The flow cytometric basophil activation test is a new test [19] that could improve the final diagnosis.

Previous reports describe different patterns of cross-reactivity between PPIs after skin prick or oral challenge tests: between omeprazole and lansoprazole confirmed by skin tests [5] (only 1 case in our group); between omeprazole, lansoprazole, and pantoprazole confirmed by skin tests [12,20] (none in our series); and between omeprazole and pantoprazole [21-23] (4 in our patients). Other authors suggest cross-reactivity between lansoprazole and rabeprazole [13,14]. PPIs are modified benzimidazoles with a pyridine ring, differing in that substitutions are present on both rings (Figure). Thus, omeprazole and pantoprazole have, respectively, a methoxy and a difluoromethoxy chain in their benzimidazole ring, whereas lansoprazole and rabeprazole have no modifications in that ring, but their pyridine rings have, respectively, a trifluoroethoxy and methoxypropoxy chain. Therefore, in

agreement with Perez Pimiento et al [14], we think that these analogous chemical structures are responsible for the high rate of cross-reactivity observed between omeprazole and pantoprazole and give support to the results obtained with our patients.

We present 9 patients with IgE-mediated allergy to omeprazole. In most cases, lansoprazole proved to be a good alternative treatment. We would like to highlight the importance of skin tests as diagnostic tools in PPI allergy. Furthermore, we underline the importance of an allergologic study (including skin and controlled challenge tests) before offering lansoprazole as a safe alternative to patients.

References

- Esplugues JV, Marti-Cabrera M, Ponce J. Safety of proton pump inhibitors. *Med Clin (Barc)*. 2007;188(20):799.
- Haeney MR. Angio-edema and urticaria associated with omeprazole. *BMJ*. 1992;305 (6858):870.
- Bowlby HA, Dickens GR. Angioedema and urticaria associated with omeprazole confirmed by drug rechallenge. *Pharmacotherapy*. 1994;14(1):119-22.
- Ottervanger JP, Phaff RA, Vermeulen EG, Stricker BH. Anaphylaxis to omeprazole. *J Allergy Clin Immunol*. 1996;97(6):1413-4.
- Galindo PA, Borja J, Feo F, Gómez E, García R, Cabrera M, Martínez C. Anaphylaxis to omeprazole. *Ann Allergy Asthma Immunol*. 1999;82(1):52-4.
- Natsch S, Vinks MH, Voogt AK, Mees EB, Meyboom RH. Anaphylactic reactions to proton-pump inhibitors. *Ann Pharmacother*. 2000;34(4):474-6.
- Fardet L, Izzedine H, Ciroidi M, Tiev KP, Cabane J. Pantoprazole-induced recurrent anaphylactic shock. *Am J Gastroenterol*. 2002;97(6):1578-9.
- Muela Molinero A, Ballesteros del Río B, Nistal de Paz F, Fernández Pérez E. Immediate anaphylactic shock after the administration of intravenous omeprazol. *Rev Clin Esp*. 2003;203(4):216-7.
- Kollmeier AP, Eddleston J, Zuraw BL, Christiansen SC. Recurrent anaphylaxis linked to pantoprazole. *J Allergy Clin Immunol*. 2004;114(4):975-7.
- Kamann S, Bauer C, Fackler I, Przybilla B. Anaphylaxis caused by omeprazole. *Hautarzt*. 2006;57(11):1016-8, 1020.
- Ricciardi L, Fedele R, Mazzeo L, Saitta S, Mancuso V, Isola S. Adverse reactions to pantoprazole. *Scand J Gastroenterol*. 2003;38(7):800.
- Garmendia Zallo M, Sánchez Azkárata A, Kraemer Mbula R, Liarte Ruano I, Núñez Hernández A, Cid de Rivera C. ¿Existe reactividad cruzada entre inhibidores de la bomba de protones? *Allergol et Immunopathol*. 2004;32(2):92-5.
- Porcel S, Rodríguez A, Jiménez S, Alvarado M, Hernández J. Allergy to lansoprazole: study of cross-reactivity among proton-pump inhibitors. *Allergy*. 2005;60:1087-8.
- Pérez Pimiento AJ, Prieto Lastra L, Rodríguez Cabrerros MI, González Sánchez LA, Rodríguez Mosquera M, García Cubero A. Hypersensitivity to lansoprazole and rabeprazole with tolerance to other proton pump inhibitors. *J Allergy Clin Immunol*. 2006;117(3):707-8.
- Malling HJ. Allergen standardization and skin tests. *Methods of skin testing*. Position Paper. *Allergy*. 1993;48(Suppl 14):55-6.
- Demirkan K, Bozkurt B, Karakaya G, Kalyoncu AF. Anaphylactic reaction to drugs commonly used for gastrointestinal system diseases: 3 case reports and review of the literature. *J Investig Allergol Clin Immunol*. 2006;16(3):203-9.
- Kaatz M, Bauer A, Hipler C, Elsner P. Nonallergic anaphylaxis to pantoprazole. *Allergy*. 2002;57(2):184.
- Gratacós L, Soy D, Lluís M, López B, Nicolás JM, Codina C, Nogué S, Ribas J. Apparent anaphylaxis associated with pantoprazole. *Am J Health Syst Pharm*. 2005;62(13):1388-9.
- Gamboa PM, Sanz ML, Urrutia I, Jáuregui I, Antépara I, Diéguez I, De Weck AL. CD63 expression by flow cytometry in the in vitro diagnosis of allergy to omeprazole. *Allergy*. 2003;58(6):538-9.
- González P, Soriano V, López P, Niveiro E. Anaphylaxis to proton pump inhibitors. *Allergol et Immunopathol*. 2002;30(6):342-3.
- Confino-Cohen R, Goldberg A. Anaphylaxis to omeprazole: diagnosis and desensitization protocol. *Ann Allergy Asthma Immunol*. 2006;96(1):33-6.
- Reyes Balaguer J, Campos Andreu A, Hernández Fernández de Rojas D. Anaphylaxis to proton pump inhibitors. *Med Clin (Barc)*. 2007;128(20):799.
- Garrido S, Cumplido JA, Rábano A, Martínez D, Blanco C, Carrillo T. Allergy to proton pump inhibitors: diagnosis and assessment of cross-reactivity. *J Investig Allergol Clin Immunol*. 2008;18(2):140-1.

■ *Manuscript received June 6, 2008; accepted for publication October 2, 2008.*

■ **Dr. Teófilo I. Lobera**

C/ Gran Vía, 40 – 8º Dcha
26005 Logroño
Spain
E-mail: tlobera@riojasalud.es